



3rd INDERCOS

National Dermatology & Cosmetology Congress with International Participants

14-17 MARCH, 2018
HILTON ISTANBUL BOSPHORUS HOTEL
ISTANBUL, TURKEY



"Women in Dermatology"
Hands-on Aesthetics Dermatology Courses



Scientific Program
Lecture Summaries
Oral Presentations
Poster Presentations

www.indercos.org





3rd INDERCOS

National Dermatology & Cosmetology Congress with International Participants

14-17 MARCH, 2018
HILTON ISTANBUL BOSPHORUS HOTEL
ISTANBUL, TURKEY

CONTENTS

Invitation	4
Committees	5
Scientific Program	6 - 25
Lecture Summaries	27- 144
Oral Presentations	145 - 223
Poster Presentations	224 - 431
Authors Index for Abstracts	432 - 455

3rd INDERCOS

National Dermatology & Cosmetology Congress with International Participants

14-17 MARCH, 2018
HILTON ISTANBUL BOSPHORUS HOTEL
ISTANBUL, TURKEY



INVITATION

Dear colleagues,

It is a great pleasure to invite you to be with us in **Istanbul, Turkey** for **INDERCOS 2018**.

The main topics of the **3rd INDERCOS Congress** will be "Women in Dermato-Cosmetology" and "What's New in Female Dermatological Diseases?" Through plenaries and parallel workshop sessions, we aim to share insights and experiences and discuss how advances in dermatology and aesthetic dermatology management are affecting diagnosis and treatment in clinical practice. In order to success this, we have very distinctive international speakers with extensive experience and a range of expertise across dermatology and cosmetology. The great founder of the Republic of Turkey, Atatürk had said "Everything we see in the world is the creative work of women."

We hope you will be together with us in this fascinating, high quality scientifically educational congress and we look forward to your precious participation and feedback.

Prof. Ümit Türsen
Co-President

Prof. Serhat İnalöz
Co-President



3rd INDERCOS

National Dermatology & Cosmetology Congress with International Participants

14-17 MARCH, 2018
HILTON ISTANBUL BOSPHORUS HOTEL
ISTANBUL, TURKEY

COMMITTEES

ORGANISING COMMITTEE

İNALÖZ Serhat (TR)	<i>Co-President</i>
TÜRSEN Ümit (TR)	<i>Co-President</i>
LOTTI Torello (IT)	<i>Vice President</i>
SHAPIRO Jerry (USA)	<i>Vice President</i>
GÜVENÇ Ulaş (TR)	<i>Secretary General</i>
TÜRSEN Belma (TR)	<i>Secretary General</i>

SCIENTIFIC COMMITTEE

LOTTI Torello (IT)	<i>Chair</i>	LAEUCHLI Severin (CH)	<i>Member</i>
ATZORI Laura (IT)	<i>Member</i>	MARINKOVICH M.Peter (USA)	<i>Member</i>
BINIC Ivana (CS)	<i>Member</i>	NASHAN Dorothee (DE)	<i>Member</i>
BODAMYALI Pertevniyal (TRNC)	<i>Member</i>	NEDIC Zoran (CS)	<i>Member</i>
BURG Günter (CH)	<i>Member</i>	NIKOLIC Milos (CS)	<i>Member</i>
CLATICI Victor Gabriel (ROU)	<i>Member</i>	OZUNTURK Ercin (TR)	<i>Member</i>
FINLAY Andrew (ENG)	<i>Member</i>	PROHIC Asja (BA)	<i>Member</i>
FRANÇA Katlein (USA)	<i>Member</i>	SHAPIRO Jerry (USA)	<i>Member</i>
GOK Semih (TR)	<i>Member</i>	SOKOLOWSKA - WOJDYLO Malgorzata (POL)	<i>Member</i>
HANEKE Eckart (DE)	<i>Member</i>	SPIEWAK Radoslaw (POL)	<i>Member</i>
HENNIES Hans Christian (DE)	<i>Member</i>	SÜLEYMAN Eserdağ (TR)	<i>Member</i>
HOFMANN Maja (DE)	<i>Member</i>	THIO Hok Bing (NL)	<i>Member</i>
KATSAMBAS Andreas (GR)	<i>Member</i>	TRELLES Mario A. (ESP)	<i>Member</i>
KAYA Tamer Irfan (TR)	<i>Member</i>	WAUGH Micheal (ENG)	<i>Member</i>
KHACHEMOUNE Amor (USA)	<i>Member</i>	ZARGARI Omid(CA)	<i>Member</i>
KIRCIK Leon (DE)	<i>Member</i>	ZELENKOVA Hana (SK)	<i>Member</i>
KIRTSCBIG Gudula (DE)	<i>Member</i>	ZUBERBIER Torsten (DE)	<i>Member</i>

ORAL PRESENTATION AND POSTER REVIEW COMMITTEE


GUREL Mehmet Salih (TR)	<i>Chair</i>	SARIKAN Gaye (TR)	<i>Member</i>
AKDENİZ Necmettin (TR)	<i>Member</i>	TEKİN Burak (TR)	<i>Member</i>
BAHALI Anıl Gülsel (TR)	<i>Member</i>	TERZİ Erdinç (TR)	<i>Member</i>
GÜNDÜZ Özgür (TR)	<i>Member</i>	TOPKARCI Zeynep (TR)	<i>Member</i>
KOCATÜRK GÖNCÜ Emek (TR)	<i>Member</i>	UZUNÇAKMAK Tuğba Kevser (TR)	<i>Member</i>
MELİKOĞLU Mehmet (TR)	<i>Member</i>		

SOCIAL COMMITTEE

USTA GUNEY Ayşegül (TR)	<i>Chair</i>
APİ Hale (TR)	<i>Member</i>
OZKAN Koray (TR)	<i>Member</i>



Scientific Program





3rd INDERCOS

National Dermatology & Cosmetology Congress with International Participants

14-17 MARCH, 2018
HILTON ISTANBUL BOSPHORUS HOTEL
ISTANBUL, TURKEY

14 March 2018, Wednesday

Hall 1

08:30 - 09:00 Welcome Speeches *Serhat İnalöz, Ümit Türsen*

09:00 - 10:15 Women In Dermatology

Chairs: Mihael Skerlev, Süleyman Eserdağ

09:00 - 09:15 Women Working Community in Dermatology *Hilal Gökcalp*

09:15 - 09:30 Women in Dermatology: Challenges and Successes in Turkey *Hilal Gökcalp*

09:30 - 09:45 What the Dermatovenereologist Should Do to Prevent the STIs in Women *Mihael Skerlev*

09:45 - 10:00 Genital Aesthetics and Sexology *Süleyman Eserdağ*

10:00 - 10:15 Discussion

10:15 - 11:00 Coffee Break

11:00 - 12:30 Vasculitis

Chairs: Hok Bing Thio, Mehmet Melikoğlu

11:00 - 11:15 Acraly Distributed Dermatoses: Vascular Dermatoses (Purpura and Vasculitis) *Ralfi Singer*

11:15 - 11:30 Unclassified Vasculitis *Hok Bing Thio*

11:30 - 11:45 Behçet's Disease in Pregnancy *Mehmet Melikoğlu*

11:45 - 12:00 Connective Tissue Diseases and Pregnancy *Tuğba Kevser Uzunçakmak*

12:00 - 12:30 Discussion

12:30 - 14:00 Lunch

14:00 - 15:30 Cutaneous Allergy-1

Chairs: Torsten Zuberbier, Milos Nikolic

14:00 - 14:15 Urticaria And Pregnancy *Emek Kocatürk Göncü*

14:15 - 14:30 The Use Of Biologicals in Cutaneous Allergies - Present and Future *Torsten Zuberbier*

14:30 - 14:45 Chronic Urticaria As a Systemic Disease *Torsten Zuberbier*

14:45 - 15:00 Dermatologic Emergency: TEN *Milos Nikolic*

15:00 - 15:30 Discussion

15:30 - 16:00 Coffee Break

3rd INDERCOS

National Dermatology & Cosmetology Congress with International Participants

14-17 MARCH, 2018
HILTON ISTANBUL BOSPHORUS HOTEL
ISTANBUL, TURKEY



14 March 2018, Wednesday

Hall 1

16:00 - 17:00 Cutaneous Allergy-2 (Fast Track)

Chairs: Ayşın Köktürk, Radoslaw Spiewak

16:00 - 16:10	Dietetic Interventions in Allergic Contact Dermatitis	Radoslaw Spiewak
16:10 - 16:20	Cutaneous Manifestations of Drug Allergy and Hypersensitivity	Radoslaw Spiewak
16:20 - 16:30	Contact Allergy To Cosmetics	Radoslaw Spiewak
16:30 - 16:40	Atopic Dermatitis: Current Treatment Guidelines	Małgorzata Sokołowska-Wojdyło
16:40 - 16:50	Textiles and Clothing in Dermatology	Rafet Koca
16:50 - 17:00	Discussion	

17:00 - 18:15 Pigmentary Disorders

Chairs: Emel Fetil, Maja Hofmann

17:00 - 17:15	New Approach of Laser Treatments	Ömür Tekeli
17:15 - 17:30	Treatment of Facial Redness: What's New?	Maja Hofmann
17:30 - 17:45	Resistant Tattoo: What Can We Do?	Deniz Duman
17:45 - 18:00	Importance of Melasma Treatment	Emel Fetil
18:00 - 18:15	Discussion	



3rd INDERCOS

National Dermatology & Cosmetology Congress with International Participants

14-17 MARCH, 2018
HILTON ISTANBUL BOSPHORUS HOTEL
ISTANBUL, TURKEY

14 March 2018, Wednesday

Hall 2

09:00 - 10:15 Animal-Related Skin Diseases

Chairs: İdil Ünal, Sedat Akdeniz

09:00 - 09:15	Cats and Dogs Related Skin Diseases and Dermatology	<i>İdil Ünal</i>
09:15 - 09:30	Cattle-Related Skin Diseases	<i>Ahmet Metin</i>
09:30 - 09:45	Sea Animals and Dermatology	<i>Ragıp Ertaş</i>
09:45 - 10:00	Insect-Related Skin Diseases	<i>Sedat Akdeniz</i>
10:00 - 10:15	Discussion	

10:15 - 11:00 Coffee Break

11:00 - 12:30 Nail Diseases

Chairs: Pelin Koçyiğit, Eckart Haneke

11:00 - 11:15	Onychoscopy	<i>Mustafa Turhan Şahin</i>
11:15 - 11:30	Erythronychia (Red Lunula)	<i>Mustafa Turhan Şahin</i>
11:30 - 11:45	Important Malignant and New Nail Tumors	<i>Eckart Haneke</i>
11:45 - 12:00	Anatomy of The Nail Unit and The Nail Biopsy	<i>Eckart Haneke</i>
12:00 - 12:15	Matricectomy Indications in Dermatology	<i>Pelin Koçyiğit</i>
12:15 - 12:30	Discussion	

12:30 - 14:00 Lunch

14:00 - 15:30 Treatments in Dermatology 1

Chairs: Emel Bülbül Başkan, Omid Zargari

14:00 - 14:20	Biologics or Biosimilars: What is the Difference?	<i>Emel Bülbül Başkan</i>
14:20 - 14:40	Treatment of Parasitic Skin Diseases	<i>Omid Zargari</i>
14:40 - 15:00	Intermittant or Pulse Treatments in Dermatology	<i>Betül Şerefican</i>
15:00 - 15:20	Scleromyxoedema and Scleredema Treatments	<i>Laura Atzori</i>
15:20 - 15:30	Discussion	

15:30 - 16:00 Coffee Break

3rd INDERCOS

National Dermatology & Cosmetology Congress with International Participants

14-17 MARCH, 2018
HILTON ISTANBUL BOSPHORUS HOTEL
ISTANBUL, TURKEY



14 March 2018, Wednesday

Hall 2

16:00 - 17:00 Treatments in Dermatology-2 (Fast Track)

Chairs: Leon Kircik, Kemal Özyurt

16:00 - 16:10	Hyaluronidases and Dermatology	Ali Şahan
16:10 - 16:20	Insulin Resistance in Dermatology	Kemal Özyurt
16:20 - 16:30	Sinecatechines in Dermatology	Emin Özlü
16:30 - 16:40	Apremilast: Review in Dermatology	Leon Kircik
16:40 - 16:50	Topical Treatments for Skin Cancers	Nagihan Sahillioğlu
16:50 - 17:00	Tartışma	

17:00 - 18:30 Anti-Aging Treatments-1

Chairs: Gaye Sarıkan, Filiz Kuşak

17:00 - 17:15	Types Of Botulinum Toxin: Which One is The Best?	Filiz Kuşak
17:15 - 17:30	Anti-Aging Diet in Dermatology	Sadiye Kuş
17:30 - 17:45	Aging Determination Tests	Öykü Maraşoğlu Çelen
17:45 - 18:00	Andropause, Somatopause, Hormonal Regulation Of Aging and Anti-Aging Hormone Replacement	Berna Aksoy
18:00 - 18:15	Menopause and Dermatology	Gaye Sarıkan
18:15 - 18:30	Medical and Cosmetic Treatment of Hair Loss in Women	Ekrem Civaş



3rd INDERCOS

National Dermatology & Cosmetology Congress with International Participants

14-17 MARCH, 2018
HILTON ISTANBUL BOSPHORUS HOTEL
ISTANBUL, TURKEY

15 March 2018, Thursday

Hall 1

08:00 - 09:00 Oral Presentation-1

Chairs: Mehmet Salih Gürel, Necmettin Akdeniz

- | | | |
|---------------|---|---------------------|
| 08:00 - 08:05 | OP-01 Betatrophin and Irisin Levels in Patients with Psoriasis | Bengisu Ozarslan |
| 08:05 - 08:10 | OP-02 Herpes Zoster in Healthy Children: A Total Of 38 Cases | Hamza Aktaş |
| 08:10 - 08:15 | OP-03 Facial Melanoses in Indian Population | Meghna Sharma |
| 08:15 - 08:20 | OP-04 Investigation of Some miRNA Expression Levels Associated With Melanogenesis in Vitiligo Patients | Gurbet Doğru |
| 08:20 - 08:25 | OP-05 Radiotherapy of Malign Melanoma: A Single Institution Experience From Northeast | Mustafa Kandaz |
| 08:25 - 08:30 | OP-06 The Microvascular Changes in Psoriatic Patients with Nail Disease; A Link Between a Gray Scale and Nail Vessel Resistive Index Findings by Ultrasound and Nailfold Videocapillaroscopy Findings | Rabia Oztas Kara |
| 08:30 - 08:35 | OP-07 Comparative Study of Treatment of Recalcitrant Warts With Ablative CO2 Laser and QS-Nd-YAG Laser | Eman Moustafa Sanad |
| 08:35 - 08:40 | OP-08 Intravaginal Cog Thread Applications | Ozgur Leylek |
| 08:40 - 08:45 | OP-09 Study of The Cutaneous Expression of Thymic Stromal Lymphopoietin (TSLP) in a Sample of Vitiligo Patients: A Case-Control Study | Maha Fathy Elmasry |
| 08:45 - 08:50 | OP-10 HLA Type Determination in Patients Diagnosed With Mycosis Fungoides and Sezary Syndrome | Muazzez Çiğdem Oba |
| 08:50 - 08:55 | OP-11 Beauty Treatments - The Two Sides of a Coin | Neena Khanna |
| 08:55 - 09:00 | OP-12 A Rare Case of Facial Hypertrichosis in Females; Segmental Odontomaxillary Dysplasia | Salih Levent Cinar |

09:00 - 09:30 "Rational Use of Medicines

Gülden Ersöz

Evidence-Based Antibiotic Uses in Dermatology"

09:30 - 10:30 News from Dermatology-1

Chairs: Hans Christian Hennies, Nazan Emiroğlu

- | | | |
|---------------|---|------------------------|
| 09:30 - 09:45 | Micro-RNAs in Dermatology | Özgür Timurkaynak |
| 09:45 - 10:00 | HHV-6, 7 and 8 in Dermatology | Nazan Emiroğlu |
| 10:00 - 10:15 | The Application of CRISPR-Cas 9 and Genome Editing in Investigative Dermatology | Hans Christian Hennies |
| 10:15 - 10:30 | Nanoscience in Dermatology | Hans Christian Hennies |

3rd INDERCOS

National Dermatology & Cosmetology Congress with International Participants

14-17 MARCH, 2018
HILTON ISTANBUL BOSPHORUS HOTEL
ISTANBUL, TURKEY



15 March 2018, Thursday

Hall 1

10:30 - 11:15 Coffee Break

11:15 - 12:30 Skin Neoplasms

Chairs: Małgorzata Sokołowska-Wojdyło, Thomas Ruzicka

11:15 - 11:30	Primary Cutaneous Lymphomas: Diagnosis and Treatment	Małgorzata Sokołowska-Wojdyło
11:30 - 11:45	Use of Complementary and Alternative Medicine in Melanoma Patients	Aslı Aksu Çerman
11:45 - 12:00	Therapeutic Strategies For Actinic Keratoses-An Update	Aslı Aksu Çerman
12:00 - 12:20	BCC: Clinical Spectrum and New Developments in Diagnosis and Treatment	Thomas Ruzicka
12:20 - 12:30	Discussion	

12:30 - 14:00 Lunch

13:00 - 14:00 **SATELLITE SYMPOSIUM**
Silhouette Soft and Ellanse Filler Combination
Speaker: Şerafettin Saraçoğlu

mezo klinik

14:00 - 15:30 General Dermatology

Chairs: Ayşe Serap Karadağ, Andrew Finlay

14:00 - 14:15	Misnomers in Dermatology: An Update	Işın Sinem Bağcı
14:15 - 14:30	Phenomenon in Dermatology: An Update	Gamze Erfan
14:30 - 14:45	Pseudo-Conditions in Dermatology	Ezgi Özkur
14:45 - 15:00	Inverse-Conditions in Dermatology	Ayşe Serap Karadağ
15:00 - 15:15	Every Dermatology Consultation: Think Adherence	Andrew Finlay
15:15 - 15:30	Skin Tests in Dermatology	Ragıp Ertaş

15:30 - 16:00 Coffee Break



3rd INDERCOS

National Dermatology & Cosmetology Congress with International Participants

14-17 MARCH, 2018
HILTON ISTANBUL BOSPHORUS HOTEL
ISTANBUL, TURKEY

15 March 2018, Thursday

Hall 1

16:00 - 17:00 Aesthetic Dermatology-1

Chairs: Eckart Haneke, Hüray Hügöl

16:00 - 16:15	How Can We Obtain Venus Lips	Hüray Hügöl
16:15 - 16:30	Periorbital Fillers	Hüray Hügöl
16:30 - 16:45	Diagnosis and Management of Filler Adverse Effects: An Algorithm	Eckart Haneke
16:45 - 17:00	Carboxytherapy Uses in Dermatology	Hana Zelenkova

17:00 - 18:10 Hair Diseases (Fast Track)

Chairs: Jerry Shapiro, Esra Kural

17:00 - 17:10	Hair Loss in Women	Jerry Shapiro
17:10 - 17:20	Cicatricial Alopecia	Jerry Shapiro
17:20 - 17:30	Frontal Fibrosing Alopecia	Jerry Shapiro
17:30 - 17:40	Alopecia Areata	Jerry Shapiro
17:40 - 17:50	Hair Cosmetics, Hair in Forensic Medicine	Esra Kural
17:50 - 18:00	New Trichoscopic Observations in Female Hair Loss	Esra Kural
18:00 - 18:10	Hair Growth Assessment Techniques	Esra Kural

3rd INDERCOS

National Dermatology & Cosmetology Congress with International Participants

14-17 MARCH, 2018
HILTON ISTANBUL BOSPHORUS HOTEL
ISTANBUL, TURKEY



15 March 2018, Thursday

Hall 2

09:00 - 10:30 Lasers in Dermatology -1 & 2 (Fast Track)

Chairs: Mario Trelles, Meltem Önder

09:00 - 09:10	Neodymium-Doped Yttrium Aluminum Garnet (Nd:YAG) Laser For Vascular Lesions	<i>Zehra Aşiran Serdar</i>
09:10 - 09:20	Lasers for Hair Removal	<i>Victor Gabriel Clatici</i>
09:20 - 09:30	KTP Lasers in Dermatology	<i>Maja Hofmann</i>
09:30 - 09:40	Carbondioxide (10600 nm) and Er_glass (1540 nm) Combination Laser Use in Dermatology	<i>Ahu Birol</i>
09:40 - 09:50	Laser For Onychomycosis	<i>Meltem Önder</i>
09:50 - 10:00	Laser For HPV	<i>Eda Tiftikçi</i>
10:00 - 10:10	Vaginal Rejuvenation With CO2 Laser	<i>Mario Trelles</i>
10:10 - 10:20	Non-Thermal Laser Skin Rejuvenation of Dark Skin During The Summer	<i>Mario Trelles</i>
10:20 - 10:30	Discussion	

10:30 - 11:15 Coffee Break

11:15 - 12:15 Psoriasis

Chairs: Omid Zargari, Erkan Alpsoy

11:15 - 11:30	Psoriasis Treatment in Children and Pregnancy	<i>Erkan Alpsoy</i>
11:30 - 11:45	Some Practical Points in Managing Psoriatic Patients	<i>Omid Zargari</i>
11:45 - 12:00	Rotational Systemic Therapies in Dermatology	<i>Sibel Alper</i>
12:00 - 12:15	Discussion	

12:15 - 14:00 Lunch



3rd INDERCOS

National Dermatology & Cosmetology Congress with International Participants

14-17 MARCH, 2018
HILTON ISTANBUL BOSPHORUS HOTEL
ISTANBUL, TURKEY

15 March 2018, Thursday

Hall 2

14:00 - 15:30 Dermatological Diagnosis

Chairs: Amor Khachemoun, Kenan Aydoğan

14:00 - 14:15	Acetic Acid and Potassium Hydroxide Uses in Dermatology	Ercan Arca
14:15 - 14:30	Evaluation of Direct Immunofluorescence Assay and Cytological Examination in Dermatology	Murat Durdu
14:30 - 14:45	Stains for Dermatological Diagnosis (PAS, Methenamine Silver etc..)	Murat Durdu
14:45 - 15:00	Wood Lambs and Dermatology	Kenan Aydoğan
15:00 - 15:15	Epiphenomenon and Oxymoron Conditions in Dermatopathology	Amor Khachemoun
15:15 - 15:30	Mohs Surgery: Whats New?	Amor Khachemoun

15:30 - 16:00 Coffee Break

16:00 - 17:00 Sebaceous Gland Diseases

Chairs: Victor Gabriel Clatici, Andreas Katsambas

16:00 - 16:15	Rosacea and Systemic Diseases	Victor Gabriel Clatici
16:15 - 16:30	Acne and Metabolic Syndrome	Victor Gabriel Clatici
16:30 - 16:45	Therapeutic Approaches To Reducing Atrophic Acne Scarring	Andreas Katsambas
16:45 - 17:00	Difficult and Rare Forms of Acne	Andreas Katsambas

17:00 - 17:40 News from Dermatology-2 (Fast Track)

Chairs: M. Peter Marinkovich, Oktay Taşkapan

17:00 - 17:10	Toll-Like Receptors and Antimicrobial Peptides in Dermatology	Özgür Gündüz
17:10 - 17:20	Patch and Prick Tests: What's New?	Oktay Taşkapan
17:20 - 17:30	Gene Treatments in Dermatology	M.Peter Marinkovich
17:30 - 17:40	Alopecia Areata, Eczema and Vitiligo: News	M.Peter Marinkovich

17:40 - 18:25 Art and Dermatology (Fast Track)

Chairs: Yeşim Kaymak, Emel Erdal

17:40 - 17:50	Cinema And Dermatology	Yeşim Kaymak
17:50 - 18:00	Novel (Art) and Dermatology	Emel Erdal
18:00 - 18:15	Music and Health	Özalp Ekinci
18:15 - 18:25	The Golden Ratio of Beauty	Alev Bobuş

3rd INDERCOS

National Dermatology & Cosmetology Congress with International Participants

14-17 MARCH, 2018
HILTON ISTANBUL BOSPHORUS HOTEL
ISTANBUL, TURKEY



16 March 2018, Friday

Hall 1

08:00 - 09:00 Oral Presentation-2

Chairs: Özgür Gündüz, Deniz Demirseren

08:00 - 08:05	OP-13 Association Between Serum Adropin and Ischaemia - Modified Albumin Levels and Psoriasis Vulgaris	<i>Suzan Demir Pektas</i>
08:05 - 08:10	OP-14 Examination of Clinical and Demographic Characteristics of 14 Cases With Frontal Fibrosing Alopecia	<i>Fadime Kılınç</i>
08:10 - 08:15	OP-15 Geriatric Dermatoses in Women Presenting to a Dermatology Outpatient Clinic	<i>Ragıp Ertaş</i>
08:15 - 08:20	OP-16 Using of a Pulsed Dye Laser for Therapy of Chronic Dermatoses. Some Clinical Cases	<i>Alena Soha</i>
08:20 - 08:25	OP-17 The Relationship Between the Severity of Psoriasis, Body Mass Index and Waist Circumference	<i>Nermin Karaosmanoğlu</i>
08:25 - 08:30	OP-18 Arsenicosis in Bangladesh: Dermatological Manifestations and Management	<i>Mohammad Abdul Hye</i>
08:30 - 08:35	OP-19 Liposome Incorporated Clove Oil in the Treatment of Idiopathic Palmar Hyperhidrosis: Single Blinded Placebo Controlled Study	<i>Ibrahim Mohammed Abdel Kareem</i>
08:35 - 08:40	OP-20 Role of Radiotherapy in Palliative Outcome and Local Control of Non-Aids Associated Kaposi's Sarcoma	<i>Elif Emine Ozkan</i>
08:40 - 08:45	OP-21 Serum and Skin Levels of Adiponectin, Cartonectin (CTRP-3) and Osteopontin in Psoriasis Vulgaris and Effect of Treatment with Methotrexate	<i>Emine Böyük</i>
08:45 - 08:50	OP-22 Evaluation of Estrogen and Androgen Receptor Expression, Clinical Severity and Autoimmune Association in Lichen Sclerosus	<i>Fatma Uzun</i>
08:50 - 08:55	OP-23 The State of Occupational Dermatoses in Turkey	<i>Mehmet Melikoğlu</i>
08:55 - 09:00	OP-24 Topical polyphenol treatment of sacrococcygeal pilonidal sinus disease: Use of Ultrasonography to evaluate response to treatment - Clinical case series study	<i>Hasan Mete Aksoy</i>



3rd INDERCOS

National Dermatology & Cosmetology Congress with International Participants

14-17 MARCH, 2018
HILTON ISTANBUL BOSPHORUS HOTEL
ISTANBUL, TURKEY

16 March 2018, Friday

Hall 1

09:00 - 10:15 Pregnancy and Dermatology

Chairs: *Gudula Kirtschig, Levent Çınar*

09:00 - 09:15	Pregnancy Related Pruritus	<i>Salih Levent Çınar</i>
09:15 - 09:30	Pregnancy Related Pigmentations	<i>Salih Levent Çınar</i>
09:30 - 09:45	Pregnancy and Skin Tumours	<i>Salih Levent Çınar</i>
09:45 - 10:00	Distinct Diseases in Pregnancy	<i>Gudula Kirtschig</i>
10:00 - 10:15	The Safest Systemic and Topical Dermatological Treatments in Pregnancy	<i>Gudula Kirtschig</i>

10:15 - 11:00 Coffee Break

11:15 - 12:30 Oro-Genital Skin Diseases

Chairs: *Michael Waugh, Soner Uzun*

11:15 - 11:30	Treatment Guidelines of HPV Infections	<i>Michael Waugh</i>
11:30 - 11:45	Female-Prone Sexual Transmitted Skin Diseases	<i>Michael Waugh</i>
11:45 - 12:00	Pregnancy and STD Treatments	<i>Michael Waugh</i>
12:00 - 12:15	HPV Related Oral Diseases	<i>Soner Uzun</i>
12:15 - 12:30	Lichen Sclerosus et Atrophicus in Children	<i>Zeynep Topkarcı</i>

12:30 - 14:00 Lunch

13:00 - 14:00 Social Program : "Power of Women "

Beral Fişekçi

14:00 - 15:30 Differential Diagnosis (Fast Track)

Chairs: *Günter Burg, Aslı Erdemir*

14:00 - 14:10	Dermatoglyphics in Dermatology	<i>Pırl Etikan</i>
14:10 - 14:20	Sporotrichoid Pattern Skin Disease	<i>Ayşe Şermin Filiz</i>
14:20 - 14:30	Skin Diseases Affecting Cleavage Lines	<i>Sümeyre Seda Ertekin</i>
14:30 - 14:45	What Your Hands Show: Hand Signs as Hints to Diagnosis	<i>Günter Burg</i>
14:45 - 14:55	Differential Diagnosis of Annular Lesions	<i>Tuba Falay</i>
14:55 - 15:05	Phagedenic Ulcers Of Skin in Differential Diagnosis	<i>Esra Koku Aksu</i>
15:05 - 15:15	Chancriform Ulcers in Dermatology	<i>Aslı Erdemir</i>
15:15 - 15:30	Discussion	

3rd INDERCOS

National Dermatology & Cosmetology Congress with International Participants

14-17 MARCH, 2018
HILTON ISTANBUL BOSPHORUS HOTEL
ISTANBUL, TURKEY



16 March 2018, Friday

Hall 1

15:30 - 16:00 Coffee Break

16:00 - 17:30 News from Dermatology-3

Chairs: Asja Prohic, Günter Burg

16:00 - 16:15	Tinea Incognito: What's New?	<i>Asja Prohic</i>
16:15 - 16:30	Chronic Paronychia: What's New?	<i>Burhan Engin</i>
16:30 - 16:45	How, Where and When to Make a Biopsy?	<i>Günter Burg</i>
16:45 - 17:00	Cosmetic and Academic Dermatology: Two Sides of One Coin	<i>Günter Burg</i>
17:00 - 17:15	MacGyver in Dermatology	<i>Tuğrul Dereli</i>
17:15 - 17:30	Discussion	

17:30 - 18:30 Aesthetic Dermatology-2

Chairs: Ivana Binic, Belma Türsen

17:30 - 17:45	Sensitive Skin Syndrome	<i>Ivana Binic</i>
17:45 - 18:00	Percutaneous Collagen Induction Therapy in Aesthetic Dermatology	<i>Ivana Binic</i>
18:00 - 18:15	Water and Dermatology	<i>Belma Türsen</i>
18:15 - 18:30	Discussion	



3rd Indercos

National Dermatology & Cosmetology Congress with International Participants

14-17 MARCH, 2018
HILTON ISTANBUL BOSPHORUS HOTEL
ISTANBUL, TURKEY

16 March 2018, Friday

Hall 2

08:00 - 09:00 Oral Presentation-3

Chairs: Mehmet Melikoğlu, Zeynep Topkarcı

08:00 - 08:05	OP-25 Neurosyphilis in the Differential Diagnosis of Neuropsychiatric Disorders	Betül Şerefican
08:05 - 08:10	OP-26 Ocular Behçet's Disease - Two Treatment Methods for Two Severe Cases	Özgür Gündüz
08:10 - 08:15	OP-27 Cutaneous and Subcutaneous 18F-FDG PET/CT Findings in 195 Sarcoidosis Patients	Effrosyni D Manali
08:15 - 08:20	OP-28 A Nucleoside Reverse Transcriptase Inhibitor - Induced Dystrophic Anagen Alopecia	Betül Tas
08:20 - 08:25	OP-29 Hairy Throat: A Case Report	Meghna Sharma
08:25 - 08:30	OP-30 Skin Manifestations in Common Rheumatologic Diseases in Pediatric Population	Ilkin Zindancı
08:30 - 08:35	OP-31 Effects of Omalizumab on the Hematological and Inflammatory Parameters in Patients with Chronic Spontaneous Urticaria	Nihan Yüksel Çanakçı
08:35 - 08:40	OP-32 Comparison of Topical 3% Diclofenac Gel and 5% Imiquimod Cream in the Treatment of Actinic Keratosis: Clinical and Histopathological Study	Fatma Tunçez Akyürek
08:40 - 08:45	OP-33 Clinical and Demographical Characteristics and Treatment Outcomes of Digital Myxoid Pseudocysts	Güldehan Atış
08:45 - 08:50	OP-34 Is There a Relationship Between Hair Loss and Cephalalgia?	Serkan Demirkan
08:50 - 08:55	OP-35 High Frequency of Irritable Bowel Syndrome in Patients With Atopic Dermatitis	Mehmet Unal
08:55 - 09:00	OP-36 A Rare Pemphigus Variant: Pemphigus Herpetiformis	Handan Bilen

09:00 - 10:15 Treatments in Dermatology-3

Chairs: Mustafa Tunca, Hok Bing Thio

09:00 - 09:15	Intralesional Treatments in Dermatology	Mustafa Tunca
09:15 - 09:30	Evidence-Based Therapy For Cutaneous Sarcoidosis	Hok Bing Thio
09:30 - 09:45	Epidermolysis Bullosa: Evidence-Based Approach	M. Peter Marinkovich
09:45 - 10:00	Trichloroacetic Acid, Phenol and Sodium Hydroxide Uses in Dermatology	Fatma Pelin Cengiz
10:00 - 10:15	Discussion	

3rd INDERCOS

National Dermatology & Cosmetology Congress with International Participants

14-17 MARCH, 2018
HILTON ISTANBUL BOSPHORUS HOTEL
ISTANBUL, TURKEY



16 March 2018, Friday

Hall 2

10:15 - 11:00 Coffee Break

11:15 - 12:30 Treatments in Dermatology-4

Chairs: Serap Öztürkcan, Zoran Nedic

11:15 - 11:30	Bioengineering of Human Skin Substitutes	Maja Hofmann
11:30 - 11:45	Ifn Treatment: Does It Work in Dermatology	Maja Hofmann
11:45 - 12:00	Topical Calcineurin Inhibitors	Serap Öztürkcan
12:00 - 12:15	Topical Imiquimod	Zoran Nedic
12:15 - 12:30	Vitamin D and Dermatology	Habibullah Aktaş

12:30 - 14:00 Lunch

14:00 - 15:00 Psychodermatology

Chairs: Nilgün Solak, İlknur Altunay Kıvanç

14:00 - 14:15	Placebo and Nocebo Therapy in Dermatology	İlknur Altunay Kıvanç
14:15 - 14:30	Omalizumab Treatment in Chronic Spontaneous Urticaria	Andrew Finlay
14:30 - 14:45	Trichotillomania: New Treatment Approaches	Pelin Üstüner
14:45 - 15:00	Discussion	

15:00 - 16:00 Home-Based Treatments

Chairs: Banu Ertekin Taşkın, Pertevniyal Bodamyalı

15:00 - 15:15	Home Ultraviolet Light Therapies	Banu Ertekin Taşkın
15:15 - 15:30	Home Laser Therapies	Banu Ertekin Taşkın
15:30 - 15:45	Home Chemical Peelings	Pertevniyal Bodamyalı
15:45 - 16:00	Discussion	

16:00 - 16:30 Coffee Break



3rd INDERCOS

National Dermatology & Cosmetology Congress with International Participants

14-17 MARCH, 2018
HILTON ISTANBUL BOSPHORUS HOTEL
ISTANBUL, TURKEY

16 March 2018, Friday

Hall 2

16:30 - 17:30 Treatments in Dermatology-5 (Fast Track)

Chairs: Rafet Koca, Mehmet Melikoğlu

16:30 - 16:45	The Importance of Ornithine Decarboxylase in Dermatology	<i>Hilal Kaya Erdoğan</i>
16:45 - 17:00	Depot-Penicillin in Dermatology	<i>Pınar İncel</i>
17:00 - 17:15	Potassium Iodide Uses in Dermatology	<i>Şule Güngör</i>
17:15 - 17:30	The Role Of Capsaicin in Dermatology	<i>Şule Güngör</i>

17:30 - 18:30 Treatments in Dermatology-6 (Fast Track)

Chairs: Amor Khachemoune, Hilal Kaya Erdoğan

17:30 - 17:45	Photodynamic Therapy in Dermatology	<i>Amor Khachemoune</i>
17:45 - 18:00	Local Hyperthermia in Dermatology	<i>Gamze Erfan</i>
18:00 - 18:15	Mould Infections in Dermatology	<i>Asja Prohic</i>
18:15 - 18:30	Dermatology and PABA	<i>Müge Göre Karaali</i>

3rd INDERCOS

National Dermatology & Cosmetology Congress with International Participants

14-17 MARCH, 2018
HILTON ISTANBUL BOSPHORUS HOTEL
ISTANBUL, TURKEY



17 March 2018, Saturday

Hall 1

08:00 - 09:00 Oral Presentation-4

Chairs: Kemal Özyurt, Ragıp Ertaş

08:00 - 08:05	OP-37 Evaluation of The Relationship Between Severity of Disease in Acne Vulgaris and Dietary Factors with Body Mass Index	Ömer Kutlu
08:05 - 08:10	OP-38 Intralesional Vitamin D3 Injection in the Treatment of Common Warts: Single - Blinded Placebo - Controlled study	Ibrahim Mohammed Abdel Kareem
08:10 - 08:15	OP-39 Evaluation of Serum Netrin - 1 and Ischaemia - Modified Albumin Levels in Psoriasis Patients	Suzan Demir Pektaş
08:15 - 08:20	OP-40 Effects of Isotretinoin on the Hair Cycle	Zeynep Gizem Kaya Islamoğlu
08:20 - 08:25	OP-41 Evaluation of the Skin Prick Test and Serum Total IgE Results in Chronic Spontaneous Urticaria and Atopic Dermatitis	Işıl Bulur
08:25 - 08:30	OP-42 Epstein-Barr Virus Infection and Bacterial Infection with Urticarian Vasculitis Shows Same Cutaneous Clinical Manifestations in two Different Children Patients	Mehmet Melikoğlu
08:30 - 08:35	OP-43 Could Low Iron and Vitamin Levels be a Cause of Failure in Melasma Treatment	Mehmet Melikoğlu
08:35 - 08:40	OP-44 The Clinical Study of the Relation Between Chronic Idiopathic Urticaria (CIU) and Hp Infection	Marwa Mohamed
08:40 - 08:45	OP-45 Immune Therapy of Warts	Eman Moustafa Sanad
08:45 - 08:50	OP-46 Chronic Systemic Diseases and Rosacea: Results of a Case - Control Study at King Fahd Hospital of the University in Alkhobar, Saudi Arabia	Nora Alomair
08:50 - 08:55	OP-47 An Epidemiological and Clinical Analysis of Cutaneous Adverse Drug Reactions Seen in a Tertiary Care Outpatients Clinic in Cairo, Egypt	Maha Fathy Elmasry
08:55 - 09:00	OP-48 Erythema Ab Igne With Atypical Location	Ibrahim Halil Yavuz



3rd INDERCOS

National Dermatology & Cosmetology Congress with International Participants

14-17 MARCH, 2018
HILTON ISTANBUL BOSPHORUS HOTEL
ISTANBUL, TURKEY

17 March 2018, Saturday

Hall 1

09:00 - 10:30 Aesthetic Dermatology-3

Chairs: Leon Kircik, Filiz Kuşak

09:00 - 09:15	New Research On HA Fillers	Filiz Kuşak
09:15 - 09:30	Local Anesthesia For Aesthetic Dermatology: Whats New?	Pertevniyal Bodamyalı
09:30 - 09:45	Topical Peptides in Aesthetic Dermatology	Zahide Eriş Eken
09:45 - 10:00	Innovations in Dermatology Radiofrequency Ablation in Dermatology	Fatih Göktay
10:00 - 10:15	Microsphere Technology: Hype Or Help?	Leon Kircik
10:15 - 10:30	Evidence-Based Skincare	Leon Kircik

10:30 - 11:15 Coffee Break

11:15 - 12:30 Aesthetic Dermatology-4

Chairs: Laura Atzori, Şükran Sarıgül

11:15 - 11:30	When Aesthetic Concerns are Clues of More Severe Diseases?	Laura Atzori
11:30 - 11:45	When The Cure is Worse Than The Disease?	Laura Atzori
11:45 - 12:00	Thread Complications	Recep Dursun
12:00 - 12:15	Pla Thread Uses For Antiaging	Şükran Sarıgül

3rd INDERCOS

National Dermatology & Cosmetology Congress with International Participants

14-17 MARCH, 2018
HILTON ISTANBUL BOSPHORUS HOTEL
ISTANBUL, TURKEY



17 March 2018, Saturday

Hall 2

08:00 - 09:05 Oral Presentation-5

Chair: Necmettin Akdeniz, Erdinç Terzi

08:00 - 08:05	OP-49 Does Systemic Isotretinoin Treatment Effects Female Sexual Functions?	Şule Güngör
08:05 - 08:10	OP-50 A Rare Presentation of Discoid Lupus Erythematosus: Comedogenic DLE	Yavuz Tezcan
08:10 - 08:15	OP-51 Wound Healing & Cosmetic Procedures; Back to Basics	Eman Moustafa Sanad
08:15 - 08:20	OP-52 Nevoid Hyperkeratosis of the Nipple and Areola	Merve Işık
08:20 - 08:25	OP-53 In This Study, Patients Aged 15-35 Years with Vitiligo and 30 Sex- and Age - Matched Apparently Healthy Controls were Included. The Vitiligo Size Representative Area was Estimated. The Results Showed That by Applying Sinax Ointment on Vitiligo for 60 d	Sina Sadreddini
08:25 - 08:30	OP-54 Unilateral Nevoid Telangiectasia	Ladan Rastgar
08:30 - 08:35	OP-55 Optimizing the Results of Management of Post Acne Scars	Eman Moustafa Sanad
08:35 - 08:40	OP-56 Serum Lipoprotein(a) and Lipid Levels in Patients with Chronic Plaque Type Psoriasis.	Melek Aslan Kayıran
08:40 - 08:45	OP-57 Acne Therapy from Vegetable Oil Derivatives	Emad Al Mulla
08:45 - 08:50	OP-58 Lichen Planus and Its Management: An Evaluation	Mohammad Abdul Hye
08:50 - 08:55	OP-59 The Impact of Disease Severity and Quality of Life on Patients with Acne Vulgaris	Melek Aslan Kayıran
08:55 - 09:00	OP-60 Evaluation of (Serum) Brain-Derived Neurotrophic Factor Levels And The Impact Of Systemic Isotretinoin Treatment On Brain-Derived Neurotrophic Factor Levels In Patients With Acne Vulgaris	Mehmet Şimşek
09:00 - 09:05	OP-61 Acanthosisnigricans Combined with Skin Tags as Clinical Marker for Evaluation of Obesity in Turkish Population	Tugba Kevser Uzuncakmak



3rd INDERCOS

National Dermatology & Cosmetology Congress with International Participants

14-17 MARCH, 2018
HILTON ISTANBUL BOSPHORUS HOTEL
ISTANBUL, TURKEY

17 March 2018, Saturday

Hall 2

09:05 - 10:30 Anti-Aging Treatments-2

Chairs: Kansu Büyükaşar, Asja Prohic

09:05 - 09:15	Melatonin For Skin and Hair	Aslı Kaptanoğlu
09:15 - 09:30	Hormonal Therapy of Intrinsic Aging	Aslı Kaptanoğlu
09:30 - 09:45	Mitochondrial Theory of Aging	Kansu Büyükaşar
09:45 - 10:00	Smoking and Skin Aging	Deniz Demirseren
10:00 - 10:15	Alcohol and Skin	Asja Prohic
10:15 - 10:30	Sport and Skin: Benefits (Anti-Aging Exercises) and Damage	Gül Yıldırım

10:30 - 11:15 Coffee Break

11:15 - 12:30 Skin Wounds & Vitiligo

Chairs: Severin Laeuchli, Tamer İrfan Kaya

11:15 - 11:30	Wounds and Becaplermin	Necmettin Akdeniz
11:30 - 11:45	Wound Healing	Tamer İrfan Kaya
11:45 - 12:00	Wound Care and Scars	Severin Laeuchli
12:00 - 12:15	Closing Lecture Vitiligo	Torello Lotti
12:15 - 12:30	Discussion	

The first e-learning platform dedicated to
dermatology, plastic surgery and aesthetic science

BE PART OF THE FASTEST GROWING COMMUNITY
MORE THAN 11 000 PHYSICIANS

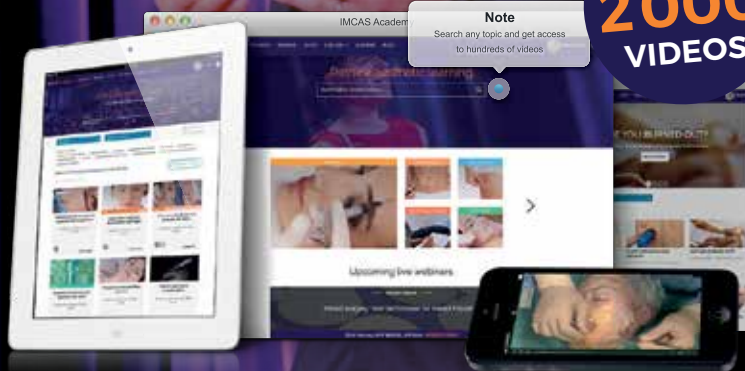IMCAS Academy

Subscribe now online

ACADEMY.IMCAS.COM

ONLY
390 USD
FOR 12-MONTH
FULL ACCESS
SUBSCRIPTION

FOLLOW US
IMCASACADEMY



MARK YOUR 2018/2019 CALENDAR



IMCAS AMERICAS
CARTAGENA - MARCH 15 TO 17



IMCAS ASIA
SEOUL - JULY 27 TO 29



IMCAS 20TH ANNUAL
WORLD CONGRESS
PARIS - JAN 31 TO FEB 2



Lecture Summaries



3rd INDERCOS

National Dermatology & Cosmetology Congress with International Participants

14-17 MARCH, 2018
HILTON ISTANBUL BOSPHORUS HOTEL
ISTANBUL, TURKEY



WOMEN WORKING COMMUNITY IN DERMATOLOGY

Hilal Gökalp

Although there are many female physicians specializing in dermatology now, the situation was very different in the past. The history of medicine shows that women had to overcome many challenges and had to be very successful to do so. Males were dominant and supported in dermatology throughout history, as in every field. It has not been easy for women to receive a medical education, starting in antique periods. This tradition continued during the European Renaissance. However, Margaret Bulkley (1799-1865) registered at Edinburgh University dressed as a male and using her uncle's name (James Barry) to defy this tradition. Dr. Bulkley joined the British Army as a surgeon 3 years after her graduation and is the first known female physician. Her true identity was only revealed after her death.

The first faculty of medicine to officially accept women was the Female Medical College of Pennsylvania in 1850. The first female to graduate from a faculty of medicine in this oppressive environment was Dr. Elizabeth Blackwell (1821-1910). An increasing number of women became employed in the medical sector in the following years despite numerous obstacles. The American Medical Women's Association was founded in 1915, the Medical Women International Association in 1919 and the Brazilian Association of Medical Women in 1960. All these associations were mainly established to support the role of women in medicine, fight against discrimination and elaborate on matters related to female health.

Women are at the forefront of the specialty of dermatology today. Despite the lack of clear information on when dermatology appeared in history, some dermatological procedures are known to have been performed by women in ancient Egypt. Modern dermatology appeared in Europe in the 15th and 16th centuries. The work of males was emphasized in the initial stages of the history of Dermatology, as in all specialties. However, the entry of women into faculties of medicine has gradually increased the number of females specializing in dermatology. Dr. Rose Hirschler (1886-1963) was the first female dermatologist to specialize in the USA. She is celebrated and commemorated by the Rose Hirschler award given to eminent female dermatologists by the Women's Dermatology Society every year. The Women's Dermatology Society was actually established by a male in 1973. Dr. Walter Shelley, the Chief of Dermatology at Pennsylvania University, saw that female dermatologists were in the minority and had very little social interaction with each other, and wanted to establish an association that would enable them to come together and help each other achieve personal and professional success. The Women's Dermatology Society was born in this way. Similarly, female dermatologists started to become a part of committees in Brazil in the 1970s. Dr. Orcanda Andrade became the first female Head of the Brazilian Dermatology Society in 1990 and more than 65% of the same Society's members are female now. The increased recognition of the success of women in medicine and dermatology in the current era has also increased the respect they receive. Their role in scientific meetings is constantly increasing. Women have been faced with many challenges throughout the history of medicine and dermatology. However, they have proven that they are at least as efficient and skillful as men in medicine and especially dermatology with their manual dexterity, elegance and persistence.



3rd INDERCOS

National Dermatology & Cosmetology Congress with International Participants

14-17 MARCH, 2018
HILTON ISTANBUL BOSPHORUS HOTEL
ISTANBUL, TURKEY

WOMEN IN DERMATOLOGY: CHALLENGES AND SUCCESSES IN TURKEY

Hilal Gökalp

Female dermatologists in Turkey have had to overcome many challenges, just like those around the world. Once the acceptance of females into the faculties of medicine began, a few female physicians started to train to become a physician. The first Turkish female dermatologist, Dr. Hamidiye Abdürrahim (Rauf) Maral (1895-1975), worked as a mathematics and biology teacher before starting medical school. She registered at the Faculty of Medicine of the American Female High School in the 1921/1922 period. Following her graduation in 1928, she specialized in dermatology, physical treatment and radiotherapy. Dr. Maral also worked as the assistant of the famous physician Prof. Friedrich Dessauer for a while. Dr. Maral saw patients across many specialties and also worked continuously as a teacher for 50 years.

Today, there are approximately 2200 dermatologists (specialists and residents) in Turkey and 65% of them are female. Many successful famous female dermatologists were eventually trained besides Dr. Maral. However, Türkan Saylan (1935-2009) is definitely the most important Turkish female dermatologist. Dr. Saylan has taught others not only with what she has said and written, but also by the way she lived. She was able to see disease from the patient's point of view and approach the patient as a human being, not as an organism carrying the disease, making her famous as the "physician who is also a friend." Dr. Saylan was very much affected by the isolation of leprosy patients while a medical student and wanted to become a Dermatologist and work at the Leprosy Ward as a volunteer. Saylan continued to work a member of the medical faculty but was also involved for extended periods in public health initiatives in regions with a high incidence of leprosy. She founded the Fight Against Leprosy Association in 1976 and the İstanbul University Leprosy Research and Application Center in 1980. She also tried to help the thousands of children of leprosy patients receive an education. She was very successful in the work to eventually eradicate leprosy from our own country and the world and became one of the foremost global authorities on leprosy with the work she carried out in this field. Thanks to her efforts, the World Health Organization (WHO) declared Turkey as one of the countries where "leprosy has shown a significant decrease." Dr. Saylan also received the International Gandhi Award in India in 1986 for her work on leprosy.

She witnessed the life of the girls and women in the eastern and southeastern provinces of our country during her visits and became heavily involved in attempts to ensure gender equality in education. She therefore played a role in establishing the Association for the Support of Contemporary Living in 1989. She became the association's president in 1990 and continued in this capacity for many years. The objective of the association is to make especially girls receive an education and become powerful members of the society and it has provided education grants to almost 40,000 students since 1995.

Dr. Saylan has worked at an extraordinary tempo all her life for health, education, modernization, democracy, and women's and human rights and there are many books on her life and work. She set an example for us all by creating awareness of the importance of education with her work and died at the age of 74 on May 19, 2009. The annual Türkan Saylan Arts and Science Awards were established after her death to ensure her memory lives on and are awarded on the anniversary of her death to those involved in scientific work and art that will take her approach to life to future generations.

3rd INDERCOS

National Dermatology & Cosmetology Congress with International Participants

14-17 MARCH, 2018
HILTON ISTANBUL BOSPHORUS HOTEL
ISTANBUL, TURKEY



ACRALLY DISTRIBUTED DERMATOSES: VASCULAR DERMATOSES (PURPURA AND VASCULITIS)

Ralf Singer

Diseases presenting with purpura are caused by a variety of different etiological factors such as thrombocytopenia, abnormalities of platelet function, abnormal blood vessels or decreased support of blood vessels, capillaritis, vaculitis or vasculopathic disorders (microvascular occlusion syndromes). In this presentation, acrally located purpuric lesions caused by vasculopathies will be discussed.

Vasculopathic disorders also have a variety of etiologies. These are embolization, platelet plugging, cold related agglutination, vascular coagulopathies, systemic coagulopathies, vessel-invasive microorganisms and metabolic disorders.

Cholesterol emboli is caused by embolization of the contents of an atherosclerotic plaque from a proximal large-caliber artery to distal small to medium arteries causing end-organ damage by mechanical plugging and an inflammatory response.

Cryoglobulins can cause disease through occlusion of blood vessels and immune complex-mediated vasculitis. Type I cryoglobulinemia which is associated with monoclonal gammopathies results in a vasculopathic process caused by cold related agglutination.

Livedoid vasculopathy is a chronic thrombo-occlusive cutaneous vasculopathy that presents with purpura and recurrent painful ulcers on the distal lower extremities. Antiphospholipid syndrome which is characterized by the occurrence of venous and arterial thromboses, often multiple, and recurrent fetal losses may present with livedo reticularis/racemosa, retiform purpura, acral gangrene or splinter hemorrhages.

Purpura fulminans is a severe form of disseminated intravascular coagulation which results in extensive areas of skin necrosis usually over the extremities and buttocks. It is most frequently found in the setting of sepsis. Neonatal purpura fulminans develops in the background of protein C and S deficiency.

Calciophylaxis is a vasculopathic process characterized by the presence of calcification of the media of muscular arteries and smaller sized caliber vessels developing in the setting of chronic renal failure.



3rd INDERCOS

National Dermatology & Cosmetology Congress with International Participants

14-17 MARCH, 2018
HILTON ISTANBUL BOSPHORUS HOTEL
ISTANBUL, TURKEY

BEHÇET DISEASE IN PREGNANCY

Mehmet Melikoğlu

Behcet disease (BD) is a multisystemic vasculitis. The prognosis is better in female gender. Most studies the outcome of pregnancy was generally good in BD patients, Disease manifestations and fetal outcome also not worse most of them.

In Ben-Chetrit E. review; *"Most cases the course of BD was unchanged or improve during pregnancy. The outcome of pregnancy in BD patients was poorer than that in healthy individuals."* In Dr Iskender and friends study result; *"Patients with BD only had a higher rate of vascular complications during pregnancy and other obstetric complications were not increased and neonatal outcomes were not negatively influenced by BD."*

Colchicine is the one of the main drug in BD disease. Colchicine usage; Category C and there are no controlled studies in women or studies in women and animals are not available. Drugs should be given only if the potential benefits justify the potential risk to the fetus.. Use during pregnancy in the treatment of familial Mediterranean fever has not seen an increase in miscarriage or teratogenic effects but data was limited. Concomitant use of cyclosporine, diltiazem, verapamil, may increase the risk of myopathy. Diav-Citrin O and friends carried out a prospective observational comparative cohort study regarding colchicine exposure during pregnancy including contacts to 2 Teratology Information Services in Israel from 1994 through 2006. And *"Their study suggests that colchicine does not appear to be a major human teratogen, and, probably, has no cytogenetic effect."*

In our experience we use colchicine in pregnant BD patients besides the benzathine penicillin treatment. Because infections(especially streptococcal infections) flares the attacks in BD patients. Calgüneri and friends study results; *"Penicillin treatment was demonstrated to offer adjunctive benefits in the prevention of arthritis episodes which are not obtainable with colchicine monotherapy. This finding could provide additional evidence for antigen triggering in the pathogenesis of Behçet's disease."* And Calguneri and friends also in another study they found out that prophylactic benzathine penicillin combined with colchicine is more effective in controlling mucocutaneous manifestations of BD than colchicine alone. Al Waiz MM and friends also found out similar results.

There are some studies in the literature that's about successful treatment with infliximab or adalimumab for Behçet disease during pregnancy. Some studies in Ocular BD reported that both severity and frequency of ocular attacks improved in most of patients treated with INF- α 2a. In Brojeni Y and friends article they showed that interferon-alpha does not significantly increase the fetal risks above that in general population rates review of the safety of interferon alpha.

In some studies shows us exacerbation is possible in pregnant BD patients. Clinical exacerbation of BD occurred most commonly during the first trimester. The most frequent manifestations of the clinical exacerbation are the occurrence of oral ulcers in intensity and severity during pregnancy. Pregnancy is mostly stated to be related to disease remission in about half of the patients, besides its influence is variable.

3rd INDERCOS

National Dermatology & Cosmetology Congress with International Participants

14-17 MARCH, 2018
HILTON ISTANBUL BOSPHORUS HOTEL
ISTANBUL, TURKEY



URTICARIA AND PREGNANCY

Emek Kocatürk Göncü

The human placenta is an endocrine organ, secreting hormones that enable the growth and development of the fetus and the physiologic changes in the maternal body. Among the hormones secreted by the placenta, the steroid hormones (estrogen and progesterone) play a crucial role in maintaining pregnancy. Estrogens and progesterones are considered immunomodulators because of their influence on many cells of the immune system, including CD4+ T cells, dendritic cells, B cells, eosinophils and mast cells. While estrogens usually enhance humoral immunity, progesterones and androgens are considered suppressors; both take part in the fluctuation of immune cell function during normal states, such as the menstrual cycle, and in disease states, such as autoimmunity or allergy. Chronic urticaria is a female prone disease which has exacerbations during premenstrual period, albeit there no information on the course of the disease during pregnancy.

For the treatment of CSU during pregnancy, nonsedating H1-antihistamines are the first choice, and most first-generation antihistamines should be avoided—especially hydroxyzine. Cetirizine or loratadine (category B—no risk in animal studies) are the preferred options, as well as in breastfeeding women. Corticosteroids are not recommended in the first trimester because of a possible increased risk of cleft palate; prednisone and methylprednisolone, however, are classified as category B. Cyclosporin is classified as category C. There are case reports on the safe use of omalizumab in pregnant women with CSU, based on the observational studies in asthmatic patients it is classified as category B.



3rd INDERCOS

National Dermatology & Cosmetology Congress with International Participants

14-17 MARCH, 2018
HILTON ISTANBUL BOSPHORUS HOTEL
ISTANBUL, TURKEY

THE USE OF BIOLOGICALS IN CUTANEOUS ALLERGIES PRESENT AND FUTURE

Torsten Zuberbier

While in other areas of dermatology, like psoriasis, since many years a high variety of biologicals is available for treatment in cutaneous allergies, this development has only started very recently. Currently, two biologicals are licensed: Omalizumab for chronic spontaneous urticaria and dupilumab for atopic dermatitis. Omalizumab has now been licensed for chronic spontaneous urticaria for several years as a third line treatment as an add-on to the second line treatment of chronic spontaneous urticaria with highdose antihistamines.

Omalizumab is a highly efficient drug with a response rate of more of 80% of those patients refractory to high dose antihistamines. The effect of omalizumab is not limited to chronic spontaneous urticaria for which it is licensed, but is equally efficient in treating chronic inducible urticarias, although off-label for these diseases.

Unlike in asthma, omalizumab does not need to be dosed according to weight and IgE levels. The optimal dose shown in clinical trials is 300mg every 4 weeks. In atopic dermatitis, as second cutaneous allergic disease where a biological is available, this progress has only been noted since late last year.

Dupilumab targeting IL-4 and IL-13 is highly efficient as a systemic treatment with response rates similar or better than cyclosporine A but with a far better risk-benefit ratio. The drug can be selfadministered at two-week intervals with subcutaneous injections. An improvement of skin lesions can be expected within the first four weeks of treatment. Both omalizumab and dupilumab have an excellent safety profile, and according to our current knowledge also do not show any long-term tachyphylaxis or long-term side effects.

3rd INDERCOS

National Dermatology & Cosmetology Congress with International Participants

14-17 MARCH, 2018
HILTON ISTANBUL BOSPHORUS HOTEL
ISTANBUL, TURKEY



CHRONIC URTICARIA AS A SYSTEMIC DISEASE

Torsten Zuberbier

Chronic urticaria (CU) is defined as the occurrence of wheals, angioedema or both over a period of at least six weeks. Both chronic spontaneous urticaria forms exist as well as inducible urticarias. It is associated with a high impact on the quality of life and a considerable societal burden. The impact on the quality of life has been shown to be comparable to that in patients with ischemic heart disease. CU mostly affects patients between twenty and forty years of age, who are part of the working population, and has a considerable impact at the productivity at the workplace. In addition, physical discomfort and signs, the unpredictability of attacks, disruption of sleep and cosmetic impact lead to a high burden of disease. In understanding CU, it is important to know that the unpredictability of an outbreak, especially in the chronic spontaneous urticaria form in any unforeseen area of the skin, is part of the problem for the patient. The patient never knows: Is he going to wake up with wheals on his face or anywhere else on the body. While it is not clear which areas of the skin are affected in the individual person, it is however now clear that the underlying inflammation of chronic urticaria is part of systemic disease burden. There is growing evidence that not only there is an association between chronic urticaria and a variety of disorders such as autoimmune diseases, atopy, infections and metabolic conditions, but also that an increased reactivity and number of mast cells is present in uninvolved areas of skin and that there is an infiltrate, although mild, of leukocytes to be noted.



3rd INDERCOS

National Dermatology & Cosmetology Congress with International Participants

14-17 MARCH, 2018
HILTON ISTANBUL BOSPHORUS HOTEL
ISTANBUL, TURKEY

DERMATOLOGIC EMERGENCY: TEN (TOXIC EPIDERMAL NECROLYSIS)

Miloš Nikolić

Toxic epidermal necrolysis (TEN) or Lyell's syndrome is an acute multisystem life-threatening disease characterized by generalized epidermal necrosis and profound toxic systemic reaction. The possible etiologic agents include drugs, infections, vaccination, and autoimmune diseases. In some cases, no precipitating cause can be detected. The histopathology reveals separation of necrotic epidermis at the dermal-epidermal junction of both skin and extracutaneous epithelia.

Patients who develop TEN in the context of HIV/AIDS, malignancy, or autoimmune diseases might have a disease distinct from TEN in an otherwise healthy individual exposed to an inciting medication.

The course of TEN in children, even though dramatic at onset, when managed appropriately, leads to lower mortality. At present, the limited published evidence does not clearly delineate differences in epidemiology, pathogenesis, and prognosis of TEN in children as compared with adults.

Pulsed high-dose intravenous corticosteroids and IVIg, given as early as possible, seem to improve the outcome of TEN patients, but results from different reports are variable. Patients treated exclusively with supportive measures seem to have higher morbidity and mortality.

At present, the suggested approach to TEN patients might be:

1. Discontinuation of all nonessential drugs
2. Admit to intensive care or burn unit
3. Skin biopsy (in high suspicion of TEN, initiate treatment before the definite results)
4. Intravenous fluids, correction of electrolytes, caloric replacement
5. Strict aseptic/antiseptic measures
6. No prophylactic antibiotics
7. Nonadherent silver-based (AgNO₃) dressings (avoid Ag-sulfadiazine if known or suspected sulfonamide hypersensitivity)
8. Bland emollients to involved skin, mucous membranes
9. Ophthalmology consultation
10. Pulmonary toilet with awareness that respiratory epithelium may be involved
11. Surveillance cultures of skin, oral mucosa, sputum, blood – antibiotics if necessary
12. Early initiation of pulsed intravenous dexamethasone, 1.5 mg/kg body weight/day, over 3 days
13. At the same time, together with intravenous corticosteroid pulses, IVIg, total dose 3 g/kg, given over 3 days (check serum IgA level to exclude deficiency, favor initiation of IVIg if results not immediately available).

3rd INDERCOS

National Dermatology & Cosmetology Congress with International Participants

14-17 MARCH, 2018
HILTON ISTANBUL BOSPHORUS HOTEL
ISTANBUL, TURKEY



DIETETIC INTERVENTIONS IN ALLERGIC CONTACT DERMATITIS

Radoslaw Spiewak

A typical route of elicitation of symptoms in allergic contact dermatitis (ACD) is via skin contact, however, systemic reactivations of ACD may also occur under various symptomatology and terminology (SDRIFE, Baboon syndrome, or a misnomer "systemic contact dermatitis"). While thinking of dietetic interventions in allergic contact dermatitis one has to consider the following questions: 1) in which cases it is justified to suspect that an ingested hapten causes allergic reaction, 2) how to verify the causal relationship between the hapten and current disease, and 3) in which cases dietary interventions are justified? Clinical studies and cases that contact allergy to haptens present in food should be suspected when symptoms are consistent with the clinical picture of systemic reactivation of allergic contact dermatitis or systemic photoallergy. Positive patch test result is not sufficient as confirmation of causality – the clinical relevance should be judged by means of double-blind placebo-controlled provocation with hapten in question. If such challenge appears not feasible, the relevance may be confirmed indirectly by the clearance of symptoms after introducing a low-hapten diet with remission lasting for at least 4 weeks after withdrawal of pharmacotherapy, and the recurrence of symptoms following the return to the old diet. In the majority of cases, "nickel-free" or "low nickel" diets are burdensome and with no real benefit. According to literature, only 1-11% of patients with clinical nickel allergy will experience benefits from "nickel-free" diets. Indiscriminate introduction of such dietary regimens in every patient with positive patch test to nickel is not recommended.



3rd INDERCOS

National Dermatology & Cosmetology Congress with International Participants

14-17 MARCH, 2018
HILTON ISTANBUL BOSPHORUS HOTEL
ISTANBUL, TURKEY

CUTANEOUS MANIFESTATIONS OF DRUG ALLERGY AND HYPERSENSITIVITY

Radoslaw Spiewak

The skin is frequently involved in the drug hypersensitivity reactions (DHR) with a wide spectrum of clinical manifestations. The diagnosis be difficult because of multiple differential diagnoses. A correct classification is important for the effective diagnosis and management. At present, new guidelines are prepared under the auspices of the European Academy of Allergy and Clinical Immunology (EAACI), with the aim to provide precise definitions and criteria to correctly classify cutaneous DHR. Within this classification, cutaneous hypersensitivity reactions to drugs are divided into allergic urticaria and angioedema, maculopapular exanthema, Acute generalized exanthematous pustulosis (AGEP), allergic vasculitis, Drug reaction with eosinophilia and systemic symptoms (DRESS), Stevens Johnson's syndrome/ toxic epidermal necrolysis (SJS/TEN), symmetrical drug-related intertriginous and flexural exanthema (SDRIFE), fixed drug eruption (FDE), generalized bullous fixed drug eruption (GBFDE), and systemic photoallergic reactions. Erythema multiforme (EM) reactions are excluded from the classification, as there are no convincing cases of this reaction clearly caused by a drug, rather than infection. Lichen planus is excluded for similar reasons, as the drug-related cases can be classified as lichenoid reaction, thus falling into the category of SDRIFE (synonymous with systemic reactivation of allergic contact dermatitis).

CONTACT ALLERGY TO COSMETICS

Radoslaw Spiewak

Cosmetic ingredients, next to metals, are the most frequent sensitizers. They may cause both "classical" contact allergy, as well as photoallergic dermatitis. The most frequent sensitizers in cosmetics are fragrances, which may sensitize both via direct skin contact and, due their volatility and fat solubility via the airborne route. Many cosmetic ingredients are also used as food additives, which reminds us of the possibility of systemic reactivation of allergic contact dermatitis (SRACD). Cosmetic products labeled as "hypoallergenic" may contain strong sensitizers, the same is true for "ecological" and "organic" cosmetics. The most frequent photosensitizers are sunscreens. Cross sensitizations and co-sensitizations are to be considered between organic sunscreens and certain drugs (e.g. ketoprofen, fenofibrate). Patch testing and photopatch testing to own cosmetics should be a routine in every patient with chronic, recurrent dermatitis, whenever patch tests to baseline series are indicated.

3rd INDERCOS

National Dermatology & Cosmetology Congress with International Participants

14-17 MARCH, 2018
HILTON ISTANBUL BOSPHORUS HOTEL
ISTANBUL, TURKEY



ATOPIC DERMATITIS: CURRENT TREATMENT GUIDELINES

Małgorzata Sokołowska-Wojdyło

Atopic dermatitis (AD) is frequent condition in medical practice. The therapeutic methods need to rapidly control symptoms of the disease, improve quality of life and prevent exacerbations. It can be done only if physician is considering all aspects of the disease: inflammation, infection, irritation, itch, ichthyosis (dry skin), immunological influences, and co-morbidities (Dinulos JG et al. Curr Opin Pediatr. 2018 Feb;30(1):161-168.). Because of chronic and relapsing nature of the disease, therapy needs to be well tolerated and encourage good compliance, what is quite difficult in many cases. In spite of existing recommendations (Nowicki R. et al. Postepy Dermatol Alergol. 2015;32(4):239-49)- there are still many questions. Ex. widely used non-sedative antihistamines have not been proved to reduce itch in patients with AD. Also the sedating antihistamines have seemed to provide benefit only in sleep control and co-morbidities as allergic rhinitis (not AD symptoms themselves) (He A. Et al. J Am Acad Dermatol. 2018 Jan 6) – so should be used or not? What about moisturizers, topical steroids, calcineurin inhibitors (topical and oral), phototherapy in the era of dupilumab and anti-IL31 Ab (Boguniewicz M. Et al. Ann Allergy Asthma Immunol 120 (2018) 10–22 , Dinakar Ch. Et al. Ann Allergy Asthma Immunol 120 (2018) 8–9) ?



3rd INDERCOS

National Dermatology & Cosmetology Congress with International Participants

14-17 MARCH, 2018
HILTON ISTANBUL BOSPHORUS HOTEL
ISTANBUL, TURKEY

TEXTILES AND CLOTHING IN DERMATOLOGY

Rafet KOCA

Textile is a type of material composed of natural or synthetic fibers. They are many types of textile fibers. These are: natural and synthetic fibers. Animal-based (wool or silk), plant-based (linen and cotton) and mineral-based (Asbestos) fibers are natural fibers. Polyester, nylon, spandex, acrylic and rayon are good examples for synthetic fibers. Generally, the actual fibers are not allergenic; rather, the dyes used to color the fabrics or formalin finishing resins added to make them wrinkle-resistant, shrink-proof, or easily laundered, are the responsible contactants. Textiles play a major role in both the etiology and the treatment of various types of dermatitis. All fibers can cause irritant and allergic contact dermatitis (ACD). Prevalence data commonly indicate that allergic contact dermatitis caused by textiles seems to be rare. However, dermatologists might underestimate the prevalence of textile allergy, and suspect other causes for eczema rather than contact allergy to textiles. However, in recent years, the quality of the garments marketed in European countries and in Turkey has significantly changed, because of globalization and the consequent increase in the importation of clothing. There are many reasons of allergic reactions to textiles or clothes. These are: Dyes, formaldehyde, finishing resins, rubber materials, chemical additives, glues, tanning agents and metallic fasteners. But the main culprits in the elicitation of textile-associated ACD are dyes, formaldehyde (FA) and FA finishing resins. The most common class of dyes implicated in textile induced ACD are disperse dyes (DDs). DDs are the most common and well-known contact sensitizers among textile dyes. They are cheap and can supply a complete rainbow of colors. These dyes are loosely held on the fabric structure and easily rubbed off on the skin. DDs are used for the coloring of synthetic textile fibers such as polyester, nylon, acrylic, modacrylic, acetate, and polyethylene terephthalate. Disperse dyes are slightly water-soluble compounds, it will penetrate into the fiber. Any undissolved particles of dye remain on the outside of the fiber where they can bleed and are sensitive to surface abrasion. Furthermore moisture has been reported to facilitate the release of dyes from textile fibers. Tight skin contact to garments is supposed to increase the risk of the development of textile contact dermatitis (TCD). During contact there can be perspiration which involves moisture transport between the skin and the dyed and finished clothing items. ACD because of textiles is most severe in areas of perspiration and friction where garments have greatest skin contact, such as the axillary lines, medial thighs, posterior neck, and antecubital and popliteal folds. On clinical examination erythematous patches with or without fine desquamation are a common form of TCD.

When there is a suspicion of textile-related contact allergy, patch testing with the European baseline series can help to diagnose TCD. Because the European baseline series include textile dye mix (TDM) allergen. TDM may be a useful marker of textile contact allergy. Disperse azo dyes include para-amino compounds. Therefore it may cross-react with a number of structurally similar para-amino compounds, including PPD, IPPD, PAAB and benzocaine.

Dark colored garments pose a risk for TCD. Because dark shades containing mixtures of several DDs, such as DO 3 and Disperse Blue. Garments manufactured from cotton, wool, silk or linen are safe. If polyester garments are worn, light-colored clothes are safer than dark-colored ones. It may be unsafe to wear dark-colored synthetic clothing. The best way to protect against textile allergy will be to check the label when you buy a clothes.

3rd INDERCOS

National Dermatology & Cosmetology Congress with International Participants

14-17 MARCH, 2018
HILTON ISTANBUL BOSPHORUS HOTEL
ISTANBUL, TURKEY



TREATMENT OF FACIAL REDNESS: WHAT'S NEW?

Maja Hofmann

Facial redness can be caused by different dermatological and internal diseases. Classically, in dermatology facial redness occurs in patients with rosacea and in patients with atopic dermatitis. For patients with atopic dermatitis normally only local treatment opportunities or systemic treatment for AD are available. In rosacea patients treatment options include local therapy as well as laser therapy. Laser therapies have been shown to provide symptom improvement in patients with erythema and telangiectasia of rosacea; however, they are associated with side effects such as erythema. A new local therapeutic option in patients with moderate to severe redness of the face is the alpha adrenergic receptor agonist brimonidine. Brimonidine is available as 3 mg/g gel, which is approved in Europe and the US for treating rosacea patients. Combinatorial treatment with pharmacological agents and laser have demonstrated better efficacy, fewer side effects and continued long-term remission compared with monotherapies. Also using brimonidine 3 mg/g gel to target post-laser treatment erythema is highly effective in minimising refractory erythema. Continued use of brimonidine 3 mg/g gel provides a sustained reduction of erythema, increasing the visibility of other signs and symptoms of rosacea that may be present. This can facilitate the treatment of these additional signs and symptoms. Also studies for another alpha1 A receptor agonist Oxymetazolin are available, a product which is approved in the US to treat moderate to severe redness of rosacea patients.



3rd INDERCOS

National Dermatology & Cosmetology Congress with International Participants

14-17 MARCH, 2018
HILTON ISTANBUL BOSPHORUS HOTEL
ISTANBUL, TURKEY

CATS AND DOGS RELATED SKIN DISEASES AND DERMATOLOGY

İdil Ünal

Cats and dogs are our faithful and lovely friends. Many households have one or more species of pet animal, mostly dogs and cats. They bring enormous social and health-related benefits to people but they can also transmit several diseases to their owners. Many dermatological manifestation can be a sign of an infection related to pets. When a dermatologist made a diagnosis that suggesting a pet related infection, firmly control measures about the pets health should be taken.

An infection mainly with skin lesions transmitted from cats an dogs can be acquired by direct contact or indirectly. Dermatophytosis and scabies are transmitted by direct contact with pets and can infect both humans and animals. Dogs and cats may show clinical signs or be subclinical carriers. *Microsporum canis* is the most common dermatophyte in cats and dogs, with cats considered to be the most important reservoir hosts. Genetic factors, preexisting skin diseases, an immunocompromised state make people more susceptible to the infection. The pets dont need to rehomed, but appropriate management should be performed especially in the situation of an immunocopromised owner. The scabies mite is highly communicable among dogs and may infest humans, but cats are relatively resistant. Persons in contact with an infested dog may be variably affected, and they are only transient hosts for the mites unless there are repeated exposures.

The pet related infections that can be presented with skin lesions are mainly toxoplasmosis, bartonellosis, tick-borne infections, leptospirosis and echinococcosis. Avoidance and treatment of these infections can be successful with a good collaboration of the physicians and veterinarians. The dermatological evaluation should routinely include questions about whether the family keeps pets. It is unnecessary for families to rehome pets diagnosed with dermatophytosis (ringworm), scabies, toxoplasmosis, bartonellosis, tick-borne infection or leptospirosis if infections are managed appropriately

3rd INDERCOS

National Dermatology & Cosmetology Congress with International Participants

14-17 MARCH, 2018
HILTON ISTANBUL BOSPHORUS HOTEL
ISTANBUL, TURKEY



CATTLE-RELATED SKIN DISEASES

Ahmet Metin

Animals have played a great and important role in human society for centuries. They provide essential sources of meat, milk, dairy products, fertilizer for plants, clothing, and power for traction. This role continues to be vital for the lives of the people as cattle are often an important source of food security and revenue. In many developing countries, recent urbanization, population growth, and rising incomes have resulted in rapid growth and transformation of livestock production in the absence of a public health framework, thus creating an increased opportunity for zoonotic diseases to threaten human health even in developed countries.

Animal related skin diseases are known as zoonotic skin diseases that are infectious diseases transmissible from vertebrate animals to humans. Cattle related zoonotic diseases are called also bovine related infectious skin diseases that transmissible from cattle to human and vice versa on some appropriate terms. They include various diseases caused by many of pathogenic agents. They may confront veterinarians as well as general practitioners, pediatricians, infectious disease specialists, and microbiologists with special diagnostic and therapeutic problems.

Zoonotic cattle diseases consist of 46 contagious diseases in which bacteria, viruses, fungi, parasites and prions play a role as pathogens. Nineteen (% 41.30) of these cattle zoonoses are transmits not only from cattle to human, but also transmits human to humans, which is a prominent problem for public health. Significant percentage (54%) of cattle zoonoses are among the emerging or reemerging Infectious Diseases. The majority of zoonotic cattle diseases are worldwide in distribution. They can be transmitted to humans through various routes of exposure including direct contact, ingestion as meat and dairy products, cutaneous, inhalation, and by infected vectors. Of the identified zoonotic pathogens, twenty four (52.17%) of these pathogen are on the bioterrorism list of CDC. Clinical presentation of zoonotic diseases of cattle is very diverse. Systemic infection, cutaneous findings, cardiologic, pulmonary, intestinal, ocular and neurological involvement are the most obvious ones. Twenty-five (54.34%) of the zoonotic infections may transmit from animal-to-human by cutaneous route and twenty-nine of them (63.03%) have presents various cutaneous manifestations.

The method of combating these diseases requires the fight against diseases in animals as well as the treatment of humans. This presentation, will be focusing on cattle-related zoonotic skin diseases, by compressing on the clinical and microbiological characteristics of zoonotic cattle disease that, occurring both in animals and humans.

References

- McDaniel CJ, Cardwell DM, Moeller RB, Jr., Gray GC. Humans and cattle: a review of bovine zoonoses. Vector Borne Zoonotic Dis 2014;14:1-19.
- Sing A: Zoonoses: infections affecting humans and animals : focus on public health aspects. 2015.
- Bauerfeind R, Von Graevenitz A, Kimmig P, et al.: Zoonoses : infectious diseases transmissible between animals and humans. 2016.



3rd INDERCOS

National Dermatology & Cosmetology Congress with International Participants

14-17 MARCH, 2018
HILTON ISTANBUL BOSPHORUS HOTEL
ISTANBUL, TURKEY

SEA ANIMALS AND DERMATOLOGY

Ragıp Ertaş

Marine organisms can be the cause of the dermatoses that seen in dermatology clinics all over the world. Fortunately, most of the injuries are mild which can be treated by physicians with a knowledge of the cause of the pathology, although some may be significant, resulting in death.

Aquatic plants and protists can also cause cutaneous injuries. *Vibrio vulnificus* septicemia and erysipeloid are well known by dermatologists but others are uncommon. The sponges, cnidarians, echinoderms, crustaceans, and mollusks, are the main causes of the marine dermatoses. Dermatologic lesions can vary from irritant or allergic contact dermatitis to physical trauma and envenomations due to any marine/aquatic invertebrates. Also, severe systemic reactions may be seen according to marine organisms. Also, as occupational dermatoses due to marine organisms and marine injuries can be seen among the fishermen and scuba divers.

However, dermatoses due to marines can also be seen among persons who contact these animals in kitchens or beaches. Other common allergies that are encountered in the aquatic environment are: Sunburn, urticaria, jellyfish stings, and contact dermatitis to rubber equipment are. Among the infections, tinea versicolor, intertrigo, and verruca vulgaris are also widespread. A recent travel history, and/or a report of contact with an aquatic environment should alert the dermatologist to the etiology of the cutaneous problems.

The diagnosis and differential diagnosis of marine envenomation is made based upon anamnesis of patient, sudden onset of pain and single/multiple puncture wounds. When marine envenomation is suspected, the primary diagnostic considerations are; envenomation by sea snakes, jellyfish stings, cone snails or the blue-ringed octopus.

There are many treatment options. As an important rule in treating these injuries is to inactivate the venom, take control of the pain as well as localization, removal of embedded foreign material or spines, and wound irrigation to treat the local reaction or injury, and treat the systemic sequelae are important aspects of initial treatment for all marine envenomations. Emergency resuscitation (support of airway, breathing, and circulation) may be needed in patients with severe physical effects such as shock, or signs of myocardial infarction after envenomation. Deep stingray wounds may require management as for severe penetrating trauma, including exploration in the operating room.

3rd INDERCOS

National Dermatology & Cosmetology Congress with International Participants

14-17 MARCH, 2018
HILTON ISTANBUL BOSPHORUS HOTEL
ISTANBUL, TURKEY



ONYCHOSCOPY

Mustafa Turhan Şahin

Onychoscopy refers to the examination of the nail unit using a dermoscope. Many attempts have been made to use it for the diagnosis of nail disorders, most commonly pigmented lesions. Onychoscopy is very important in the diagnostic work up of nail disorders. Simple visual inspection may not be helpful in diagnosing many conditions of nails reliably. Even a nail biopsy may not give a definitive answer every time. Onychoscopy is thus a valuable aid not only in enhancing visible nail features but also in revealing cryptic features of diagnostic value. This presentation aims to summarize the current level of knowledge about onychoscopic features of various diseases of the nail unit.

ERYTHRONYCHIA-RED LUNULA

Mustafa Turhan Şahin

Longitudinal erythronychia presents with longitudinal red bands in the nail plate that commence in the matrix and extend to the point of separation of the nail plate and nailbed. This finding is becoming increasingly recognized in clinical practice. Neoplastic, inflammatory, scarring, or idiopathic processes involve the distal nail matrix, producing a groove in the ventral nail plate. The nail bed then occupies this groove and accentuates the red color of the nail bed, producing a red streak. Longitudinal erythronychia may be specific to one nail or involve multiple nails. When longitudinal erythronychia involves one nail, it may be caused by benign conditions, such as onychopapilloma, wart, warty dyskeratoma, glomus tumor, or a solitary lesion of lichen planus. Less commonly, it may be caused by malignancies, such as Bowen disease, invasive squamous cell cancer, melanoma in situ, and basal cell carcinoma. The most common causes of longitudinal erythronychia involving multiple nails are lichen planus and Darier disease. Less common etiologies are systemic amyloidosis, hemiplegia, graft-versus-host disease, and acantholytic epidermolysis bullosa.



3rd INDERCOS

National Dermatology & Cosmetology Congress with International Participants

14-17 MARCH, 2018
HILTON ISTANBUL BOSPHORUS HOTEL
ISTANBUL, TURKEY

IMPORTANT MALIGNANT AND NEW NAIL TUMORS

Eckart Haneke

Most nail tumors are rare although the distal phalanx comprises a great number of different tissues. Nail-specific tumors are even less common. Malignant nail neoplasms are mainly of keratinocytic and melanocytic origin.

Less than 20 years ago, a peculiar lesion deriving from the matrix was described, which after some re-naming, is now known as onychocytic matricoma. It is in fact an acanthoma with great similarity to seborrheic keratosis. Clinically, it causes a greyish to brown longitudinal streak in the nail with circumscribed thickening of the nail plate. The treatment of choice is tangential excision.

Approximately 25 years ago a peculiar fibroepithelial matrix tumor was observed and termed onychomatricoma. Less than 200 cases have been published until now. The nail plate is thickened, yellow with longitudinal striation in which sometimes long capillaries can be seen by dermatoscopy. End-on view shows small holes in the thickened nail. The histopathological architecture is characteristic with a fibrous tumor component of dense fine collagen fibers and many fibroblasts that form long filiform projections reaching into the nail plate and thus causing the canals. Treatment is by complete extirpation or, in case of medial localization within the nail, saucer-shape tangential excision.

A peculiar tumor was observed in a 30-year-old woman that had components of the proximal matrix, distal matrix, nail bed and undersurface of the proximal nail fold and was termed panonychia.

Onychopapilloma is a relatively frequent small lesion originating from the distal matrix and running all along the nail bed to the hyponychium. It is often embarrassing as it causes the free nail margin to split over a circumscribed V-shaped area of onycholysis.

Whether subungual acantholytic dyskeratotic acanthoma is an entity or should be regarded as an acantholytic-dyskeratotic variant of onychopapilloma remains to be seen.

Subungual filamentous tumor was described 45 years ago, but it was not fully accepted as an entity.

Onycholemmal horn was the first nail specific tumor described in 1983. It is located in the lateral part of the nail bed and histologically resembles a trichilemmal horn. Treatment is by complete extirpation.

Onycholemmal cysts are mainly a histological diagnosis. They are found in association with a variety of other nail lesions, particularly subungual melanoma, and were misinterpreted as squamous cell carcinoma.

Proliferating onycholemmal cyst is a very rare lesion without clinical characteristics.

3rd INDERCOS

National Dermatology & Cosmetology Congress with International Participants

14-17 MARCH, 2018
HILTON ISTANBUL BOSPHORUS HOTEL
ISTANBUL, TURKEY



Proliferating onycholemmal tumor may occur isolated or in association with incontinentia pigmenti. The former is slow-growing and symptomless whereas the latter grows fast and is often very painful.

Some of the benign nail-specific tumors have a malignant counterpart. Onychocytic carcinoma is a low-grade neoplasm of the matrix with resemblance to onychocytic matricoma.

Onycholemmal carcinoma is a rare neoplasm with just a few reported cases. Malignant proliferating onycholemmal cyst is also very uncommon.

Subungual Bowen disease and squamous cell carcinoma is rather common, particularly in males over 40 years of age. Clinically, it is often misdiagnosed as a wart for years or decades until it develops an invasive nodule with erosion and ulceration, finally bone invasion. Metastases are very rare. Most subungual squamous cell carcinomas are bowenoid and positive for high-risk human papillomavirus DNA. The non-HPV associated subungual carcinoma is rare. Treatment of choice is complete excision with margin control.

Finally, nail apparatus melanoma is the most serious nail condition. It makes up for 1 – 2.5% of all melanomas in light-skinned Caucasians and over 20% of all melanomas in Asians and Africans. Considering the small surface of all nails taken together, nail melanoma is not rare. However, delayed diagnosis is quite common and large series of nail melanoma patients exhibited tumor thicknesses of more than 4 mm. This is the reason for the poor prognosis of nail melanomas. Depending on the skin type and age, any recently acquired longitudinal melanonychia in a fair-complexioned individual and any abrupt change of a brown streak in a dark-skinned person must be taken for a melanoma suspect until otherwise proven. Dermatoscopy may help to make the diagnosis, but histopathology is the diagnostic gold standard. It can be very challenging, particularly in the earliest stage. Treatment is by wide local excision with a 6 mm safety margin to the anatomical boundaries of the nail apparatus and 10 mm to the border of a Hutchinson sign. Amputation has not proven to improve the prognosis.

In summary, there are many new and important nail tumors to be known by the dermatologist.



3rd INDERCOS

National Dermatology & Cosmetology Congress with International Participants

14-17 MARCH, 2018
HILTON ISTANBUL BOSPHORUS HOTEL
ISTANBUL, TURKEY

ANATOMY OF THE NAIL UNIT AND THE NAIL BIOPSY

Eckart Haneke

The nail unit is a relatively complex structure on the dorsal aspect of the tip of the digits. It develops shortly after the digit anlage as a field dependent on the distal phalanx bone. At week 18, the nail is fully visible and only matures during the rest of the intrauterine time. Both before and during this period, a number of potential disturbing factors may be active and give rise to nail dysplasia.

The nail apparatus is an integral part of the tip of the digit. It consists of 4 epithelial components, such as nail matrix, nail bed, eponychium and hyponychium, and connective tissue including the dermis of matrix, nail bed and nail folds, the underlying bone, the distal interphalangeal joint with its tendons, aponeuroses, ligaments and the very rich vascular and nervous supply. This is indispensable for the function of the nail unit as a protective structure, as a versatile tool, and not the least, as an important aesthetic structure.

The nail plate, which is commonly understood when the lay public speaks about the "nail", is produced by the matrix only and kept tightly attached to the underlying structures by the nail bed. From this it follows that for a normal nail both a functioning matrix plus nail bed are necessary. The nail plate surface is produced by the acral matrix whereas the mid-matrix produces the bulk of the nail thickness. Nail surface alterations derive from the acral matrix. Nail bed changes are seen under the nail and have no direct influence on the nail plate. The proximal nail fold protects the underlying matrix. It forms the cuticle, the most important sealing structure for the nail pocket. This is comparable to the hyponychium, which is specialized to permit the physiologic separation of the nail from the nail bed.

The gold standard of diagnosis is histopathology. It requires an adequate and sufficient biopsy from the right place. Several techniques are available.

Nail clippings are excellent for the diagnosis of onychomycosis and often can rule out or confirm nail psoriasis.

A punch may be good for the nail bed, but the nail plate has to be softened before with a 10 min warm bath. The punch can be 4 mm in the nail bed or 3 mm in the matrix. No suture is necessary.

A fusiform biopsy is ideal for nail bed and matrix lesions; however, it has to be oriented longitudinally in the nail bed and transversely in the matrix.

A lateral longitudinal nail biopsy is ideal for laterally located nail lesions. It contains the proximal nail fold, matrix, nail bed and hyponychium and allows all diagnoses to be made and gives information on the time course of the lesions.

For superficial matrix and nail bed lesions, a tangential matrix and bed biopsy is ideal, as it does not leave a post-biopsy nail dystrophy. This technique is therapeutic for superficial and in situ lesions.

3rd INDERCOS

National Dermatology & Cosmetology Congress with International Participants

14-17 MARCH, 2018
HILTON ISTANBUL BOSPHORUS HOTEL
ISTANBUL, TURKEY



INTERMITTENT OR PULSE TREATMENTS IN DERMATOLOGY

Betül Şerefican

Intermittent or pulse therapies are included in the alternative treatment modalities in dermatology. Particularly for drugs intended for long term treatment, situations such as cumulative toxicity, cost effectiveness, benefit to risk ratio reveal intermittent application protocols. Pulse therapy is the administration of suprapharmacologic doses of drugs in an intermittent manner. This type of therapy is suitable to achieve rapid antiinflammatory and immunosuppressive effect and arrest progression of severe diseases in dermatology.

Intermittent treatment with isotretinoin: Different treatment protocols were used in intermittent therapy when treating mild to moderate acne. However, in the European guideline for the treatment of acne which was published in 2016 there is no suggestion about intermittent usage.

Intermittent treatment of onychomycosis: As both terbinafine and itraconazole persist in the nail for a considerable period after elimination from the plasma, intermittent or pulse treatment regimens have been developed.

Intermittent terbinafine in the treatment of onychomycosis: 3-4 pulses (500 mg/day 1 week on/3 week off). Continuous terbinafine is generally more effective than intermittent regimen for mycological cure. However, both are equally effective for complete clinical cure.

Itraconazole pulse therapy for the treatment of onychomycosis: 400 mg per day for 1 week per month (fingernail-toenail onychomycosis: two-three pulses). Itraconazole pulse therapy is effective and safe in the treatment of tinea pedis/manuum, tinea corporis/cruris, and onychomycosis.

Intermittent cyclosporin therapy in psoriasis aims to overcome the side-effects of cyclosporin such as nephrotoxicity, so intermittent cyclosporin courses were used with high efficacy and improved benefit-to-risk ratio.

Intermittent Treatment in biologic therapy: Generally, the continuous regimen of biologics has greater efficacy and higher level of safety compared to an intermittent regimen.

Pulse steroid therapy is a method of administering high doses of steroids in short-term infusions. Using this method, methylprednisolone is usually given intravenously in doses of 0,5–1 g over a 2 hours period daily for 1–5 days. Arrhythmias and rare cases of sudden death are possible if rapid administration results in acute electrolyte shifts. Pulse steroid therapy has been used to treat disorders such as Behçet disease, alopecia areata, vitiligo, pemphigus, localized scleroderma and dermatomyositis.

As a steroid-sparing adjunct for the treatment of autoimmune skin diseases, cyclophosphamide is administered orally or intravenously, usually alongside oral prednisolone, with an aim of inducing remission. Intravenous cyclophosphamide pulse therapy typically involves doses of 500 mg or 10-15 mg/kg at 3–4 week intervals. It has been used for Behçet disease, pemphigus, subacute cutaneous lupus erythematosus, stevens-johnson syndrome, toxic epidermal necrolysis, pyoderma gangrenosum, dermatomyositis, relapsing polychondritis, wegener granulomatosis, generalised eruptive keratoacanthoma, multicentric reticulohistiocytosis and chronic urticaria.



3rd INDERCOS

National Dermatology & Cosmetology Congress with International Participants

14-17 MARCH, 2018
HILTON ISTANBUL BOSPHORUS HOTEL
ISTANBUL, TURKEY

SCLEROMYXOEDEMA AND SCLEREDEMA TREATMENTS

Laura Atzori

Scleromyxedema and scleredema are very rare conditions characterized by excessive production of mucin deposits in the skin and subcutaneous tissue, which causes skin hardening. The skin and subcutaneous deposits hamper the movement of limbs, thorax as well as facial mimics. Potential involvement of the internal organs, especially the heart, lungs, esophagus, central nervous system causes a very unpredictable course, with a guarded prognosis. Both diseases are typically associated with monoclonal gammopathy, while diabetes is characteristic only of scleredema. Empirical treatment with intravenous immunoglobulins at high dosage, of 2 g/per 1 kg of weight has proven efficacy and safety in several open clinical trials, with significant improvement of skin symptoms. The response is not permanent and maintenance infusions are required. Several cases are presented along with recent European recommendations.

3rd INDERCOS

National Dermatology & Cosmetology Congress with International Participants

14-17 MARCH, 2018
HILTON ISTANBUL BOSPHORUS HOTEL
ISTANBUL, TURKEY



APREMILAST: REVIEW IN DERMATOLOGY

Leon Kircik

Apremilast Lecture

We will discuss the role of apremilast treatment in psoriasis as well as mechanism of action, its efficacy and safety profile



3rd INDERCOS

National Dermatology & Cosmetology Congress with International Participants

14-17 MARCH, 2018
HILTON ISTANBUL BOSPHORUS HOTEL
ISTANBUL, TURKEY

TOPICAL TREATMENTS FOR SKIN CANCERS

Nagihan Sahillioğlu

Since the introduction of 5-fluorouracil in the 1960s, a number of topical drugs have been used for the treatment of skin tumors. Some of these topical drugs have been approved by the US Food and Drug Administration for selected indications; others are used off-label or are under investigation.

5-Fluorouracil acts as an antimetabolite, interfering with DNA synthesis. Topical 0.5%, 1%, 2%, and 5% 5-fluorouracil are approved by the US Food and Drug Administration for the treatment of actinic keratoses. The 5% formulation is also approved by the US Food and Drug Administration for the treatment of superficial basal cell carcinomas. The most common local skin reactions observed during treatment with 5-fluorouracil include erythema, blistering, necrosis, and erosions, accompanied by pruritus and burning.

Imiquimod is a synthetic immune response modifier. Imiquimod 5%, 3.75%, and 2.5% cream are approved by the US Food and Drug Administration for face and scalp actinic keratoses. Imiquimod 5% is also approved by the US Food and Drug Administration for the treatment of superficial basal cell carcinomas. Patients treated with imiquimod may experience moderate to severe local skin reactions, occasionally extending beyond the application site, including pruritus, burning, erythema, vesicles, erosions, exudation, and crusting. The development of such inflammatory reaction is a good predictor of therapeutic efficacy.

Diclofenac acts by downregulating cyclooxygenase enzymes and increasing apoptosis. A unique topical formulation containing diclofenac 3% gel in 2.5% hyaluronic acid is approved by the US Food and Drug Administration for the treatment of actinic keratoses. Diclofenac 3% gel in 2.5% hyaluronic acid is considered a well-tolerated treatment, with mild irritant side effects at application sites.

Ingenol mebutate has a dual mechanism of action: the induction of rapid cellular death (within a few hours) followed by an inflammatory response (within days). Two formulations of ingenol mebutate are available and approved by the US Food and Drug Administration for the treatment of actinic keratoses: a 0.015% gel for the face and scalp lesions once daily for 3 days and a 0.05% gel for the trunk and extremities once daily for 2 days. The most common local skin reactions related to the use of ingenol mebutate include erythema, flaking/scaling, and crusting.

Topical therapies may have particular advantages over surgical techniques in selected populations, including patients with multiple diffuse lesions and subclinical disease and in anatomic locations where surgical management would result in functional or cosmetic deficiencies or poor healing.

3rd INDERCOS

National Dermatology & Cosmetology Congress with International Participants

14-17 MARCH, 2018
HILTON ISTANBUL BOSPHORUS HOTEL
ISTANBUL, TURKEY



ANDROPAUSE, SOMATOPAUSE, HORMONAL REGULATION OF AGING AND ANTI-AGING HORMONE REPLACEMENT

Berna Aksoy

As long as people continue to resist normal aging process and prolongation of life span with time, there will be interest in maintaining a younger appearance and function. One of the most important health care needs is also reported to be successful aging with less frailty and dependency.

With aging the secretion of many hormones decreases, the impact of which is also augmented by a reduction in the sensitivity of tissues to their action, and additionally normal circadian rhythms are lost. Most endocrine axes manifest these changes with clinically identifiable losses of function such as those seen in the aging of the reproductive system (menopause and andropause), the growth axis (somatopause) and axes involving the adrenal gland (adrenopause). The clinical sequelae of these changes are variable and include reductions in bone, skin and skeletal muscle mass and strength, increases in adipose tissue, derangement of insulin signalling and effects on immune system function. Skin aging along with decreases in lean body mass, bone mineral density, sexual desire and erectile function, intellectual activity and mood have all been related to this hormonal decline with aging.

Hormones and hormone precursors have been investigated to delay the onset or progression of age associated changes in body composition, physical and cognitive function for the aim to be used as antiaging treatments. Among them dehydroepiandrosterone and growth hormone have been investigated in various studies. However most studies have included small sample sizes, followed for short durations and investigated various dosages ending with the mixed results. Sex hormones were also studied extensively for antiaging purposes. Testosterone has been shown to be effective only in older men with symptomatic hypogonadism with declined physiologic function. Efficacy of supplementation of these hormones in the healthy, non-symptomatic older people remains relatively unclear with little evidence of benefit and also presence of evidence of harms. Older adults with true hormone deficiencies that adversely affect their function to the degree that their daily functions compromised are appropriate candidates for the hormone replacement treatment. The lack of clinical studies evaluating efficacy, risks and long term effects and proven risks of hormone replacement in healthy older adults limits their routine use in clinical practice for antiaging indications. It is also recognised that endocrine adaptation during earlier life, physical exercise, calorie and especially glucose restriction may affect longevity and health in older age.



3rd INDERCOS

National Dermatology & Cosmetology Congress with International Participants

14-17 MARCH, 2018
HILTON ISTANBUL BOSPHORUS HOTEL
ISTANBUL, TURKEY

MEDICAL AND COSMETIC TREATMENT OF HAIR LOSS IN WOMEN

Ekrem Civaş

Hair loss in women is one of the most common benign dermatological conditions with cosmetic consequences that can cause psycho-social and psychiatric disorders. Unlike males, hair loss in women is an unexpected and unacceptable condition in all age groups. In recent years there has been major developments in distinguishing the causes and classification of women hair loss. As for the treatment options; medical treatment is limited such that it can only stop or slow down the advancement of hair loss.

Hair transplant is the only option that can somewhat regain back lost hair volume. Unfortunately only women with sufficient and strong donor with advanced stage FPHL are suitable candidates of hair transplant. Apart from that, non-medical hair systems, hair volume enhancing products, anti-breakage and scalp concealing products cosmetic products can be used to camouflage hair loss in women.

3rd INDERCOS

National Dermatology & Cosmetology Congress with International Participants

14-17 MARCH, 2018
HILTON ISTANBUL BOSPHORUS HOTEL
ISTANBUL, TURKEY



RATIONAL USE OF MEDICINES “EVIDENCE-BASED ANTIBIOTIC USES IN DERMATOLOGY”

Gülden ERSÖZ

No More Antibiotics for Acne!

At the outset of the 20th century, infection was the primary cause of worldwide mortality and the concept of antibiotic therapy was essentially wishful thinking. Today, in dermatology, prolonged antibiotic use in the management of acne has become a common standard of care. In the milieu of antibiotic resistance as a public health menace, is it possible that dermatologists should temper their reliance on such agents and consciously step away from antibiotic use in favor of other acne treatment modalities? Exactly the answer is “yes”.

Four main contributors to the development of bacterial antibiotic resistance:

- *The pharmaceutical industry,
- *The agriculture and animal husbandry industry,
- *Patients,
- *Healthcare providers.

Due to the rise in antibiotic resistance, new drugs must be developed to treat highly virulent pathogens; however, the number of new antibacterial drugs receiving US FDA approval has dramatically decreased in last decade.

The history of antibiotic discovery and concomitant development of antibiotic resistance; (1) The dark ages, it is named as the pre-antibiotic era and there were not any antibiotic discovery; (2) primordial, the advent of chemotherapy, via the sulfonamides; (3) golden, the halcyon years when most of the antibiotics used today were discovered; (4) the lean years, the low point of new antibiotic discovery and development; pharmacologic, attempts were made to understand and improve the use of antibiotics by dosing, administration, etc.; (5) biochemical, knowledge of the biochemical actions of antibiotics and resistance mechanisms led to chemical modification studies to avoid resistance; (6) target, mode-of-action and genetic studies led to efforts to design new compounds; genomic/HTS, genome sequencing methodology was used to predict essential targets for incorporation into high-throughput screening assays; (7) end of the story, disenchantment and extreme resistance; with the failure of the enormous investment in genome-based methods, many companies discontinued their discovery programs.

Other milestones in this history include the creation of the FDA Office of New Drugs after the thalidomide disaster led to stricter requirements for drug safety, including the use of antibiotics. This slowed the registration of novel compounds. Before antibiotics were discovered, Semmelweis advocated hand washing as a way of avoiding infection; this practice is now strongly recommended as an effective method for infection control preventions.

Do dermatologists contribute to overuse of antibiotics?



3rd INDERCOS

National Dermatology & Cosmetology Congress with International Participants

14-17 MARCH, 2018
HILTON ISTANBUL BOSPHORUS HOTEL
ISTANBUL, TURKEY

According to some experts, Dermatologists generally know that the sensitivity of many pathogens to the antibiotics used to treat them is decreasing. But many dermatologists may not appreciate their specialty's role in potentially fueling the problem. There is a changing of pathogens' sensitivity to antibiotics, and that is a global public health issue. Generally rather than "antibiotic resistance" infectious diseases professionals prefer the term "change in antibiotic sensitivity". Because clinical outcomes of the resistance more important than laboratory findings. It is certain that decreases antibiotic sensitivity of the pathogen microorganisms.

According to a World Health Organization (WHO), antimicrobial resistance impacts patients with infections ranging from HIV to *Staphylococcus aureus*. Resistant infections increase the length and cost of treatment, and cause high morbidity and mortality. Versus nonresistant infections, resistant infections are 2-3 times as likely to kill. Some studies show that resistant *Propionibacterium acne* is likely to fail treatment, although research has not yet established how much is the rates. Some authors of the dermatology world, says that "We must maintain the activity of antibiotics, more specifically, we must know the mechanisms of killing the bacteria and be aware the dangers of the development of the resistance.

There is another problem is topical antibiotics prescriptions. Based on antibiotic prescribing data from 2003, dermatologists account annually for 8-9 million prescriptions for oral antibiotics, and 3-4 million prescriptions for topical antibiotics. Overall, much of the emphasis on concerns related to emergence of clinically significant antibiotic-resistant bacterial strains focuses on use of systemic antibiotics, however, topical antibiotic use may also have potential implications. The potential therapeutic benefits and ecologic implications ("ecologic mischief") of topical antibiotic therapy for specific indications should be evaluated in ambulatory dermatology practice before each prescription. Especially, rifampin is an important example for easy developing resistance by *S. aureus*.

The strategy of the administration of antibiotics:

Patients with serious bacterial infections, the number of white cells are usually increased and even excel granulocytes.

Based on the clinical picture, laboratory tests can identify the anatomical location of the infection.

Patients who develop an infection during their hospital stay empiric antimicrobial therapy administration should take account of the sensitivity of the flora.

The remarkable ability of the microorganisms to adapt to any environment is that each new pathogenic is resistant to antibiotics administered in the previous period.

The older people metabolize and excrete antibiotics at a slower pace. Therefore, there should be longer intervals between the doses of antibiotics. At this age, drugs with greater toxicity, such as aminoglycosides (nephrotoxicity and ototoxicity) should be avoided.

Too many antibiotics together may act synergistically rather than competitively. The majority of infections can be treated with an antibiotic. But there are cases where it is necessary to combine the administration of antibiotics. This is the case where a polymicrobial infection.

The use of many antibiotics results in more side effects. Adverse reactions to antibiotics are common and are divided into idiosyncratic, allergic and dose-dependent. Examples of serious allergic reactions are immediate hypersensitivity reaction to penicillin (laryngeal edema, circulatory collapse). When a patient

3rd INDERCOS

National Dermatology & Cosmetology Congress with International Participants

14-17 MARCH, 2018
HILTON ISTANBUL BOSPHORUS HOTEL
ISTANBUL, TURKEY



taking many antibiotics had an allergic reaction, then all antibiotics are suspect and cannot reuse.

The use of many antibiotics increases the risk of infection with resistant microorganisms. When many antibiotics are administered to a patient, the spectrum of microorganisms killed is increased. The destruction of the flora of the oropharynx and gastrointestinal tract are harmful to humans. The microorganisms that are normally found in these regions are competing to develop more resistant microorganisms. The elimination of the normal flora of the indiscriminate use of antibiotics has resulted in the development of multi-resistant pathogenic microorganisms.

Patients should be informed about antibiotics and their treatment:

Make people take antibiotics on their own initiative or at the instigation of others or primarily. The prescription of antibiotics is not necessary in every condition. If the doctor does not prescribe antibiotics do not deny. The antibiotics to viral infection do not reduce the duration of symptoms or protect people around you to be none afflicted. When assumed by the doctor that it is necessary to administer antibiotics, they should be strictly adhered to dosage instructions and duration of the treatment. Follow the physician's instructions carefully.

Epilogue; No More Antibiotics for Acne!

Alternatives to Antibiotic Treatment

- Treating acne aside from topical monotherapy with benzoyl peroxide
- High intensity light
- Photodynamic therapy
- Thermo therapy
- Hormonal therapy with oral contraceptive pills or spironolactone
- Sub-antimicrobial doses of doxycycline which exploit the non-antimicrobial, anti-inflammatory properties of the antibiotic
- Dapsone
- Isotretinoin
- Zinc plus or minus nicotinamide
- Topical bleach

Conclusion

Antibiotic resistance is a serious matter of concern for the clinician, including the practicing dermatologist. As current and new agents continue to be utilized, the rate of resistance will continue to increase. The best methods for diminishing risk of antibiotic resistance include a careful history and physical, diagnostic laboratory and culture studies, close monitoring of clinical response, appropriate directed-therapy when the causative organism is identified, appropriate empiric treatment based on local antimicrobial susceptibilities within the community, and continuing therapy for the appropriate duration. All of these precautions, as well as discontinuing of antibiotics when deemed unnecessary, will aid to reduce the ever-growing rate of antibiotic resistance. There is no single template for a program to optimize antibiotic prescribing in infection treatment. The complexity of medical decision making surrounding antibiotic use; some times require flexibility in implementation, but the experience demonstrates; antibiotic stewardship programs can be implemented effectively in a widely to protect from resistance of the microorganisms. That success is dependent on multidisciplinary approach.



3rd INDERCOS

National Dermatology & Cosmetology Congress with International Participants

14-17 MARCH, 2018
HILTON ISTANBUL BOSPHORUS HOTEL
ISTANBUL, TURKEY

Reference

1. Laxminarayan R, Matsoso P, Pant S, et al. Access to effective antimicrobials: a worldwide challenge. *Lancet* 2016;387:168–75.
2. Van Boeckel TP, Gandra S, Ashok A, et al. Global antibiotic consumption 2000 to 2010: an analysis of national pharmaceutical sales data. *Lancet Infect Dis* 2014;14:742–50
3. Muhammad M, Rosen T. A controversial proposal: no more antibiotics for acne! *Skin Therapy Lett.* 2013;18(5):1-4
4. Chon SY, Doan HQ, Mays RM, et al. Antibiotic overuse and resistance in dermatology. *Dermatol Ther.* 2012;25(1):55-69
5. Perera G, Hay R. A guide to antibiotic resistance in bacterial skin infections. *J Eur Acad Dermatol Venereol.* 2005;19(5):531-45
6. Del Rosso JQ, Kim GK. Topical antibiotics: therapeutic value or ecologic mischief? *Dermatol Ther.* 2009;22(5):398-406

3rd INDERCOS

National Dermatology & Cosmetology Congress with International Participants

14-17 MARCH, 2018
HILTON ISTANBUL BOSPHORUS HOTEL
ISTANBUL, TURKEY



MICRO - RNA's IN DERMATOLOGY

Özgür Timurkaynak

Micro-Ribonucleic acids (miRNAs) belong to a class of short endogenous non-coding RNAs with an average length of 22 nucleotides. They regulate various cell functions by binding to target mRNAs, resulting in mRNA degradation and inhibition of translation, thus having the ability to control gene expression.

Human genome contains more than 2500 miRNAs and their first regulatory role in cancer has been discovered nearly three decades ago. Each miRNA can repress hundreds of genes. Since then, the impact of these molecules on cell growth, differentiation, apoptosis and immune response have been supported by growing number of reports on human cancer, cardiovascular disease, Hepatitis C virus infections and several skin disorders.

Numerous ongoing investigations on miRNAs in skin cancer such as melanoma, basal and squamous cell carcinoma, Kaposi's Sarcoma, cutaneous T-cell lymphoma and Merkel cell carcinoma are present. Together with lichen planus, allergic contact dermatitis and hidradenitis suppurativa; psoriasis vulgaris and atopic dermatitis are the most common inflammatory skin disorders that have been evaluated. Micro RNA profile alterations have also been shown in several other skin disorders such as vitiligo, dermatomyositis, scleroderma, wound healing, drug reactions, Hailey-Hailey disease, neurofibromatosis and hair loss disorders.

According to the present data, miRNAs can be readily used as biomarkers for disease, monitoring of treatment efficacy and even a promising target for treatment. Skin diseases will serve as an attractive model for further studies, especially with the successful development of safe and efficient delivery systems.



3rd INDERCOS

National Dermatology & Cosmetology Congress with International Participants

14-17 MARCH, 2018
HILTON ISTANBUL BOSPHORUS HOTEL
ISTANBUL, TURKEY

HHV-6, 7 AND 8 IN DERMATOLOGY

Nazan Emiroglu

Human herpesviruses (HHVs) have frequently been discussed as etiologic agents in cutaneous disease but clearly defined associations are rare. Investigations into an etiologic association between HHVs (HHV-6, HHV-7, HHV-8(KSHV)) and cutaneous disease are complex because of the ubiquity and nearly universal prevalence of some herpesviruses.

HHV-6 and HHV-7 are closely related b-herpesviruses that have been linked with roseola, pityriasis rosea, severe drug eruptions(drug-induced hypersensitivity syndrome (DIHS), drug reaction with eosinophilia and systemic symptoms (DRESS)), lichen planus, post-transplant reactivation, and autoimmune connective tissue diseases.

Roseola infantum, also known as exanthem subitum or sixth disease, is a generally benign febrile exanthem of infancy. It has a characteristic clinical course of high fever followed by the appearance of an exanthem upon defervescence. Roseola is caused by infection with human herpesviruses 6 or 7 (HHV-6/7), which are acquired at a young age. Roseola has usually complete recovery with no significant sequelae. However, HHV-6/7 can reactivate immunocompromised individuals with severe systemic consequence.

Pityriasis rosea is an acute, self-healing exanthem characterized by oval erythematous-squamous lesions. Constitutional symptoms, which have the character of true prodromes; clinical features, which resemble those of the known exanthems; and many epidemiologic data all suggest an infectious origin. A host of infectious agents have been investigated, but, recently, human herpesvirus 6 and 7 have been extensively studied.

KSHV (Kaposi's sarcoma-associated herpesvirus, HHV-8) is a g-herpesvirus that is thought to be the etiologic agent of Kaposi's sarcoma. This virus was found to be a gamma herpesvirus, closely related to Epstein-Barr virus. HHV-8 DNA was found in almost all specimens of classic KS, endemic KS, and iatrogenic KS, as well as epidemic KS (ie, AIDS KS). It is now believed that HHV-8 is necessary, but not sufficient, to cause KS and that other factors such as immunosuppression play a major role.

This presentation summarizes the associations between cutaneous diseases and three new human herpesviruses, human herpesvirus (HHV)-6, HHV-7, and Kaposi's sarcoma-associated herpesvirus (KSHV).

3rd INDERCOS

National Dermatology & Cosmetology Congress with International Participants

14-17 MARCH, 2018
HILTON ISTANBUL BOSPHORUS HOTEL
ISTANBUL, TURKEY



THE APPLICATION OF CRISPR/CAS 9 AND GENOME EDITING IN INVESTIGATIVE DERMATOLOGY

Hans Christian Hennies

Studies in genetics and genomics have revealed the molecular basis of numerous genetic skin diseases in recent years. Treatment of monogenic and other skin diseases, however, is still often limited especially in the context of causative therapies and precision medicine. Genome editing is a promising approach to provide means for gene and mutation specific treatments for these diseases. Experimental therapies have been developed in particular for blistering diseases with the use of the CRISPR/Cas9 technology. The procedure can be used for RNA guided gene corrections through homologous recombination and for allele specific inactivation of dominant negative mutations with non-homologous end joining. These strategies can be combined with the use of induced pluripotent stem cells, which makes the approach even more flexible and applicable for more complex diseases involving a range of different cell types. Recent examples of using the technology for genetic skin diseases will be discussed.

NANOSCIENCE IN DERMATOLOGY

Hans Christian Hennies

Nanosystems, and in particular lipid nanoparticles, have gained more and more importance in dermatology and cosmetology over several years. While metal nanoparticles have a wide impact for the treatment of infections and the protection against harmful effects of sunlight, lipid nanoparticles and other nanostructured transporters have been developed as carriers for the topical application of substances that cannot efficiently pass the stratum corneum alone. These systems are suitable for packaging even larger and hydrophilic molecules and stabilisation of enzymes and other biologically active reagents. Advanced formulations have recently addressed the problem of targeted release of therapeutic substances and can be used for topical epidermal, dermal or transdermal deliveries. At the same time, they secure the advantages of topical treatment and several nanosystems have been shown to have a good safety profile that makes them promising candidates for clinical applications.



3rd INDERCOS

National Dermatology & Cosmetology Congress with International Participants

14-17 MARCH, 2018
HILTON ISTANBUL BOSPHORUS HOTEL
ISTANBUL, TURKEY

PRIMARY CUTANEOUS LYMPHOMAS: DIAGNOSIS AND TREATMENT

Małgorzata Sokołowska-Wojdyło

Primary cutaneous lymphomas are a group of rare lymphoproliferative disorders with not completely known pathogenesis. They comprise cutaneous T-cell lymphomas (CTCL), cutaneous B-cell lymphomas (CBCL) and T/NK-cell lymphomas. The aim of the presentation is to provide physicians with a tool to facilitate the diagnostic and therapeutic process in patients with this group of diseases, based on Polish, European and World recommendations. The dermatological recommendations should be consistent with the guidelines for haematologists and oncologists, what enable the unification of diagnostics and therapy – from topical glucocorticosteroids, through phototherapy, bexarotene, IFN α , methotrexate, clinical trials, chemotherapy and alloHSCT.

It is important to note that therapeutic decisions must be made individually on the basis of the general condition of the patient, history of internal diseases and medicines used, with careful consideration of the potential efficacy and safety profile of the proposed treatment, which may differ from patient to patient.

3rd INDERCOS

National Dermatology & Cosmetology Congress with International Participants

14-17 MARCH, 2018
HILTON ISTANBUL BOSPHORUS HOTEL
ISTANBUL, TURKEY



USE OF COMPLEMENTARY AND ALTERNATIVE MEDICINE IN MELANOMA PATIENTS

Aslı Aksu Çerman

- * Complementary and alternative medicine (CAM) is a widespread phenomenon among cancer patients.
- * In Western countries, from 40 to more than 90% of all cancer patients use CAM at some time of their disease.
- * Reasons to use CAM vary in the literature.
- * Many patients look for some opportunity to get involved in the treatment, to consciously do something for one's own well-being.
- * So far, there is no internationally accepted definition of CAM, but the National Center for CAM (NCCAM) simply defines it as a «group of diverse medical and health care interventions, practices, products, or disciplines that are not generally considered part of conventional medicine.»
- * According to NCCAM, CAM comprises natural products (e.g. supplements) as well as mind and body techniques (e.g. acupuncture, yoga, relaxation techniques).
- * Communication on CAM should become a regular topic in counselling melanoma patients
- * To increase safety, patients and physicians must have access to evidence-based information on these methods and their interactions with modern cancer treatments.
- * To protect melanoma patients from potential harm by the combination of their cancer treatment and CAM usage, patients should systematically be encourage to report their CAM use, while oncologist should be trained on evidence of CAM, and patient guidance for saver CAM use.



3rd INDERCOS

National Dermatology & Cosmetology Congress with International Participants

14-17 MARCH, 2018
HILTON ISTANBUL BOSPHORUS HOTEL
ISTANBUL, TURKEY

THERAPEUTIC STRATEGIES FOR ACTINIC KERATOSES – AN UPDATE

Aslı Aksu Çerman

Clinically, AKs typically present as scaly or keratotic patches, papules or plaques on an erythematous base. The diameter usually does not exceed 1 cm, although in some patients lesions can be numerous and confluent. Although the risk of progression to invasive SCC for a specific lesion may be low, it is widely regarded that 60% to 97% of SCCs originate from AKs.

Management;

A 5-step approach to managing AK has been proposed that includes:

- 1- Periodic dermatologic examinations,
- 2- Field-directed therapy,
- 3- Lesion-directed therapy,
- 4- Patient education with respect to both sun protection and the need for AK treatment,
- 5- Regular skin self-examinations.

Classification of patient subgroups for the treatment;

- 1- Single AK lesions

At least one and not more than five palpable or visible AK lesions per field or affected body region

- 2- Multiple AK lesions

At least six distinguishable AK lesions in one body region or field

- 3- Field cancerization

At least six AK lesions in one body region or field, and contiguous areas of chronic actinic sun damage and hyperkeratosis

- 4- Immunosuppressed patients with AK

Lesion-Directed Therapy

Lesion-directed therapies work by physically destroying the targeted lesion and should be considered for isolated or early lesions that are relatively few in number. This treatment options are cryosurgery, curettage with electrodesiccation and shave excision.

Field-Directed Therapy

Field-directed therapies are used to treat multiple AK lesions on contiguous areas of skin, including the sun-damaged area at risk of the development of AKs from subclinical lesions. Field-directed therapy includes both procedural ablative techniques and creams containing pharmacologic agents.

3rd INDERCOS

National Dermatology & Cosmetology Congress with International Participants

14-17 MARCH, 2018
HILTON ISTANBUL BOSPHORUS HOTEL
ISTANBUL, TURKEY



MISNOMERS IN DERMATOLOGY: AN UPDATE

Işın Sinem Bağcı

Description of the skin lesions is the mainstay of raising a diagnosis in the field of dermatology. Therefore, descriptive terminology has a crucial role in defining, differentiating, and classification of skin lesions. Besides its rich descriptive terminology, dermatological lexicon has also a number of misnomers which causes confusion not only for dermatologists but also for non-dermatologists physicians and patients. In addition, a discordance between the name of the disease and clinical picture, etiology or pathophysiology is also challenging for the trainees in dermatology. In this talk, some of the more commonly encountered misnomers will be reviewed and discussed.



3rd INDERCOS

National Dermatology & Cosmetology Congress with International Participants

14-17 MARCH, 2018
HILTON ISTANBUL BOSPHORUS HOTEL
ISTANBUL, TURKEY

PSEUDO-CONDITIONS IN DERMATOLOGY

Ezgi Özkur

Learning and recognizing true dermatological conditions prevent unnecessary investigations and treatments. The pseudo conditions are look alike conditions occurring in the same site but originate from different causes and not related to the original disease. Most of these pseudo-conditions were named due to some clinical or histopathological resemblance to the original disease. These conditions' range are very wide but well known pseudo conditions in dermatology are pseudo-lymphoma, pseudo Kaposi's sarcoma, pseudo-folliculitis, pseudo Hutchison's sign, Pseudoepitheliomatous hyperplasia, pseudo porphyria, pseudo Nikolsky's sign, Pseudopelade of Brocq etc. Pseudo conditions have been classified according to the major disease groups in dermatology.

3rd INDERCOS

National Dermatology & Cosmetology Congress with International Participants

14-17 MARCH, 2018
HILTON ISTANBUL BOSPHORUS HOTEL
ISTANBUL, TURKEY



INVERSE CONDITIONS IN DERMATOLOGY

Ayşe Serap Karadağ

Inverse conditions can occur in a wide variety of inverse areas of the body such as axillae, inguinal folds, perineum, inner aspect of the thighs, inframammary skin, under abdominal folds, behind the ears, web spaces between the toes and fingers, creases of the neck and chin, and the eyelids.

There are many conditions may affect intertriginous areas. In this speech, inverse conditions will be divided six different headings, and many subheadings.

1. Dermatoses: Intertrigo, diaper dermatitis, psoriasis inversa, seborrheic dermatitis, lichen planus pigmentosus inversus, pemphigus vegetans, and pemphigoid vegetans.
2. Infections: Bacterial (streptococcal intertrigo, erythrasma, gram (-) intertrigo), fungal (candidal, tinea cruris, interdigital tinea pedis, erosio digitalis blastomycetica)
3. Genetic diseases (Darier, Hailey-Hailey, Dowling-Degos, Gali-Gali disease)
4. Drugs related (Baboon syndrome, SDRIFE, Chemotherapeutic induced toxic erythema)
5. Nutritional dermatoses (Acrodermatitis enteropathica, biotin deficiency, riboflavin deficiency, pyridoxine deficiency)
6. Others (Hidradenitis suppurativa, acanthosis nigricans, bromhydrosis, chromhydrosis, hyperhydrosis, necrolytic migratory erythema, intertriginous MF, Letterer-Siwe disease).

The important point is the differential diagnosis for some similar conditions. Diaper dermatitis is a common disease which is a type of intertriginous dermatitis. Seborrheic dermatitis, atopic dermatitis, inverse psoriasis, and Langerhans cell histiocytosis can be confused with diaper dermatitis. Similarly the differentiation of interdigital T.pedis, erythrasma, candida, and gram negative intertrigo is occasionally hard. The clinician have to catch up some clues for disease; such as satellite pustules for candida, yellow crust for seborrheic dermatitis, well demarcated active border for dermatophyte infection, and green pigmentation for pseudomal infections. Bacterial culture, KOH examination, wood lamb, punch biopsy, etc are helpful techniques for differential diagnoses. Skin biopsies are sometimes needed, culture and sensitivities may be obtained if a secondary infection is suspected. Clinical response and prognosis are different patient to patient.



3rd INDERCOS

National Dermatology & Cosmetology Congress with International Participants

14-17 MARCH, 2018
HILTON ISTANBUL BOSPHORUS HOTEL
ISTANBUL, TURKEY

EVERY DERMATOLOGY CONSULTATION: THINK ADHERENCE

Andrew Finlay

We are all swimming in a sea of non-adherence. Understanding adherence is essential for all clinicians. Non-adherence results in lack of treatment effectiveness, longer time to improvement, prolonged burden of disease, wasted clinic appointments and clinicians getting false impressions of the impact of their therapy advice. Non-adherence is so common it is almost normal. There are some groups of patients in whom the risk of non-adherence is even higher.

Methods to assess adherence include the "Yesterday Use" question, formal questionnaires and "smart" ointment or tablet containers. Once you are aware of the constant likelihood of non-compliance, there are several ways to improve adherence, including making treatment regimens as simple as possible, practical patient therapy teaching, involving partners or other family members, text reminders and use of communication techniques such as the Finger Tip Unit.

So in every clinic, Think Adherence and be proactive in high risk patients.

Reference

Finlay AY. Every dermatology consultation: think adherence. Br J Dermatol 2017; 176(3): 558-559.

3rd INDERCOS

National Dermatology & Cosmetology Congress with International Participants

14-17 MARCH, 2018
HILTON ISTANBUL BOSPHORUS HOTEL
ISTANBUL, TURKEY



SKIN TESTS IN DERMATOLOGY

Ragıp Ertas

Skin tests are widely used to support the diagnosis of dermatological diseases. They are mainly indicated for the detection of; 1-Immediate (Type I hypersensitivity), 2-Delayed type hypersensitivity (DTH, Type IV hypersensitivity) towards exogenous or endogenous antigens. Induration and its size is more important than erythema while interpreting Type IV hypersensitivity.

Tuberculin test (Mantoux method); Disease: Tuberculosis, Type IV, Antigen: Tuberculin, one tuberculin unit is injected intradermal on the flexor aspect of the forearm and reading taken after 48h.

Lepromin test; Disease: Leprosy (This test is not a diagnostic test) helpful in classification of disease. Antigens: Mitsuda lepromin (Lepromin A); and Dharmendra lepromin, Biphasic reaction; Fernandez reaction (48-72h) and Mitsuda reaction (3-4 weeks).

Frei test; Lymphogranuloma venereum (all chlamydial species, not specific to *C. trachomatis* /LGV) Frei's test becomes positive 2-8 weeks after infection.

Foshay test; Cat-scratch disease (*Bartonella henselae*); A positive test is a sign of past or present infection. The test has an historical importance.

Anthraxin test; Anthrax (*B. anthracis*); The anthraxin skin test becomes positive in most of the cases in the first three days of the disease, and stays positive for a long time after recovery from the disease.

Dick's test; Scarlet fever (*Streptococcus pyogenes*); The reaction is considered positive when there is an erythema more than 5mm in diameter and strongly positive if induration also develops.

Trichophyton test; Performed to detect allergic hypersensitivity towards dermatophytes.

Candidin test; Hypersensitivity to *Candida albicans* is universal. It is not a diagnostic test for the infection. The candidin test serves as an aid to evaluate the cellular immune response in patients suspected of having reduced immune system.

Coccidioidin test; Antigens: acoccidioidin and spherulin. *Coccidioides immitis*.

Histoplasmin test; is used for epidemiological studies, such as investigations of case cluster or the definition of endemic areas but is not predictive of histoplasmosis.



3rd Indercos

National Dermatology & Cosmetology Congress with International Participants

14-17 MARCH, 2018
HILTON ISTANBUL BOSPHORUS HOTEL
ISTANBUL, TURKEY

Leishmanin test (Montenegro test); A positive reaction consists of a palpable nodule more than 5mm in diameter developing in 48 to 72h and indicates DTH, but not necessarily immunity, to leishmania organisms.

Intradermal tests in various skin or systemic infections thus serve an important role in reaching a diagnosis and predicting the prognosis of these conditions. Intradermal sensitivity test used for detecting the drug hypersensitivity (drug-specific IgE antibodies). It is commonly performed for penicillin, general and local anesthetic agents, tetanus toxoid, iodinated radiocontrast media, insulin, heterologous sera...

Autologous serum skin test (ASST); About 25-45% of patients of CSU have autoantibodies against the high affinity IgE receptor FcεRI or IgE that are capable of histamine release.

Kveim-Siltzbach test; It is a valuable intradermal test for the diagnosis of sarcoidosis.

Pathergy test is a nonspecific, cutaneous hypersensitive response, which is characterized by formation of erythematous in duration at the site of trauma with a papule or sterile pustule formation at its centre, 24-48 hours after 20-26G sterile needle stick in Behçet's Disease.

Oral Pathergy test; Pathergy can also be applied to mucosa of the lower lip.

Autoerythrocyte sensitization test; the intradermal test for the diagnosis of autoerythrocyte sensitization syndrome.

Patch test: Allergic contact dermatitis (ACD) is a type IV hypersensitivity reaction which develops against substances contacting the skin.

Photopatch testing; when photoallergic contact dermatitis is suspected, photopatch testing may be carried out. The recommended method of photopatch testing involves the application of a photoallergen series, and any suspected patient materials, in duplicate, on either side of the upper back.

Also, other skin tests such as repeated open application test, Usage test...etc. was briefly mentioned.

3rd INDERCOS

National Dermatology & Cosmetology Congress with International Participants

14-17 MARCH, 2018
HILTON ISTANBUL BOSPHORUS HOTEL
ISTANBUL, TURKEY



DIAGNOSIS AND MANAGEMENT OF ADVERSE FILLER EFFECTS

Eckart Haneke

Filler injections belong to the most frequently performed beautifying procedures in cosmetic medicine. Adverse side effects are a catastrophe for the affected person and everything possible must be done to avoid them. This starts with a careful and thorough patient history concerning previous injections, allergies, immune reactions and diseases, drug treatments, particularly those with an immunomodulatory potential, and chronic infections as well as a family history as to serious diseases, so-called collagenoses, immune defects, genetic disorders and others.

Filler adverse effects are classified according to their time course and due to user dependent, filler and host factors. Technical errors concern too much or too little volume, incorrect depth of filler placement, wrong location, and inappropriate product choice.

The physician must be experienced to avoid gross mistakes concerning the site of injection, the volume, the speed, the depth, and the post-injection treatment. The physician should be available after the injection and never dismiss a patient's concerns. The nature of complication is checked and can be classified into light and disappearing by itself, moderate and requiring treatment, or severe necessitating immediate intervention. Treating a patient with empathy has avoided many lawsuits.

Concerning the fillers, it is the substance on one hand and its chemistry, purity, homogeneity, particle size, shape and roughness, its electrical charge, its ability to biointegration and to react with other substances including other fillers, that matter. It has also to be kept in mind that a filler result that is desirable at the age of 20 might look odd at age 50 or 60. And finally, the host and his or her immune system are of paramount importance. This can change during the life of a filler and have a great impact on its tolerability.

Fillers are divided into reversible (early or temporary: collagens and hyaluronic acid, late or long-term: HA with dextranomer beads, poly-L-lactic acid and calcium hydroxylapatite), and irreversible (delayed or permanent ones: paraffin, silicon preparations, polymethylmethacrylate microspheres, hydroxyethylmethacrylate fragments, polyacrylamide hydrogel, polyalkylimide gel, polyvinylhydroxide microspheres in polyacrylamide gel, and many more). In general, their adverse effects last as long as their intended ones. Although it is often thought that temporary fillers are better tolerated than permanent ones this is apparently not true as the frequency of short-term adverse reactions is very similar. Whatever substance is injected into the tissue it is perceived as a foreign substance with an initial challenge to the host's immune system.

Early complications develop within less than two weeks and include erythema, edema, and allergy. Bumps and lumps following superficial injection are usually visible immediately after the injection or shortly thereafter. Necrosis due to intra-arterial injection becomes obvious within a day.

Late complications are chronic inflammation, late allergic reactions, nodules (granulomas) and filler migration, hypertrophic scar and telangiectasia.

Delayed complications are considered to be largely due to biofilm formation.

Often, adverse effects develop weeks, months or even years after the injection, and the patients frequently do not remember which filler they had gotten. The problem may even be confounded by the fact that different fillers may have been injected at various times by different physicians and even sometimes by non-physicians.



3rd INDERCOS

National Dermatology & Cosmetology Congress with International Participants

14-17 MARCH, 2018
HILTON ISTANBUL BOSPHORUS HOTEL
ISTANBUL, TURKEY

CARBOXYTHERAPY – NON-INVASIVE METHOD IN DERMATOLOGY, AESTHETIC DERMATOLOGY AND SOME OTHER BRANCHES OF MEDICINE

Hana Zelenkova

Carboxytherapy - medicinal administration of CO₂ injections - has developed substantially in the past 20 years both in theory and in practice. Some refuse it, some remain indecisive, and some consider it an extraordinarily popular method usable in various branches of medicine. Has been applied in rehabilitation medicine and physiotherapy for years. In other branches of medicine, this method, which is both safe and comfortable for the patient, had to go through substantial development, verified by many valid trials carried out by renowned centres around. The regulation of the gas exchange of CO₂ and O₂ is ensured by the synchronization of several processes, and therefore the numerous effects of carboxytherapy involve humoral, biochemical, and tissue mechanisms. The devices used in carboxytherapy of course had to pass through this development and on the market there are multiple variants, ranging from the so called "pens" to sophisticated devices featuring displays with detailed information. In general, they differ based on the projected and desired treatment result and depend on the erudition of the expert administering carboxytherapy to skin, subcutaneous tissue, muscles, joints, and spinal area. The technique used to administer CO₂ abides by certain rules. There are two types of administration. Each of them has its advocates and opponents. Many centres use devices adjusted according to purpose. The gas applied either way will spread in adjacent tissues, the variable being the administration time. Continuous administration and bolus administration of CO₂. Continuous administration is a technique of gradual administration of a predefined amount of CO₂ in certain localities (intradermal administration), under the skin (subdermal administration) and into deeper structures (sub cutis, fatty tissue, muscles in physiotherapy and neurology, fibrous tissue in keloid scars or in *Morbus Peyronie*, etc.). Continuous administration is preferred by some experts also when treating the face, neck, and décolletage. The disadvantage is the longer injection interval and the risk of unwanted movement of the inserted needle (especially with pens, which may be small but quite heavy and come with a small cartridge placed in the handle). The amount of CO₂ gradually fills in the treated areas. Bolus administration of CO₂ is the administration of certain predefined bolus doses of CO₂ into predefined localities. The session takes less time and is more comfortable for the patient, especially when treating more extensive or sensitive localities. In aesthetic dermatology this method may be applied as a rejuvenation and regenerating modality. Is employed mainly due to its classic vasodilatation effect and its capacity to foster intradermal collagen restructuring. In classic dermatology it is used to treat patients with poor healing lower leg ulcers, in diabetic patients and in patients with poor healing surgical wounds and others dermatosis.

Conclusions: Carboxytherapy In the last years has become the centre of attention as a unique method applicable in dermatology, aesthetic dermatology and anti-aging medicine and other branches medicine.

3rd INDERCOS

National Dermatology & Cosmetology Congress with International Participants

14-17 MARCH, 2018
HILTON ISTANBUL BOSPHORUS HOTEL
ISTANBUL, TURKEY



HAIR COSMETICS, HAIR IN FORENSIC MEDICINE

Esra Kural

Hair cosmetics can be divided into two main groups:

1. Cosmetics that produce only temporary changes to the hair; such as shampoos, conditioners, hair sprays, and temporary dyes.
2. Cosmetics that produce a permanent change to the hair; such as permanent waves, relaxers, bleach and permanent dyes.

Shampoos & Conditioners: It is important to realize that the only ingredients that are important for the cleansing and the manageability of the hairs are the synthetic detergents and the conditioners. A detergent or surfactant is amphiphilic, meaning the detergent molecules contain both lipophilic (oil-attracting) and hydrophilic (water-attracting) sites. Surfactants are classified according to hydrophilic polar group as anionic, cationic, amphoteric and nonionic. Shampoos should not have a pH higher than 5.5 because alkaline pH, causes hair-shaft swelling. This swelling loosens the protective cuticle and it predisposes the hair shaft to damage. Hair-shaft swelling can be prevented by "pH-balanced" shampoos formulated with the addition of an acidic substance, as citric and lactic acid.

Conditioning agents have positive charges. Conditioners act by neutralizing the electrical negative charge of the hair. Common ingredients of conditioners include dimethicone, simethicone, glycerin, propylene-glycol, quaternized cationic derivatives, cationic polymers, polyvinyl-pyrrolidone, stearyltrimonium-chloride and hydrolyzed animal proteins. Conditioners can temporarily improve split ends and mend trichoptilosis. There are common myths among general population such as the better it foams the better it cleans; sulfateless shampoo is good for your hair health; not to wash your hair frequently; attractive list of ingredients like chemical sun screens, vitamins, pro-vitamins, botanicals makes shampoo better.

Straightening & Permanent Waves: The least permanent way to straighten hair is blow drying and/or flat ironing. This method uses heat for straightening which will only last until the next wash. Using excessive heat (>190 °C) can be detrimental to hair health. The mechanisms of relaxing is the breaking of hair disulfide bonds, re-forming of hair shape and re-making of the linkages. The shape of the hair changes from curly to straight, and the effect of hair straightening is permanent. The main adverse effects of hair straightening are scalp burns and hair breakage.

A permanent wave is a process that makes the hair curly, using chemicals that break and reform the strong disulfide bonds of the hair shaft. Common side effect is trichorrhesis nodosa.

Hair dyes: Hair dyes are cosmetics used to change hair color. Hair dyes are classified according to their origin: i) vegetable hair dyes ii) mineral or metallic hair dyes and iii) synthetic hair dyes. Synthetic hair dyes are classified according to the degree of penetration as follows: i) temporary hair dyes ii) semi-permanent hair dyes and iii) permanent hair dyes. Adverse effect of hair dyes are i) cuticle damage ii) allergic contact dermatitis and iii) carcinogen in animal models but for human remains largely inconclusive mixed results. **Hair in forensic medicine:** Hair analysis is useful to identify doping practices and drug abuse, poisoning, DNA. Proteins in hair may offer a useful alternative to DNA. If the new method does prove itself, it will be a game changer for forensics.



3rd INDERCOS

National Dermatology & Cosmetology Congress with International Participants

14-17 MARCH, 2018
HILTON ISTANBUL BOSPHORUS HOTEL
ISTANBUL, TURKEY

NEW TRICHOSCOPIC OBSERVATIONS IN FEMALE HAIR LOSS

Esra Kural

In female pattern hair loss (FPHL), hair diameter diversity, peripilar signs, yellow dots, short vellus hair on the frontal scalp, pinpoint white dots, scalp pigmentation and focal atrichia can be detected by dermatoscopy.

Hair diameter diversity (anisotrichosis) is a typical feature of androgenetic alopecia. More than 20% of diversity is a diagnostic feature for androgenetic alopecia. Hair diameter diversity is also seen in alopecia areata, however the hair shafts are homogeneously miniaturized.

Short vellus hairs (<0.03 mm) are a sign of severe miniaturization. Their presence in the frontal scalp is a very useful clue for diagnosis. FPHL can be diagnosed when 10% or more than seven vellus hairs are detected in the frontal scalp.

Peripilar signs are features seen

in androgenetic alopecia, particularly in early phase. They appear as brown depressed halos surrounding the follicular openings.

Yellow dots are a sign of severe miniaturization and are more numerous in patients with severe FPHL. More than four yellow dots in four images from the frontal scalp at high magnification (70×) are considered a major criterion for diagnosis. In addition to severe cases of androgenetic alopecia yellow dots are typical of alopecia areata, and are also seen in some cases of alopecia areata incognito, trichotillomania, and chemotherapy alopecia.

Other features of FPHL are pinpoint white dots; in very severe cases; scalp pigmentation; in sun-exposed areas; and focal atrichia in post-menopausal women.

Differential diagnosis can be made with chronic telogen effluvium and alopecia areata incognito.

In chronic telogen effluvium, dermoscopy shows an absence of variability and, in some cases, short regrowing hairs of normal thickness.

In alopecia areata incognito, dermoscopy shows the presence of numerous yellow dots and short regrowing tip-shaped miniaturized hairs (2–4 mm long). The pattern is easily seen at all magnifications.

3rd INDERCOS

National Dermatology & Cosmetology Congress with International Participants

14-17 MARCH, 2018
HILTON ISTANBUL BOSPHORUS HOTEL
ISTANBUL, TURKEY



HAIR GROWTH ASSESSMENT TECHNIQUES

Esra Kural

Hair growth assessment tools in a trichologic consultation comprise global photographs of scalp, dermatoscope, trichogram, unit area trichogram, phototrichogram and scalp biopsy in addition to thorough clinical history and a physical examination.

Global Photography: Standardized or semi-standardized scalp pictures should be taken of every hair patient at their first visit or before the start of a new therapy. In this way, disease progression or success of therapy can be tracked.

Scalp dermoscopy also known as trichoscopy is the examination of the scalp with a dermatoscope. When dermatoscopic images are digitally captured or processed, the instrument can be referred to as a video dermatoscope. Digital dermatoscopy offers the advantage of storing the images for further controls. The magnification enhances the images of scalp and hair and detects the hair shaft in the follicle and its length, diameter and possible anomalies.

Trichogram/Unit area trichogram: By using a rubber-armed forceps 50–70 hairs are plucked at two specific scalp locations depending on the hair disorder. The hair should not be washed 5 days prior to epilation (The hair should not be washed to avoid premature plugging of telogen hairs). The microscopic evaluation of the hair roots is done by low-power microscopy (not more than 40-fold magnification). Anagen hairs are distinguished from telogen hairs, and anagen to telogen ratios are calculated. The unit area trichogram (UAT) is based on plucking hair in a defined area (usually >30 mm²) and allows the determination of hair density. Disadvantages of the trichogram/UAT are i) plucking process is painful ii) the plucking procedure causes hair damage iii) many patients find it unpleasant not to shampoo for 5 days. One more major drawback of the trichogram/UAT is that hairs in early anagen and vellus hairs are easily missed in a standard plucking process because of their small size. Trichograms should be reserved for special cases like loose anagen syndrome or diffuse alopecia areata.

Phototrichogram: The basic principle of the phototrichogram is taking close-up photographs of a certain defined scalp. Before taking the first photograph, cut the hair in the area short to a defined length (usually 1 mm). To increase the contrast of hair and scalp, the hair has to be dyed with dark hair dye to make vellus hair and light or white hair visible against the background. After certain periods, recurrent photographs are taken. Depending on the type of image analysis, the following parameters can be determined: i) Total number of hairs per area (hairs/cm²) ii) Vellus to terminal hair ratio, anagen to telogen ratio iii) Linear hair growth rate (millimeters per day) (measured by the change in length of renewable hair on the subsequent picture) iv) Hair thickness. When images are taken 3 days after hair clipping, growing hairs can be differentiated from non-growing hairs. The software cannot diagnose telogen or anagen hair loss like a histopathologist. However, based on the biological behavior of those hairs, the software identifies non-growing hairs as telogen hairs and growing hairs as anagen hairs.

Histopathological analysis of scalp biopsies has been used for some time now to investigate hair growth. It has since been shown that horizontal sectioning provides better diagnostic information than vertical sections alone. Horizontally cut punches can be examined for the number of hair follicles, follicular units, hair diameter, and growth parameters (terminal to vellus hair ratio, anagen to telogen ratio, and catagen hair). If vertical sections or direct immunofluorescence are desired, a second 4-mm biopsy specimen could be obtained. Scalp biopsy is a sensitive method, but it is painful and invasive. Correct analysis of histopathology is a tedious job and requires expertise.



3rd INDERCOS

National Dermatology & Cosmetology Congress with International Participants

14-17 MARCH, 2018
HILTON ISTANBUL BOSPHORUS HOTEL
ISTANBUL, TURKEY

NEODYMIUM-DOPED YTTRIUM ALUMINUM GARNET (Nd:YAG) LASER FOR VASCULAR LESIONS

Zehra Aşiran Serdar

Nd:YAG laser has a 1064 nm. wavelength with deeper penetration and provides treatment in a wide range of vessel diameters in most skin types. The Nd:YAG laser is used effectively in treatment of telangiectasia of the face and leg veins. Leg telangiectasia is more difficult to treat than facial telangiectasia. Total duration and session of the treatment depends on skin type and the size, form and location of the lesions. Prior to the treatment, venous doppler must be required due to the possibility of venous insufficiency in leg veins. Patients must be informed comprehensively about the anticipated results and possible complications or side-effects of the treatment and consent of them must be received. Complications and side-effects of Nd:YAG laser treatment are pain, edema, bleeding, purpura, blistering and discoloration.

3rd INDERCOS

National Dermatology & Cosmetology Congress with International Participants

14-17 MARCH, 2018
HILTON ISTANBUL BOSPHORUS HOTEL
ISTANBUL, TURKEY



LASERS FOR HAIR REMOVAL

Victor Gabriel Clatici

Laser hair removal (and IPL hair removal) represent one of the most frequent procedures worldwide and the main benefits of Energy Based Devices (EBD) hair removal are represented by saving time, smoother skin and save money. Because of the frequency of the procedures there are a lot of competitions (other doctors, home devices and cosmetic salons).

The approach of the procedure must start with the first consultation of the patients for hair removal, in order to establish both the contraindications and the management plan, including setting the expectations of the patient.

Is very important for patients to understand that options varies with efficiency, the degree of discomfort and cost and each procedure involves a specific degree of efficiency, cost, the possibility of adverse reactions.

The limits of laser procedure is strong connected with a lot of factors like nature (hair color, associated diseases, the presence of nevi or tattoos in the areas to be treated etc.), patient preparation, doctors' professional training, technology used, and doctor - patient communication.

There are a lot of factors which you must think before you choose your device, respectively wavelength, pulse duration, cooling methods, spot, pulse repetition frequency, the possibility to use all year round, power, fluency etc.

When you promote your practice don't forget the advantages of laser interventions performed by medical staff, respectively establish a "relationship" with the patient, scheduling other types of intervention, developing long-term relationships, and safety and efficiency.

In conclusion, laser intervention for hair removal increasing patient's quality of life (health and beauty, more time, more money, fewer side effects, etc.) and „provide,, time, money and happiness in the long term.



3rd INDERCOS

National Dermatology & Cosmetology Congress with International Participants

14-17 MARCH, 2018
HILTON ISTANBUL BOSPHORUS HOTEL
ISTANBUL, TURKEY

KTP-LASERS IN DERMATOLOGY

Maja Hofmann

Vascular abnormalities can be targeted with specific light and laser devices. In addition to KTP laser, pulsed dye laser (PDL) and Nd:YAG laser, also intense pulsed light devices (IPLs) are used. Vascular changes include superficial and deep vascular lesions. A popular laser device for treatment of superficial vascular lesions is the potassium-titanyl-phosphate (KTP) laser. This system, which is a frequency-doubled neodymium-doped yttrium aluminum garnet (Nd:YAG) laser, produces green light at a wavelength of 532 nm. This wavelength is near the first absorption peak of oxyhemoglobin. One advantage of the KTP-laser over PDL is the lack of post interventional purpura for the treatment of rosacea and telangiectasia. The main disadvantage to the 532 nm wavelength produced by these lasers is the greater absorption of energy by epidermal melanin with a greater risk of pigmentary changes. Other potential side effects include transient erythema, edema, and crusting. Scars are very rare reported in KTP-lasertherapy compared to Nd:YAG lasertherapy. Atrophic scars have also been known to be caused by this laser, particularly while using high fluency to treat small telangiectasia around the nose.

Other indications of the usage of KTP-laser are senile angioma, fibrous papules of the nose and treatment of small warts. The ablative effect of KTP-lasers can also be used in treatment of xanthelasma or benign skin tumors, but only if there is no ablative device like CO₂- or Er:YAG laser available. In conclusion, the main treatment indication of KTP-lasers are superficial vascular changes with a light to moderate side effect profile.

3rd INDERCOS

National Dermatology & Cosmetology Congress with International Participants

14-17 MARCH, 2018
HILTON ISTANBUL BOSPHORUS HOTEL
ISTANBUL, TURKEY



CARBONDIOXIDE (10600 NM) AND ER_GLASS (1540 NM) COMBINATION LASER USE IN DERMATOLOGY

Ahu Birol

Ablative and non-ablative lasers are used for the treatment of a wide group of diseases. Ablative lasers offer faster results but not applicable to all the patients due to the long down-time and higher risk of pigmented disorders. Non-ablative lasers are much more tolerated by any skin type and can be used on almost every patient, but need repeated sessions to achieve the desired results.

The you laser MT, utilizes ablative (10600 nm) CO₂ and non-ablative (1540 nm) er-glass in one fractional laser. It is possible to use simultaneous or sequential emission of 10600 nm and 1540 nm. During the procedure, the 1540 nm non-ablative fractional laser creates micro channels deep in the skin while the CO₂ 10,600 nm creates surface micro ablative dots. The mixed technology utilizes the two laser wavelengths to make changes to both the deep dermal layer as well as the surface epidermal layer. It allows the practitioner to maximise the advantage of each technology. Producing results similar to ablative treatments with almost no downtime for patients.

It can be used for the treatment of facial rejuvenation, fine and deep wrinkles, acne scarring, stria, sun-damaged tissue treatment. The You laser Mixed Technology can treat the any area of the face and body. It is uniquely effective in the delicate periorbital (around the eyes) and perioral (around the mouth) areas and scars. A topical numbing cream may be applied to the skin prior to treatment to alleviate discomfort. Many patients see improvement one week after treatment. Great results are visible in two to three months. Patients may apply make-up five days after treatment. After treatment, the skin looks sunburned and may be slightly swollen. Patients report little or no discomfort post treatment. During post care, patients apply ointment to the skin for four to five days and should limit sun exposure and wear protective clothing.

Surgical apparatus can be used for the treatment of corn, callus, verruca, syringoma, dermal nevi..



3rd INDERCOS

National Dermatology & Cosmetology Congress with International Participants

14-17 MARCH, 2018
HILTON ISTANBUL BOSPHORUS HOTEL
ISTANBUL, TURKEY

LASERS FOR HPV

Eda Tiftikçi

Cutaneous warts are benign neoplasms caused by human papillomavirus (HPV) infection of keratinocytes. Warts are commonly diagnosed lesions, with an estimated 10% incidence. (1)

Common warts, which can arise on any part of the body, account for 70%, while plantar and flat warts account for 24% and 3.5%, respectively. The remaining 2.5% includes anogenital warts and mucous membrane warts (eg, oral, laryngeal). (2)

Although there are more than 100 serotypes of HPV, knowing the serotype does not influence the treatment of benign warts. Warts vary in appearance, size, shape, and treatment response depending on the type of epithelium affected. (3)

Numerous treatments for nongenital warts are available, although no single therapy has been established as completely curative. Watchful waiting is an option for new warts, because they tend to be self-limited and treatment does not decrease transmissibility of the virus. In the 17 trials, the average reported cure rate was 30 percent within 10 weeks. Observational studies have shown that one-half of cutaneous warts resolve spontaneously within one year, and about two-thirds within two years. However, many patients request treatment because of social stigma or discomfort. Ideally, treatment has been established as completely curative, many options are available. The effectiveness and safety of these treatments generally have not been assessed in randomized controlled trials (RCTs). Many non-RCTs have been published on the treatment of cutaneous warts, but should be interpreted with caution because of a significant placebo effect. (4)

Despite high prevalence, warts can pose a therapeutic challenge. No monotherapy has achieved complete remission in every case. The most common treatments are salicylic acid (SA) and cryotherapy. Other modalities include chemical agents (eg, cantharidin, formaldehyde), chemotherapeutics (eg, podofilox, fluorouracil, bleomycin sulfate), contact sensitizing agents (eg, dinitrochlorobenzene, squaric acid dibutyl ester), and immunomodulators (eg, interferon, imiquimod). Surgical excision, curettage, and laser therapy are physical means of treating warts. (2)

Lasers can be an effective treatment option for both simple and recalcitrant warts. The lasers most studied for this purpose are CO₂, PDL, and Nd:YAG and of these, PDL has the fewest adverse effects. Currently, use of lasers for wart treatment is limited by lack of established treatment guidelines. Future studies are needed to compare laser modalities with each other and with nonlaser treatment options, and to establish optimal treatment protocols. (5)

3rd INDERCOS

National Dermatology & Cosmetology Congress with International Participants

14-17 MARCH, 2018
HILTON ISTANBUL BOSPHORUS HOTEL
ISTANBUL, TURKEY



References:

1. Robson KJ, Cunningham NM, Kruzan KL, et al. Pulsed-dye lazer versus conventional therapy in the treatment of warts:a prospective randomized trial. J Am Acad Dermatol.2000;43 (2,pt1):275-280.
2. Cobb MW, Human papillomavirüs infection. J Am Acad Dermatol. 1990;22(4):547-566
3. Gibbs S, Harvey I. Topical treatments for cutaneous warts. Cochrane Database Syst Rev. 2006(3): CD001781.
4. Mulhem E, et al. Am fam Physician.2011;Mulhem E, et al. Am fam Physician.2011;Mulhem E, et al. Am fam Physician.2011;84(3):288-29
5. Nguyen J, et al. JAMA Dermatol, 2016;152(9):1025-1034



3rd INDERCOS

National Dermatology & Cosmetology Congress with International Participants

14-17 MARCH, 2018
HILTON ISTANBUL BOSPHORUS HOTEL
ISTANBUL, TURKEY

VAGINAL REJUVENATION WITH CO2 LASER

Mario Trelles

Vulvovaginal atrophy is a common condition in postmenopausal women, presenting with symptoms of dryness, irritation, soreness, and dyspareunia. Genital and sexual symptoms due to lack of lubrication produce discomfort or pain as well as impaired function in the urinary tract. Clinical findings include a pale and dry vulvovaginal mucosa and can lead to infections with petechiae formation.

The CO2 laser for the so called intimate surgery is a hot topic at present within the various indications of lasers. Patient report improvement of the above list of symptoms and only a mild and transient discomfort with itching is the most commonly reported mild side effects.

Laser treatment mechanism of action basically depends on the use of a wavelength which should be highly absorbed by water, as it is the case of the carbon dioxide (CO2) laser. With this system ablation and coagulation of vaginal and vulva tissues can be done, and this laser is indicated for treatment of redundant skin of the minor and major labia.

Wound healing response is initiated to repair the originated micro lesions of laser by thermal effect, resulting in tissue remodeling with collagen and elastic fibers neoformation in the atrophic skin. Muscle tone of the vagina also is benefited by tightening the supportive structures of the vulvovaginal area. The sequence and number of treatments depends on the severity of symptoms, the effectiveness, safety, and the outcome observed.

NON-THERMAL LASER SKIN REJUVENATION OF DARK SKIN DURING THE SUMMER

Mario Trelles

This clinical study reports on the efficacy and safety of a method of facial rejuvenation using a 2940 – nm Erbium:YAG laser with Spatially Modulated Ablation™. This study was performed in women moderate to severe signs of facial aging relative to chronological age, who underwent two treatment sessions with an Er:YAG laser coupled to the RecoSMA™ technology (Linline, Minsk, Belarus).

The whole face was treated in all patients. Clinical efficacy, tolerance, adverse effects, complications, and histological changes due to the treatment, were evaluated. Photographs and biopsies were taken before treatment and 3 months after the second treatment session. All patients completed the study and presented no significant complications. Histological changes in the epidermis and dermis as a result of treatment were found. Fine lines, wrinkles and overall facial aging improved significantly ($p < 0.0001$). The mean reduction of fine lines and wrinkles was 59% ($r = 40\% - 75\%$). The mean improvement of overall facial aging was 74% ($r = 55\% - 90\%$). After showing the patients the comparative photographs before and after treatment, 75% of women stated that they were satisfied or very satisfied, and would recommend the treatment. Preliminary results show an excellent safety/efficacy profile for this technology which, based on observed results, is considered to have advantages over other methods of facial rejuvenation with lasers, particularly on dark skin phototypes and during the summer season.

3rd INDERCOS

National Dermatology & Cosmetology Congress with International Participants

14-17 MARCH, 2018
HILTON ISTANBUL BOSPHORUS HOTEL
ISTANBUL, TURKEY



PSORIASIS TREATMENT IN CHILDREN AND PREGNANCY

Erkan Alpsoy

Psoriasis treatment has become much more effective in recent years because of increased knowledge about the disease and introduction of new, effective and targeted treatment options. Therefore, psoriasis can be controlled better, and long-term remissions can be provided. Many parameters should be considered in determining the treatment and its duration. In some special cases and/or patient groups, treatment approaches show some differences from the usual psoriasis treatments. Treatment alternatives have to be chosen more carefully in these patient-specific conditions. In this presentation, treatment approaches in childhood period and pregnancy will be summarized in the light of current knowledge and algorithmic treatment approaches will be given.

Psoriasis treatment in children; Psoriasis is a significant dermatological problem in the pediatric population and it starts in childhood almost one-third of the cases. Pediatric psoriasis can be in association with serious co-morbidities such as obesity, hypertension, hyperlipidemia, diabetes mellitus. Psoriasis can lead to profound and long-term effects on children's mental health. Psoriasis-related symptoms and psychiatric co-morbidity may also negatively impact school performance.

Approximately 3 of 4 psoriasis patients have mild to moderate psoriasis and respond to topical treatment. In the treatment of mild to moderate psoriasis, topical treatments should be the first choice. Topical corticosteroids (TCS) are usually considered as the first-line treatment. In clinical practice, TCS are used in combination with calcipotriol and calcineurin inhibitors or rotationally because of their well-known side effects. Tacrolimus and pimecrolimus are effective steroid-sparing treatments in facial, intertriginous and anogenital areas. If topical treatments are not effective, UVB can be used. Particularly narrowband UVB (nbUVB) is an effective choice especially in diffuse guttate and thin-plaque psoriasis. Traditional systemic agents such as methotrexate, cyclosporine and acitretin should be used in the treatment of severe psoriasis. Systemic treatments can be combined with topical treatments to increase the effectiveness. Biological agents are other alternatives to control the disease in unresponsive cases. In this circumstances, anti-TNF- agents (etanercept and adalimumab, aged ≥ 4 years) and ustekinumab (aged ≥ 12 years) should be selected.

Psoriasis treatment in pregnancy or those planning pregnancy in the near future; In 3 of 4 pregnant psoriasis patients, the course of the disease changes. The improvement in the course of the disease is about 2 times more than the worsening. On the other hand, complications such as low birth weight and preterm delivery are more frequent in pregnant patients with psoriasis. Drug use in pregnancy is avoided because of possible side effects on the fetus. Drug studies on pregnancies can not be done for ethical reasons. Naturally, studies on this area is limited and there is no evidence-based approach to this issue.



3rd INDERCOS

National Dermatology & Cosmetology Congress with International Participants

14-17 MARCH, 2018
HILTON ISTANBUL BOSPHORUS HOTEL
ISTANBUL, TURKEY

Topical treatment options are the drugs used in the first step for pregnant patients or those women planning pregnancy in the near future. Emollients are safe topical preparations with no significant side effects, and can be used to relieve both itching and scaling. Mild or moderate TCS may be preferred in the first step for a short time. These agents are more reliable in the second half of pregnancy. While current data indicate that strong or very strong TCS may cause low birth weight, similar association has not been reported with mild to moderate TCS. Patients should be advised not to use excessive amounts of TCS in large areas. Calcipotriol and tacrolimus are other topical agents that can be evaluated in the treatment. Pregnancy category of TCS, calcipotriol and tacrolimus are C. UVB treatment, particularly nbUVB is an important treatment choice in pregnancy. It does not cause any anomaly and premature birth in the fetus. For this reason, nbUVB can be selected as first-line treatment in patients who do not respond to topical treatments or in patients with moderate to severe psoriasis. Biological treatments, corticosteroids and cyclosporin are the drugs to be used in the second step for the treatment of moderate to severe psoriasis. As a general rule, systemic treatment in the first trimester should be avoided as much as possible. Current knowledge suggests that biological treatment options (pregnancy category B) do not pose a significant risk. However, their use in the fertilization period are not recommended. In later stages of pregnancy, they can be used with caution in severe and/or unresponsive cases 8-10 weeks prior to the expected date of birth. If possible, lower doses should be preferred and/or treatment intervals should be extended. Because of its short half-life, etanercept is the first choice in biological drugs. Etanercept is a fusion protein and shows less transplacental transport than other monoclonal antibodies such as adalimumab and infliximab. Cyclosporine (pregnancy category C) can be used in psoriatic pregnancies as an effective and relatively safe alternative. Systemic corticosteroids (pregnancy category C) as a treatment option should be considered only in generalized pustular psoriasis and should be used with caution. The use of acitretin and methotrexate (pregnancy category X) is not recommended.

3rd INDERCOS

National Dermatology & Cosmetology Congress with International Participants

14-17 MARCH, 2018
HILTON ISTANBUL BOSPHORUS HOTEL
ISTANBUL, TURKEY



SOME PRACTICAL POINTS IN MANAGING PSORIATIC PATIENTS

Omid Zargari

The targets of anti-psoriatic medications have evolved in parallel with the substantial changes in our understanding of the pathophysiology of psoriasis. In addition, the expanded offering of new therapeutic options has raised the bar regarding outcomes, such that both dermatologists and patients now expect long-term disease control and clearance.

In spite of all the progresses, methotrexate(MTX), is still considered in most of the world as the gold-standard agent for the treatment of severe psoriasis and psoriatic arthritis.

MTX is a folate antagonist with anti-inflammatory, antiproliferative, and immunosuppressive effects. It is one of the main and relatively safe systemic therapies for psoriasis and has been widely used to treat patients with the condition for over 50 years.

Herein I provide an overview of how MTX works and how to dose it, the advantages offered by MTX in the era of biologics, and a few pearls regarding how best to use MTX based on my clinical experience.



3rd INDERCOS

National Dermatology & Cosmetology Congress with International Participants

14-17 MARCH, 2018
HILTON ISTANBUL BOSPHORUS HOTEL
ISTANBUL, TURKEY

ACETIC ACID AND POTASSIUM HYDROXIDE USES IN DERMATOLOGY

Ercan Arca

In dermatological diagnosis, the potassium hydroxide (KOH) examination in superficial fungal infections is a traditionally method. Although microscopic evaluation of KOH-treated samples does not allow for speciation or characterization of the susceptibility profile, it is used as a quick, easy and inexpensive tool to provide evidence of dermatophytosis. In fungal infections involving the skin, hair or nails, scales from the advancing border, subungual dermis, or affected hair removed and placed on a glass slide. KOH 10-20% dropped on specimen and covered with a cover slip. The undersurface of the glass slide may be gently heated with a low-fit flame. It softens keratin and highlights the dermatophyte. Long narrow septated and branching hyphae may be visualized under microscopic examinations.

Application of acetic acid solution to the genital skin followed by magnified examination permits the detection of grossly inapparent flat condylomata acuminata.

Naked-eye visual inspection of the cervix with acetic-acid wash (VIA), or cervicoscopy, is an alternative to cytology in screening for cervical cancer in poorly resourced locations. The need for simple, cost-effective screening approaches for cervical cancer prevention in low-resource countries has led to the evaluation of visual screening with 3–5% acetic acid. The low reproducibility and wide variation in accuracy reflect the subjective nature of the test. Pooled sensitivity, specificity, positive and negative predictive values were 80%, 92%, 10% and 99%, respectively, for detecting cervical intraepithelial neoplasia grade 2 or worse lesions. Realistic sensitivity of a quality- assured single visual inspection with acetic acid is around 50%. A single round of visual inspection with acetic acid screening has been associated with a 25–35% reduction in cervical cancer incidence and the frequency of cervical intraepithelial neoplasia grade 2 or worse lesions in randomised-controlled trials. Despite all its limitations, implementing visual inspection with acetic acid screening in lowresource countries may provide a pragmatic approach to building up human resources and infrastructure that may facilitate the highly anticipated low-cost, rapid human papilloma virus testing in the near future.

In this lecture, in dermatological practice uses of potassium hydroxide preparation and acetic acid will be presented.

3rd INDERCOS

National Dermatology & Cosmetology Congress with International Participants

14-17 MARCH, 2018
HILTON ISTANBUL BOSPHORUS HOTEL
ISTANBUL, TURKEY



EVALUATION OF DIRECT IMMUNOFLOUORESCENCE ASSAY AND CYTOLOGICAL EXAMINATION IN DERMATOLOGY

Murat Durdu

Cytology is a simple, quick, valuable, and inexpensive diagnostic method based on the investigation of characteristic features of individual cells. In this method, cellular materials are obtained by scraping method, slit-skin smear, touch smear or fine needle aspiration method according to the type of skin lesions. Obtained materials are immediately spread as a thin layer onto a microscopic slide. Slides are stained with various cytological dyes, and then they are examined under the light microscope. Many different cytological stains can be used to stain cytological materials. Each of them has its own advantages and disadvantages. The most common stains used in dermatocytology are Giemsa and Wright stains. However, cytologically, differentiation between herpes simplex virus (HSV) and varicella zoster virus (VZV) infections cannot be made by these routine cytological stains. Direct immunofluorescence examination or immunohistochemical examination required for this distinction. This distinction is not only important for sustaining a correct clinical diagnosis, but also for determining antiviral dosing, which differs between VZV and HSV infections. If it is a HSV infection, positive fluorescence are detected by fluorescein-labelled HSV type 1 or 2-specific monoclonal antibodies. If it is a HZV infection, positive fluorescence are detected by fluorescein-labelled HZV specific monoclonal antibodies. Immunofluorescence examination can also be used to show some bacteria, fungus and viruses that cannot be detected with routine cytological stains. Spirochetes can be detected not only by dark field microscopy but also by detected by fluorescein-labelled anti troponemal antibody. In order to detect of mycobacteria, EZN staining or direct immunofluorescence test should be made. In addition, autofluorescence can be detected, when H&E stained slides are examined under a fluorescent microscope.

Immunofluorescence assays are important not only for detecting infection agents but also for diagnosis of pemphigus. This autoimmune bullous disease, which has high mortality, should be differentiated from other acantholytic diseases such as Hailey-Hailey's disease and Grover's disease. Cytologically, if there is only acantholytic cell without multinucleated giant cell, corps rond and grain, an immunofluorescence assay on smear should be performed. IgG deposition around the acantholytic cell is highly sensitive (86-100%) and specific (100%) for diagnosis of pemphigus.



3rd INDERCOS

National Dermatology & Cosmetology Congress with International Participants

14-17 MARCH, 2018
HILTON ISTANBUL BOSPHORUS HOTEL
ISTANBUL, TURKEY

STAINS FOR DERMATOLOGICAL DIAGNOSIS (PAS, METHENAMINE SILVER ETC..)

Murat Durdu

Potassium hydroxide (KOH) examination is the first screening tool used to identify fungal hyphae and spores. Gram stains and calcofluor stains may reveal hyphae when the KOH test result is negative. When direct microscopic examination and culture are negative, histopathologic examination is performed for differential diagnosis. A small number of fungal hyphae and spores are easily overlooked in Hematoxylin Eosin stained sections. In suspected cases of Majocchi granuloma and other deep dermatophytosis, confirmatory stains such as periodic acid-Schiff (PAS) or Gomori's methenamine silver (GMS) can be performed. GMS also stains algae, cyst walls of *Pneumocystis jiroveci*, intracytoplasmic granular inclusions of Cytomegalovirus, *Actinomyces Israeli*, *Mycobacterium spp.*, and *Klebsiella pneumoniae* and *Streptococcus pneumoniae*. It may not be possible to distinguish between pigmented fungus and hyaline fungus in GMS stained sections. This distinction is necessary for the diagnosis of phaeohyphomycosis. Another disadvantage of GMS staining is that it shows insufficient inflammatory to fungal invasion. Some of the artifacts observed in GMS staining are not observed with PAS staining. In PAS-stained sections obtained from caseating granulomatous lesions, calcific bodies are stained with PAS positive and confused with budding yeasts. This false positivity can be avoided with GMS stained sections. The best combination is PAS and GMS staining to reduce the incidence of false positive results in diagnosis of fungal infections.

PAS staining is used not only for the diagnosis of fungal infections but also for the diagnosis of certain diseases. Demonstration of PAS-positive stained mucopolysaccharides is valuable for diagnosis of Paget's disease, adnexial tumors and clear cell acanthoma. Furthermore, immunoglobulin deposits are seen as PAS positive hyaline globules in glomeruloid hemangioma.

3rd INDERCOS

National Dermatology & Cosmetology Congress with International Participants

14-17 MARCH, 2018
HILTON ISTANBUL BOSPHORUS HOTEL
ISTANBUL, TURKEY



WOOD'S LAMB AND DERMATOLOGY

Kenan Aydoğar

Invented in 1903 by a physicist, Robert W. Wood, Wood's lamp(WL) uses a light source with a glass filter containing barium silicate and 9% nickel oxide to emit bands of light between 320 and 400 nm (peak 365 nm). The light source may be from a fluorescent tube, a mercury vapor lamp, a light-emitting diode, or an incandescent light. Tissue fluorescence occurs when WL is absorbed and visible light is emitted; however, this is minimal in normal skin due to the presence of amino acids, elastin, and melanin. Fluorescent bulbs (black lights) emitting a similar, although slightly broader, spectrum light are also available. Initially used for the detection of fungal infection, WL examination may also be useful in clinical settings where bacterial infection, pigmentary disorders, porphyrias, photodynamic diagnosis of skin cancer, tetracycline use, or exposure to fluorescent materials is suspected. (Table 1) (1-10). This lecture presents the WL, a useful, and cost-effective diagnostic tool to quickly assess many dermatologic conditions.

Table 1. Dermatologic diagnosis with the use of Wood's lamp and its fluorescences



3rd INDERCOS

National Dermatology & Cosmetology Congress with International Participants

14-17 MARCH, 2018
HILTON ISTANBUL BOSPHORUS HOTEL
ISTANBUL, TURKEY

Clinical setting/ diseases	Condition	Chromophore or fluorescent compound	Appearance / Colour of fluorescence
Pigmentary disorders	Vitiligo	Absence of melanin	Bright bluish-white
	Anaemic naevus	Auto-fluorescence	No fluorescence-normal pigmentation
	Pityriasis alba	Auto-fluorescence	No fluorescence-normal pigmentation
	Progressive macular hypomelanosis	Absence of melanin and coproporphyrine III	Bluish-white and follicle-bound coral-red
	Lentigo maligna	Melanin	Dark-brown to black
	Ephelides	(Epi)dermal melanin	Dark-brown
	Melasma	(Epi)dermal melanin	Dark-brown
	Tuberous sclerosis	Decrease of melanin	White
Fungal infections	Dermatomycosis		
	- <i>Microspora species</i>	Pteridine	Bright-green
	- <i>Trichophyton schoenleinii</i>		Blue
	Pityriasis versicolor	<i>Mallasezia furfur</i>	Chamois leather-like
	Pityrosporum folliculitis	<i>Mallasezia furfur</i>	Follicle-bound bluish-white
Bacterial infections	Erythrasma	Coproporphyrin III	Coral-red
	<i>Propionibacterium acnes</i>	Coproporphyrin III/Protoporphyrin IX	Coral-red
	<i>Pseudomonas</i> infections	Pyoverdin/pyocyanin	Yellow-green
Porphyria	Porphyria cutanea tarda	Porphyrins in urine and faeces	Pink-red
	Erythropoietic porphyria	Porphyrins in teeth and blood	Pink-red
Non-melanoma skin cancer	Basal cell carcinoma/ squamous cell carcinoma including actinic keratosis	5-aminolevulinic-induced protoporphyrin IX	Coral-red
Medications	Tetracycline		Yellow fluorescence on nails teeth, bone
	Fluorescein		Yellow fluorescence
	Salicylic acid		Green

3rd INDERCOS

National Dermatology & Cosmetology Congress with International Participants

14-17 MARCH, 2018
HILTON ISTANBUL BOSPHORUS HOTEL
ISTANBUL, TURKEY



References

1. Kamath NK, Pai G, Pinto J. Wood' light examination. *Annals of Dermatol* 1995;7:283-87
2. Asawanonda P, Taylor C.R. Wood's light in dermatology. *Int J Dermatol* 1999; 38: 801-7.
3. Gupta L.K., Singhi M.K. Wood's lamp. *Indian J Dermatol Venereol Leprol* 2004; 70: 131-5.
4. Ducharma EE, Silverberg NB. Selected applications of technology in the pediatric dermatology Office. *Semin Cutan Med Surg* 2008;27:94-100
5. Ruocco, E., Baroni, A., Donnarumma, G., & Ruocco, V. Diagnostic procedures in dermatology. *Clin Dermatol* 2011;29: 548-56.
6. Gebhard RE, Wood's light examination. In Pfenninger & Fowler's Procedures for primary care. Pfenninger JL, Fowler GC, eds. 3rd ed. Elsevier Mosby, Philadelphia, 2011;275-77
7. Ponka, D., & Baddar, F. Wood lamp examination. *Canadian Family Physician*, 2012;58: 976.
8. Klatte JL, Van der Beek N, Kemperman PMJH. 100 years of Wood's lamp revised. *J EADV* 2015;29:842-7
9. Sharma, S., & Sharma, A. (2016). Robert Williams Wood: Pioneer of invisible light. *Photodermatology, Photoimmunology, & Photomedicine*, 2016;32; 60-5.
10. Limone B, Meadows L. The Wood's light's diagnostic use in dermatology. *J Dermatol Nurses Assoc* 2017;9: 211-5



3rd INDERCOS

National Dermatology & Cosmetology Congress with International Participants

14-17 MARCH, 2018
HILTON ISTANBUL BOSPHORUS HOTEL
ISTANBUL, TURKEY

EPIPHENOMENON AND OXYMORON CONDITIONS IN DERMATOPATHOLOGY

Amor Khachemoun

Epiphenomenon and Oxymoron Conditions in Dermatopathology. In the realm of dermatopathology literature, it is not infrequent to come across terminology and concepts that are ambiguous and contradictory to each other (Oxymoron conditions). Metastasizing dermatofibroma, metastasizing Spitz's nevus as well as benign melanoma are all considered oxymoron. On the other hand, there are well defined pathologic processes that occur in association with multiple distinct entities but it is not clear what their presence means in disease pathogenesis; whether they are innocent bystanders, secondary phenomenon (epiphenomenon) or have causal relationship to the relevant entity. Vasculitis in neutrophilic dermatoses, Skin lesions of Sweet syndrome and its dorsal hand variant, desmoplasia and elastophagocytosis are some examples of epiphenomena.

DERMATOLOGICAL DIAGNOSIS

Amor Khachemoun

Mohs micrographic surgery is a microscopically controlled surgical technique that excises lateral and deep surgical margins while also sparing function and achieving optimal cosmetic outcome. It involves serial excision of a tumor followed by microscopic evaluation of the tissue. It has greatly expanded since its inception to include the use of immunohistochemistry and new noninvasive imaging techniques. Both in vivo and ex vivo devices are useful in delineating lateral and deep tumor margins prior to surgery as well as to detect residual tumor ex vivo virtually in real time. Further advancements include its application to other medical specialties, such as otolaryngology. In this presentation, I will review the recent advances in Mohs surgery techniques.

3rd INDERCOS

National Dermatology & Cosmetology Congress with International Participants

14-17 MARCH, 2018
HILTON ISTANBUL BOSPHORUS HOTEL
ISTANBUL, TURKEY



ROSACEA AND SYSTEMIC DISEASES

Victor Gabriel Clatici

Rosacea was an interesting topic in history, because we have images in Louvre from 15th century, and psychiatric illness and alcoholism was considered as „causes,, of rosacea.

Rosacea is a chronic inflammatory skin disease, characterized by erythema, papules, telangiectasia, edema, pustules, or a combination, with a specific localization on central face (cheeks, forehead, chin, and nose) and peculiar symptoms (facial flushing, stinging , pain, burning sensations).

Classification of rosacea can be do clinical (erythematotelangiectatic , papulopustular, phymatous , and ocular), or by severity (mild, moderate, or severe).

Skin disorders have a negative impact on the psychological and emotional health, been associated with depression, a decreased sense of body image and self-esteem, sexual and relationship difficulties, and a general reduction in quality of life. Experience of patients with rosacea is characterized by embarrassment, low self-esteem, frustration, impaired social functioning, and social and professional isolation.

Rosacea is associated with numerous systemic comorbid diseases (in skin severity-dependent manner), and moderate to severe rosacea is associated with hyperlipidemia, hypertension, metabolic diseases, cardio-vascular diseases (CVD).

Rosacea and CVD is a very interesting association, CVD are significantly more common in the rosacea patients compared to controls. We have a higher risk of cardiovascular comorbidities - hypertension, dyslipidemia, coronary artery disease in patient with rosacea.

Rosacea is strong connected with digestive disorders (inflammatory bowel diseases, ulcerative colitis, Crohn's disease, celiac disease) and with metabolic disorders (diabetes, insulin resistance etc.)

We have a significantly increased risk of neurologic disorders (migraine, depression, complex regional pain syndrome, glioma, Parkinson disease and Alzheimer disease) and an important clustering of autoimmune diseases in patients with rosacea (T1DM, celiac disease, multiple sclerosis, rheumatoid arthritis).

In conclusion, rosacea is an important public health opportunity in order to early diagnosis of important diseases and to prevent serious complications.



3rd INDERCOS

National Dermatology & Cosmetology Congress with International Participants

14-17 MARCH, 2018
HILTON ISTANBUL BOSPHORUS HOTEL
ISTANBUL, TURKEY

ACNE AND METABOLIC SYNDROME

Victor Gabriel Clatici

The Western diet is characterized by high glycaemic load and increased high levels of milk/dairy protein, containing abundant amounts of branched-chain amino acids.

Common chronic diseases of Western societies, such as coronary heart disease, diabetes mellitus, cancer, hypertension, obesity, dementia, and allergic diseases are significantly influenced by dietary habits.

Recent epidemiologic data underline an increase in acne risk from developing to developed countries. Acne represents a disease of Western civilization, which is closely related to Western lifestyle factors, especially to the exposure to Western diet. A hyperglycemic load, milk consumption, saturated fat, and trans fat have been identified as major nutritive factors inducing or aggravating acne vulgaris.

The Western diet increase the insulin, insulin-like growth factor 1 (IGF-1), and mechanistic target of rapamycin complex 1 (mTORC1) signaling that has been implicated as playing a key role in acne pathogenesis.

Recent evidence underlines that acne is associated with mTORC1-driven pathologic conditions, such as increased body mass index, insulin resistance, melanoma in women, and prostate cancer in men.

The central controller of cell growth and anabolism, mTORC1 is implicated in several metabolic diseases of civilization, including obesity, insulin resistance, type 2 diabetes mellitus, cancer, and neurodegenerative diseases.

Metabolic syndrome (MS) is a collection of cardiometabolic risk factors that includes obesity, insulin resistance, hypertension, and dyslipidemia. The metabolic syndrome (MetS) is a major public health problem worldwide.

The cause of MetS has not been definitively established, overweight/obesity, physical inactivity, certain dietary patterns, and genetic factors are considered major risk factors.

In this context, Western diet and lifestyle, two main actors of Western civilization, appear to be the linking points between acne, Insulin Resistance, and metabolic syndrome.

Acne is also an important indicator on systemically overdone mTORC1 signaling that cause metabolic deviation on the way to serious mTORC1-driven diseases of civilization, especially obesity, arterial hypertension, insulin resistance, type 2 diabetes mellitus, cancer, and Alzheimer's disease.

Dietary attenuation of over-stimulated mTORC1 signalling may not only improve acne but may prevent the march to more serious chronic mTORC1-driven diseases of civilization.

3rd INDERCOS

National Dermatology & Cosmetology Congress with International Participants

14-17 MARCH, 2018
HILTON ISTANBUL BOSPHORUS HOTEL
ISTANBUL, TURKEY



THERAPEUTIC APPROACHES TO REDUCING ATROPHIC ACNE SCARRING

Andreas Katsambas

The treatment of post acne scars is still a therapeutic challenge, as often a single method is not enough. Most of the time a combination of more than one technique is required.

The treatment depends on the type of acne scars (macular, atrophic or hypertrophic) of which the atrophic ones can further appear as ice pick, 'rolling' or boxcar scars. In the management of acne scarring, prevention is of paramount importance as the initiation of the proper treatment may minimize the risk of scars.

The methods of scarring therapy include various types of ablative and non-ablative lasers, chemical peeling with emphasis in the 'Cross' method, skin needling, punch techniques and subcision and for the hypertrophic scars intralesional corticosteroids and probably fluouracil.

DIFFICULT AND RARE FORMS OF ACNE

Andreas Katsambas

In a significant number of acne cases there are difficulties in the management. Some of these cases are the following: poor responders to Isotretinoin (IST), patients relapsing after IST treatments, patients with acne fulminans, patients with pyoderma faciale, etc. Each of the above categories require an appropriate treatment.

There are also a rare number of acneiform dermatoses in complex syndromes. Some of them are the following: Congenital adrenal hyperplasia (CAH), Seborrhea – Acne - Hirsutism – Androgenetic Alopecia (SAHA Syndrome), Polycystic ovary syndrome (PCOS), Hyperandrogenism - Insulin resistance – acanthosis nigricans (HAIR-AN), etc.

For the above complex syndromes, a multidisciplinary approach is necessary (Dermatologist – Endocrinologist - Gynecologist).



3rd INDERCOS

National Dermatology & Cosmetology Congress with International Participants

14-17 MARCH, 2018
HILTON ISTANBUL BOSPHORUS HOTEL
ISTANBUL, TURKEY

TOLL-LIKE RECEPTORS AND ANTIMICROBIAL PEPTIDES IN DERMATOLOGY

Özgür Gündüz

Toll-like receptors (TLRs) and antimicrobial peptides (AMPs) are particular groups of molecules that play crucial roles in the early stages of the immune defense.

TLRs are a group of transmembrane proteins, which are located on the cell surface, as well as on the intracellular structures of eukaryotic cells. They constitute a subgroup of pattern recognition receptors (PRRs), which detect and bind molecular patterns that are not made by the host but, by the pathogen, (pathogen-associated molecular patterns (PAMPs)), such as lipopolysaccharides (LPS) in the outer membrane of the gram-negative cell wall; lipoteichoic acids and peptidoglycans in the gram-positive cell wall; lipoarabinomannan and mycolic acids found in acid-fast cell walls; flagellin in bacterial flagella, bacterial and viral nucleic acid, which contain a high frequency of unmethylated cytosine-guanine dinucleotide. TLRs are also known to be expressed by keratinocytes and Langerhans cells in the human skin. Stimulation of TLRs leads to an inflammatory reaction, so through inhibition or stimulation of TLRs inflammation can be manipulated. Acne, psoriasis, atopic dermatitis, syphilis, leprosy, candidiasis, herpes simplex infections are some of the skin diseases in which the TLR expressions are known to be upregulated. Cumulative experience with imiquimod, probably the most well-known and studied topical TLR-modulating agent, has shown the TLR manipulation as an effective therapeutic intervention. Several extensively-prescribed topical agents, such as nicotinamid, all-trans retinoic acid, adapalene etc, are shown to possess TLR modulating properties. There is also an ever increasing research for the development of new TLR-modulating molecules. CBT-SL5 and CpG-ODN are some recent examples for such molecules.

AMPs are a unique group of peptides, which have antibacterial activity against gram-positive and gram-negative bacteria. Human skin continuously produces these peptides and their production increases after infection. AMPs are known to show antiviral and antifungal activities. AMPs disrupt bacterial cell membranes due to their structural characteristics but do not harm human cell membranes. AMPs can also stimulate host cells' cytokine stimulation and likely play a role in cell migration, and proliferation. These properties of AMPs make them an attractive focus in the development of new therapeutic drugs.

3rd INDERCOS

National Dermatology & Cosmetology Congress with International Participants

14-17 MARCH, 2018
HILTON ISTANBUL BOSPHORUS HOTEL
ISTANBUL, TURKEY



PATCH AND PRICK TESTS: WHAT'S NEW ?

Oktay Taşkapan

Skin tests are the basic diagnostic procedures in allergology. "Patch tests" [patch test (PT), photopatch test and atopy patch test (APT)] are used in the diagnosis and/or management of allergic contact dermatitis, photoallergic contact dermatitis, atopic dermatitis (AD), (some types of) food allergy and cutaneous adverse drug reactions (CADR). Despite problems regarding standardization of test materials, APT might be a useful diagnostic tool in the evaluation of AD patients triggered by inhalant and food allergens. Especially in "mite-induced AD", APT is suggested to be a useful screening test.

The scientific evidences obtained from some recent data suggests that the role of APT in both diagnosis and epidemiology of allergic rhinitis should be redefined. A prevalence study in an unselected pediatric population (456 subjects) revealed that 78 children (17.1%) had a positive skin prick test (SPT) and 57 children (12.5%) had a positive APT. APT is frequently positive in allergic rhinitis / bronchial asthma (AR / BA) patients who have a history of current or past AD. Moreover, in some patients with respiratory allergy (AR and/or BA without AD) whose SPT results are negative, APT may be the only positive test.

"Skin prick test" widely used to demonstrate an IgE-mediated allergic reaction is the basic test in the diagnosis of respiratory allergic diseases. It is also performed in food allergy and CADR. Several methods are available to evaluate SPT results in type-I allergy testing. Reading of the largest or the average diameter of the wheals is the most commonly used technique in clinical practice. Recent data indicate that digital photographic wheal identification and 3D scanning not only gives more accurate results, but also allows for the standardization of the reading and data exchange.

References:

1. Liu Y, Peng J, Zhou Y, Cui Y. Comparison of atopy patch testing to skin prick testing for diagnosing mite-induced atopic dermatitis: a systematic review and meta-analysis. Clin Transl Allergy. 2017; 7: 41.
2. Hammond C, Lieberman JA. Unproven diagnostic tests for food allergy. Immunol Allergy Clin N Am. 2018; 38: 153-163.
3. Fuiano N, Incorvaia C. Utility of the atopy patch test in the diagnosis of allergic rhinitis. Iran J Otorhinolaryngol 2016; 28: 169-175.
4. Fuiano N, Diddi G, Delvecchio M, Incorvaia C. Prevalance of positive atopy patch test in an unselected pediatric population. Clin Mol Allergy 2015; 13:2.
5. Bousquet J, Heinzelring L, Bachert C et al. Practical guide to skin prick tests in allergy to aeroallergens. Allergy 2012; 67: 18-24.
6. Van der Valk JPM, Gerth van Wijk R, Hoorn E et al. Measurement and interpretation of skin prick test results. Clin Transl Allergy 2016; 6:8.
7. Justo X, Diaz I, Gil JJ, Gastaminza G. Prick test: evolution towards automated reading. Allergy 2016; 71: 1095-1102.



3rd INDERCOS

National Dermatology & Cosmetology Congress with International Participants

14-17 MARCH, 2018
HILTON ISTANBUL BOSPHORUS HOTEL
ISTANBUL, TURKEY

THE GOLDEN RATIO OF BEAUTY

Alev Bobuş

The divine proportion or golden section or golden ratio (GR), expressed as 1:1.618, occurs in many natural forms and represented by the symbol phi (Φ). The mathematical relationship that underlies this ratio enables the structures to be aesthetically likeable or beautiful. It has been considered as an ideal measure by many scholars, artists and architects till ancient Greeks. Leonardo da Vinci used the GR in his drawings. Parthenon at the Acropolis of Athens is based on the GR. Apple, one of the well-known computer companies designated their logo considering the GR. The GR is believed to appear ubiquitously in nature such as; in leaf arrangement of some plants, in the spiral of seashell, in the spiral of DNA, in sunflower seed, in pine cones, etc.

Ricketts indicated that this relationship seems to occur in the human face and body. Stephan R. Marquardt developed a soft tissue analysis based on the divine proportion and created a lateral (repose) and a frontal beauty mask based on this proportion. Basic framework of this mask is formed by pentagonal complex and has some differences between men and women. Many research has shown that attractive faces follow certain defined ratios of facial proportions, such as neoclassical canons and the GR which have been believed to be ideal ratios for beautiful faces. Although facial skin colors and texture are related to face attractiveness, it is thought that averageness, harmony and symmetry plays an important role in facial attractiveness.

For this reason, aim of the plastic surgeons, dermatologists and aestheticians is to provide harmonious, symmetric and balanced profile individualized to each patient. Consequently, using neoclassical facial canons conforming the GR would provide to achieve satisfactory cosmetic results.

3rd INDERCOS

National Dermatology & Cosmetology Congress with International Participants

14-17 MARCH, 2018
HILTON ISTANBUL BOSPHORUS HOTEL
ISTANBUL, TURKEY



PREGNANCY RELATED PRURITUS

Salih Levent Çınar

Pruritus is an unpleasant sensation that provokes the desire to scratch. The itch during pregnancy may have numerous causes connected mainly with infections, infestations, particular systemic disorders (e.g., liver or kidney dysfunction), pregnancy-specific dermatoses, and exacerbation of preexisting dermatologic conditions, like atopic dermatitis. Pruritus gravidarum might be both localized, affecting mainly breasts and abdomen, and generalized. It may accompany the specific dermatoses of pregnancy, although it can also occur without any underlying disease.

The cause of itch accompanying pregnancy dermatoses is still poorly understood. Although infrequent, pregnancy dermatoses can not only cause pruritus but can also carry the risk of adverse fetal and maternal outcomes. The connection between progesterone and pruritus was initially taken under consideration with regard to the pathophysiology of intrahepatic cholestasis of pregnancy. However, recent experimental studies have suggested the role of autotaxin, and its product, lysophosphatidic acid, as possible mediators of cholestatic itch in intrahepatic cholestasis of pregnancy.

The specific dermatoses of pregnancy represent a heterogeneous group of inflammatory skin diseases related to pregnancy and/or the postpartum period. A clinically relevant classification has been well established over the past 10 years and includes pemphigoid gestationis, polymorphic eruption of pregnancy, intrahepatic cholestasis of pregnancy, and atopic eruption of pregnancy. The hallmark of all four entities is severe pruritus that is accompanied by characteristic skin changes. While some of these dermatoses are distressing only to the mother because of pruritus, others may be associated with significant fetal risks. Early diagnosis and prompt treatment are therefore essential.

It should be emphasized that itching appears to be a significant problem during night hours causing significant sleep disturbances in 20% of the pregnant women with pruritus. Some studies suggest that sleeping less than 8 hours per day during the 1st and 2nd trimester is a risk factor for miscarriage, so managing nighttime pruritus is important.

In conclusion, pruritus during pregnancy is a complex symptom. Physicians taking care of the pregnant women affected with itch should undertake proper clinical management, as it is essential for the well-being not only of the expectant mother, but also of the fetus. Additional laboratory findings and careful anamnesis with an emphasis on the location and timing of the pruritus often reveal important clues that can facilitate diagnosis and efficacious treatment. However, as many pregnant women may also suffer from pruritus of unknown origin, as in our group, further studies are needed to better characterize this subset of patients and determine the best treatment options.



3rd INDERCOS

National Dermatology & Cosmetology Congress with International Participants

14-17 MARCH, 2018
HILTON ISTANBUL BOSPHORUS HOTEL
ISTANBUL, TURKEY

PREGNANCY RELATED PIGMENTATION

Salih Levent Çınar

Skin and mucosal hyperpigmentation is a common cutaneous findind in pregnancy and often is well described and mostly benign in nature. During pregnancy, many women develop blotches of dark skin upper lip, nose, cheekbones, and forehead, which resemble somewhat the shape of a mask. Medically known as chloasma or melasma gravidarum, this condition is fairly more pronounced in women who have dark skin. The pathophysiology of hyperpigmentation seems to be related to the increased levels of estrogens, and probably to increased levels of progesterone or melanocyte-stimulating hormone (MSH). In selected areas of the body such as the linea alba and areola, hyperpigmentation seems to be related to the distribution of melanocytes, but extension of these cells beyond these parts may explain unusual patterns of distribution.

The intensity of the hyperpigmentation, however, may be related to environmental factors or even intake of some drugs, although other causes may include pre-existing conditions, such as hyperthyroidism or a genetic predisposition. Nevoid hyperkeratosis of the nipple and areola should be considered in the absence of abdominal involvement. Dermal melanocytosis is another rare condition that could present with excessive pigmentation. In such cases pregnancy and sun-exposure are thought to be the triggering factors.

Most pregnancy-related skin hyperpigmentation is benign and is usually resolved after delivery (usually within months or a year), although patients may be strongly concerned. Medical treatment is rarely required. In cases where the condition persists, bleaching agents may be used, although at times their effectiveness may be unsatisfactory. Proper counseling and assurance is the only reliable alternative in such cases.

Although skin hyperpigmentation is common in pregnancy, extensive pigmentation, can also be present rarely. Patients may be cosmetically concerned, but all that is required from the health professional is reassurance that the condition has no adverse effect on pregnancy outcome. The treatment of pigmentation of pregnancy should be done after the delivery and breastfeeding periods. Combination or specially formulated creams with hydroquinone, a phenolic hypopigmenting agent, azelaic acid, and retinoic acid, nonphenolic bleaching agents, and/or kojic acid may be prescribed. Best is the protection of hyperpigmentation if possible.

3rd INDERCOS

National Dermatology & Cosmetology Congress with International Participants

14-17 MARCH, 2018
HILTON ISTANBUL BOSPHORUS HOTEL
ISTANBUL, TURKEY



PREGNANCY AND SKIN TUMORS

Salih Levent Çınar

The prevalence and behavior of certain skin tumors are affected by pregnancy, whereas others may incidentally occur during pregnancy. Melanocytic nevus enlargement and darkening can occur during pregnancy. Although the biologic behavior of normal melanocytic nevi is not altered by pregnancy according to histologic and clinical studies, it is unclear whether dysplastic nevi in patients with dysplastic nevus syndrome have increased risk for malignant change. Hormonal influence on malignant transformation of dysplastic nevi in dysplastic nevus syndrome has been hypothesized. Malignant melanoma is the most common pregnancy-associated malignant neoplasm, responsible for 24-31% of all malignancies diagnosed during pregnancy. Pregnancy-associated melanomas (PAMs) are typically defined as melanoma diagnosed during pregnancy and up to 1 year after delivery. MM is also the most common malignancy to metastasize to the placenta and fetus.

Merkel cell carcinoma (MCC) is an aggressive neuroendocrine tumor associated with a polyomavirus. Two cases of MCC diagnosed during pregnancy resulted in poor fetal and maternal outcomes that are spontaneous abortion, premature labor, and metastatic MCC, causing maternal demise within 2 years.

Dermatofibrosarcoma protuberans (DFSP) is a locally aggressive malignancy that occurs in young and middle-aged adults. Accelerated growth and more aggressive behavior, including fibrosarcomatous changes, may occur during pregnancy. Any woman of childbearing age with a history of DFSP should be counseled regarding the possible propensity for recurrence and aggressive behavior during pregnancy.

Vascular neoplasms, in addition to various physiologic vascular changes such as palmar erythema, spider telangiectasia, gingival hyperemia, and varicosities, occur with greater frequency in pregnancy. Pyogenic granuloma (PG), also referred to as the pregnancy tumor, gingival pregnancy tumor, epulis gravidarum, cutaneous lobular capillary hemangioma, and granuloma gravidarum, is the most commonly reported vascular tumor to arise during pregnancy.

Other tumors reported to occur or change in pregnancy are seborrheic keratoses, dermatosis papulosa nigra, syringomas, poromas, porokeratosis, collagenomas, segmental and plexiform neurofibromas, and Spitz nevi.

Numerous types of cutaneous neoplasms develop or change in pregnancy, but fortunately the majority are benign and inconsequential to fetal and maternal health.



3rd INDERCOS

National Dermatology & Cosmetology Congress with International Participants

14-17 MARCH, 2018
HILTON ISTANBUL BOSPHORUS HOTEL
ISTANBUL, TURKEY

DISTINCT DISEASES IN PREGNANCY

Gudula Kirtschig

The specific dermatoses of pregnancy represent a heterogeneous group of severely pruritic inflammatory dermatoses associated exclusively with pregnancy or the immediate postpartum period, they have been reclassified in 2006: Pemphigoid gestationis, Polymorphic eruption of pregnancy, and Atopic eruption of pregnancy, they have to be differentiated from Intrahepatic cholestasis of pregnancy that shows no specific skin lesions but is intensely pruritic and needs specific treatment. Pemphigoid gestationis is a rare, self-limiting autoimmune bullous disorder of mainly late pregnancy but can occur in any of the three trimesters. Circulating complement fixing IgG antibodies bind to a 180 kDa protein, BP-180 or bullous pemphigoid antigen 2, in the hemidesmosomes of the basement membrane zone of the skin, leading to tissue damage and blister formation. Polymorphic eruption of pregnancy usually affects primigravidas in the last few weeks of pregnancy or immediately post-partum. It occurs in about 1 in 160 to 1 in 200 pregnancies. The pathogenesis of the condition remains unclear, although theories include abdominal distension and hormonal and immunological factors. Polymorphic eruption of pregnancy starts within the striae distensae on the abdomen, with severely pruritic urticarial papules that coalesce into plaques, spreading to the buttocks and proximal thighs and in severe cases becoming generalised. In contrast with pemphigoid gestationis, the umbilical region is usually spared. Atopic eruption of pregnancy describes a disease complex that includes women with a former diagnosis of atopic eczema in pregnancy, prurigo of pregnancy, and pruritic folliculitis of pregnancy. It is the most common dermatosis of pregnancy, accounting for 50% of patients seen in a typical pregnancy skin clinic. It includes eczematous or papular lesions in patients with a history of atopy and usually develops early in gestation, in 75% of cases before the third trimester.

There are physiological changes in pregnancy that are common and most resolve spontaneously after pregnancy. They lead to hyperpigmentation—linea nigra, areolae, melasma, naevi, vulvar melanosis, striae distensae—increased in third trimester, pruritus gravidarum—common in the first and second trimester (affects 1 in 5 women), hair changes—telogen effluvium (post-partum), nail changes—ridging, splitting, distal onycholysis, longitudinal melanonychia, vascular changes—telangectasia, varicosities, pyogenic granulomas, haemangiomas, peripheral oedema, eccrine glands—activity increased (increased sweating), apocrine glands—activity reduced (reduced sweating and apocrine secretion), sebaceous glands—activity increased (in third trimester), immune system—shift from T helper 1 to T helper 2 lymphocyte profile, usually leading to improvement of psoriasis during pregnancy but worsening of atopic dermatitis.

(1) Ambros-Rudolph CM, Müllegger RR, Vaughan-Jones SA, Kerl H, Black MM. The specific dermatoses of pregnancy revisited and reclassified: results of a retrospective two-center study on 505 pregnant patients. *J Am Acad Dermatol* 2006;54:395-404.

(2) Vaughan Jones SA. Chapter 3. Physiologic skin changes of pregnancy. In Black MM, Ambros-Rudolph CM, Edwards L, Lynch P, eds. *Obstetric and gynaecologic dermatology*. 3rd ed. Mosby, 2008:23-30.

(3) <https://www.eadv.org/patient-corner/leaflets>

3rd INDERCOS

National Dermatology & Cosmetology Congress with International Participants

14-17 MARCH, 2018
HILTON ISTANBUL BOSPHORUS HOTEL
ISTANBUL, TURKEY



SAFE DERMATOLOGICAL TREATMENT IN PREGNANCY

Gudula Kirtschig

Treatment for specific dermatoses of pregnancy depends on the stage and severity of the disease and aims to control pruritus and skin lesions. In all cases treatment with corticosteroids, both topically and systemically, and systemic antihistamines can be effective and are relatively safe in pregnancy.

Physiological changes during pregnancy will usually lead to a cosmetically disturbing appearance. However, most of these changes will resolve with time after pregnancy and should not be treated during pregnancy. There are some general rules that are important to consider if treatment during pregnancy is needed: The fetus is most vulnerable with regard to teratogenic damage in week 3 to 8 after conception; all toxic effects must be avoided in this period. If drug treatment is needed, always choose the lowest possible dose and the shortest possible exposure.

For ethical reasons there are not many randomized controlled trials in pregnant women, in particular if drugs are potentially harmful. However, for some medications there is a big collection of data which allows substantial conclusions. Drugs that are regarded safe for use in pregnancy are many topical treatments, however, if the group shows teratogenic effects if applied systemically they should also be avoided topically, e.g. all Vitamin A derivatives. Topical steroids, including very potent ones, are safe if applied for short periods of time to limited areas. Topical steroids, even in higher doses over longer periods of time are preferred to systemic steroids. Antihistamines that have not shown any harm are cetirizine and loratadine. Oral treatment with acyclovir and valacyclovir is safe and indicated in herpes infections. Penicillins, old cephalosporins, e.g. cefalexin, cefalotin, cefuroxime, and with some caution the macrolide antibiotic erythromycin are preferred antibiotics in pregnancy.

Drugs that may be used with good indication are e.g. azathioprine and ciclosporin A; fetotoxicity is shown in animals in high doses; in more than 1000 human pregnancies low birth weight and neonatal immunosuppression was observed that may also be attributed to co-medication or the underlying disease itself, there were no teratogenic effects. If systemic antimycotic treatment is needed amphotericin B is the drug of choice. Biologics are not thought to have a teratogenic effect, however, there is still little experience of their effect on the fetus. They should be stopped for several months before and during pregnancy, however, with good indication e.g. adalimumab, etanercept and ustekinumab may be used in individual cases with close check-ups of the fetus (cave: life vaccines in the newborn may need to be postponed). Drugs that must absolutely be avoided during pregnancy because of a high teratogenic risk are e.g. Vitamin A derivatives, griseofulvin, cyclophosphamide, methotrexate, mycophenolate mofetil, thalidomide, tetracyclines (not if accidentally taken in the first trimester), and topical fluorouracil.

- (1) Chi CC, Kirtschig G, Aberer W, et al. Updated evidence-based (S2e) European Dermatology Forum guideline on topical corticosteroids in pregnancy. *J Eur Acad Dermatol Venereol*. 2017;31:761-773
- (2) Drugs during pregnancy and lactation. Elsevier, 3rd edition, 2015, editors: Schaefer, Peters, Miller
- (3) <https://www.eadv.org/patient-corner/leaflets>



3rd INDERCOS

National Dermatology & Cosmetology Congress with International Participants

14-17 MARCH, 2018
HILTON ISTANBUL BOSPHORUS HOTEL
ISTANBUL, TURKEY

TREATMENT GUIDELINES of HPV INFECTION

Michael Waugh

Prevention. In many countries programmes for HPV preventative vaccination are well established. The main aim is to prevent cancer of the cervix but at the same time condylomata acuminata are prevented and herd immunity is established. Programmes for pre menarche females, then catch up programmes, then young males have been established using bivalent against HPV 16-18, but more often quadrivalent vaccines (Gardasil) against HPV6.11.16.18. "Gardasil 9" in addition is against 31.33.45.52.58. Other sexually transmitted infections must be excluded and syphilis serology should exclude condylomata lata of secondary syphilis.

Every clinician knows that genital warts whatever the treatment have a high recurrence rate whether through relapse or reinfection. Soft warts respond well to podophyllotoxin, sinecatechine and imiquimod (Aldara). Podophyllin must not be used in pregnancy. Keratinised warts may need cryotherapy, trichloroacetic acid, electrocautery, and excision or laser treatment.

FEMALE-PRONE SEXUAL TRANSMITTED SKIN DISEASES

Michael Waugh

Many dermatologic presentations occur in the genital area. It may be difficult for a clinician who is not aware of the patient's sexual risk factors to exclude STDs. Frequent causes of vaginal discharge candidiasis, trichomoniasis, and bacterial vaginosis need to be considered, as well as bacterial infections gonorrhoea and Chlamydia trachomatis. Whilst uncommon lymphogranuloma venereum (LGV) and chancroid are occasionally found. The classical STDs with genital skin manifestations are syphilis in primary and secondary stages; herpes genitalis (if very extensive think of immunosuppression, and HIV), and genital warts. This part of the lesson will try to train the clinician's visual diagnostic criteria.

PREGNANCY AND STD TREATMENTS

Michael Waugh

There are many frequent STD treatments that cannot be used in pregnancy, sulphonamides, trimethoprim, tetracyclines, aminoglycosides, podophyllin, and quinolones. In some of the modern treatments where more sophisticated studies have been made the manufacturers warn caution such as metronidazole, azithromycin, imiquimod, and ketoconazole.

But generally penicillins, including cephalosporins, erythromycin and acyclovir are safe.

3rd INDERCOS

National Dermatology & Cosmetology Congress with International Participants

14-17 MARCH, 2018
HILTON ISTANBUL BOSPHORUS HOTEL
ISTANBUL, TURKEY



HPV RELATED ORAL DISEASES

Soner Uzun

HPV with more than 200 different subtypes may affect not only any skin or genital area but also oral cavity. HPV is one the most common sexually transmitted virus and infection. HPV infections are primarily transmitted through sexual activities, mouth to mouth contact between partners or family members and autoinoculation. Due to different subtypes of HPV, oral papilloma/wart, focal epithelial hyperplasia, dysplastic wart (HIV), verrucous carcinoma and condyloma acuminatum are the most frequent clinical pictures can be developed in the oral cavity mucosa. Histology, electron microscopy and some sophisticated molecular techniques are the tools for laboratory diagnosis of the HPV related disorders of the oral mucosa. Treatments usually include various physical destructive methods.



3rd INDERCOS

National Dermatology & Cosmetology Congress with International Participants

14-17 MARCH, 2018
HILTON ISTANBUL BOSPHORUS HOTEL
ISTANBUL, TURKEY

DERMATOGLYPHICS IN DERMATOLOGY

Piril Etikan

Scientific study of the epidermal ridges and their configuration on the volar aspect of hands, fingers, feet and toes is called dermatoglyphics (DG). Derived from Greek word derma = "skin", and glyph = "carving". The ridges begin to develop at about the 13th week of prenatal life and the pattern formation is completed by the 18th week and remains unchanged. The palmar aspect of the hand has 3 types of glyphs; flexion creases, tension creases and sulci. Three basic types of patterns are found on the finger tips. These are arch, loop, and whorl. The classification of patterns is based on the number of triradii present. A triradius is the meeting place of three systems of ridge whose element lies approximately parallel to one another at this point. Both of autosomal and sex chromosome anomalies, inherited malformations, congenital infections, drugs (Thalidomide), dermatological diseases and dermatosis, other systemic diseases and psychiatric disorders may cause DG abnormalities. DG also plays an important role in genetics and medicine. Race and sex influence DG. In conclusion dermatoglyphic pattern studies in various dermatoses are needed to identify significant association between specific dermatoglyphic patterns and various dermatoses, so that high risk groups are detected and diseases diagnosed earlier.



SPOROTRICHOID PATTERN IN SKIN DISEASE

Ayşe Şermin Filiz

Sporotrichoid pattern skin disease is a group of disease which present with superficial cutaneous and/or subcutaneous lesions spreading along dermal and subcutaneous lymphatics.

The clinical presentation is named "sporotrichoid" because most common cause of this pattern is the infection caused by dimorphic fungus: "Sporothrix schenckii".

Sporotrichoid patterns skin diseases can be simply gathered under two main categories: infectious and non-infectious etiologies.

Most common causes of sporotrichoid infections are *S. schenckii*, *Nocardia brasiliensis*, *Mycobacterium marinum* and *Leishmania*.

Gardening, soil contamination, splinters in history could be suggestive for *Sporothrix schenckii* and *Nocardia*. Aquariums, fish- handling, swimming in oceans, lakes or pools in history could be a clue for *mycobacterium marinum*. Residence in – or travel to endemic areas also can be suggestive for *Leishmania* infections.

Other than this common causes also some infections like tuberculosis, atypical mycobacterial infections, leprosy (sporotrichoid nerve abscess), *Cryptococcus neoformans*, *streptococcus pyogenes*, *staphylococcus aureus*, Cowpox virus can result with sporotrichoid pattern cutaneous lesions.

Exposure history, physical findings, microscopy, fungal, bacterial and viral cultures, tissue biopsies with special stains are diagnostic method of choices for these infectious etiologies.

(Some interesting cases are illustrated with clinical descriptions)

Although most common causes are infectious, there are some rarely reported non-infectious etiologies in sporotrichoid pattern.

Cutaneous T cell and B cell lymphomas are reported in the literature and therefore existence of these cases reinforces the need to include cutaneous lymphoma in the differential diagnosis of nodules spreading in a sporotrichoid pattern.

Calcinosis cutis, granuloma annulare like dermatitis and also tumoral lesions like malignant peripheral nerve sheath tumor are reported in literature. Also cutaneous squamous cell carcinoma metastases to the skin and in transit melanoma metastases should be kept in mind for differential diagnoses.

(Some interesting cases are illustrated with clinical descriptions)



3rd INDERCOS

National Dermatology & Cosmetology Congress with International Participants

14-17 MARCH, 2018
HILTON ISTANBUL BOSPHORUS HOTEL
ISTANBUL, TURKEY

SKIN DISEASES AFFECTING CLEAVAGE LINES

Sümeyle Seda Ertekin

Pattern analysis of skin lesions is very important for differential diagnosis of dermatologic conditions. Three major line patterns exist on the human body: The dermatomes, the nevoid lines of Blaschko and Langer lines of skin tension which is also called as cleavage lines. Cleavage lines were first described by the Austrian anatomist Karl Langer at 1861, though he gave credit to the French surgeon Baron Dupuytren as being the first to recognize the phenomenon. These lines correspond to the direction in which the vector of naturally occurring skin tension is minimal.

Recognizing the pattern of these lines is important for surgical procedures, especially for cosmetic surgery. Because incisions following cleavage lines generally heal better and produce less scarring. Apart from their importance for skin surgery, some dermatologic diseases may have a tendency of following these lines. As thoracodorsal manifestation of this lines constitute a reverse V shape, which resembles a Christmas tree; where the spine serves as the tree's trunk with the cleavage lines outlining its branches. Some skin diseases are described to have this "Christmas Tree" pattern: Pityriasis rosea, stage 2 syphilis, mycosis fungoides, parapsoriasis, Kaposi sarcoma, exanthematic psoriasis, multiple seborrheic keratosis (Leser-Trelat syndrome), dermatosis papulosa nigra and some other diseases occurring as Wolf's isotopic response. Knowing clinical features of these diseases is important for the differential diagnosis of skin lesions following cleavage lines.

3rd INDERCOS

National Dermatology & Cosmetology Congress with International Participants

14-17 MARCH, 2018
HILTON ISTANBUL BOSPHORUS HOTEL
ISTANBUL, TURKEY



WHAT YOUR HANDS SHOW? CHANGES OF HANDS AS CLUES TO DIAGNOSIS

Günter Burg

Many dermatoses or systemic diseases may show changes of the hands and such hand signs can lead to diagnosis. Disorders with hand-signs include collagenoses, metabolic or nutritional disorders including intoxications; moreover infections, genodermatoses, vascular disorders with disturbances of circulation, neuropathies, neoplasias and some more.

In these diseases diagnostic hints of the hands may be early symptoms for sytemic or for cutaneous diseases.



3rd INDERCOS

National Dermatology & Cosmetology Congress with International Participants

14-17 MARCH, 2018
HILTON ISTANBUL BOSPHORUS HOTEL
ISTANBUL, TURKEY

DIFFERENTIAL DIAGNOSIS OF ANNULAR LESIONS

Tuğba Falay Gür

Annular skin lesions are figured lesions described by a ring-like morphology. A wide variety of cutaneous and systemic disorders are displayed with annular skin lesions. The careful assessment of lesion characteristics and accompanying clinical features are worthful for differential diagnosis.

***Lesion characteristics**

Colour: Lesion colour may also be affected by disorder-specific characteristics. Lesions of urticaria have characteristically a pink colour that emerges from the composition of dermal edema and vascular dilation. A dusky red to violaceous color is a common property in lesions of erythema multiforme.

Scale: The presence, absence, and quality of scale are main diagnostic properties for several annular dermatoses. The prototypical annular inflammatory skin lesion with leading scale is the dermatophyte infection. Trailing scale is the most commonly seen in pityriasis rosea and superficial erythema annulare centrifugum.

Vesicles or pustules: Linear IgA dermatosis and subcorneal pustular dermatosis

Purpura: Purpura annularis telangiectodes of Majocchi, acute hemorrhagic edema of infancy, Henoch-Schönlein purpura, traumatic purpura and urticarial vasculitis

***Symptoms:** Most of annular eruptions are either asymptomatic or mildly to moderately itchy. A less commonly observed feature that occurs frequently in urticarial vasculitis is the presence of burnings or painful sensations.

***Lesion progression**

Expanding lesions is noticed in tinea corporis, granuloma annulare, erythema chronicum migrans, erythema annulare centrifugum, serum sickness-like reactions and erythema gyratum repens. Migratory lesions are characteristic of urticaria and erythema marginatum.

***Lesion location:** The location of annular skin lesions can be suggested clues for diagnosis.

Lupus is the most common cause of annular lesions in a **photodistributed** arrangement. Photodistributed annular lesions are also a common demonstration of actinic lichen planus and annular elastolytic giant cell granuloma.

The target or atypical target lesions of erythema multiforme have a preference for the palms, soles and other **acral sites**. The dorsal hands and feet are common sites of granuloma annulare.

Erythema multiforme may involve the **genitals**. Circinate balanitis is described by serpiginous lesions on the glans penis that may take on an arcuate or annular appearance. Annular lichen planus may involve the male genitalia or other body sites. Annular lichenoid dermatitis of youth typically characterized by smooth, annular red plaques on the groin or flanks in young people.

***Febrile patients:** Several diagnoses should be reckoned in febrile patients with annular skin lesions as sweet syndrome, serum sickness-like reaction. Acute hemorrhagic edema of infancy, Kawasaki disease and CANDLE syndrome should also be considered in febrile children.

3rd INDERCOS

National Dermatology & Cosmetology Congress with International Participants

14-17 MARCH, 2018
HILTON ISTANBUL BOSPHORUS HOTEL
ISTANBUL, TURKEY



PHAGEDENIC ULCERS OF SKIN IN DIFFERENTIAL DIAGNOSIS

Esra Koku Aksu

Phagedenic means severe and destructive and the term of phagedenic ulcer was first used in the literature to describe the venereal syphilitic ulcer in 1819. Factors causing phagedenic ulcers can be classified as benign and malignant. Infections and inflammatory diseases are the most common reasons in the benign classification. Bruli ulcer is the most common diagnosis among infectious causes. *Mycobacterium ulcerans* cause Bruli ulcer, leads to ulcers on the extremities. Cases have been reported mainly from Africa, especially and South America, South East Asia and Australia. The mode of transmission is not fully understood, contaminated water exposure, skin trauma, insects and mosquitoes as vectors were blamed although exact mechanism has not been elucidated. Pyoderma gangrenosum is a severe ulcerating inflammatory disease. Ulcer is painful, rapidly progressive with a well defined undermined border heals with cribriform scar. Immunosuppression is the mainstay of treatment. Basal cell carcinoma and squamous cell carcinoma are the most common reasons in malignant diseases, neglected cases can enlarge and lead to large, ulcerated lesions. Microbiological and histopathological examination are important in the differential diagnosis of phagedenic ulcers. Appropriate treatment of infectious agents, wound care is important. Early diagnosis and surgical intervention is especially important in malign diseases.



3rd INDERCOS

National Dermatology & Cosmetology Congress with International Participants

14-17 MARCH, 2018
HILTON ISTANBUL BOSPHORUS HOTEL
ISTANBUL, TURKEY

CHANCERIFORM ULCERS IN DERMATOLOGY

Aslı Erdemir

CHANCERIFORM ULCERS

Chancriform ulcers are defined as ulcers that mimics syphilis chancre. These ulcers are localised especially on the genital mucosa and may be caused by infectious and noninfectious etiologies. Infectious causes are genital herpes virüs infections, syphilis, chancroid, granuloma inguinale, lymphogranuloma venereum, fungal infections and secondary bacterial infections. Noninfectious causes are Behcets syndrome, fixed drug eruptions and sexual trauma.

Infectious Etiologies

Primary syphilis caused by *Treponema pallidum* begins as a red papule or a crusted superficial erosion than it becomes well demarcated, painless ulcer. The base of the ulcer is clean and on palpation it has a cartilage like stiffness. The nonsuppurative lymph nodes can be found one or both side. Untreated chancre tends to heal in 1-4 months.

Chancroid caused by *Haemophilus ducrei* characterized with superficial solitary or multiple ulcers on genitalia and painful inguinal lymph nodes. These ulcers and lymph nodes tend to suppurate. Lesions usually have irregular, punched out or undermined edges.

Genital Herpes is usually caused by *HSV-2*. Grouped vesicles with erythematous base occurs on genitalia then they turn in multiple painful ulcers. The first infection is more severe than secondary episodes. Inguinal lymph nodes can be enlarged on both sides.

Lymphogranuloma Venereum caused by *Chlamydia trachomatis*. It is characterized with small, painless genital papules which tend to ulcerate. Unilateral tender femoral or inguinal lymphadenopathy, rectal bleeding, pain or discharge may be accompanied.

Granuloma Inguinale caused by *Calymmatobacterium granulomatis*. Painless, beefy red papules and ulcers forms the clinic. These lesions are persistent, sometimes sclerotic or necrotic.

Noninfectious Etiologies

Behcets Disease is characterized with aphthous oral ulcers and genital ulcers. Genital ulcers are generally painful and heal with scarring. In male patients the genital ulceration tend to occur on scrotal area, in female patients vagina, cervix and vulva are frequently affected areas.

Fixed Drug Eruption is often begins as a solitary plaque or bulla and frequently located on the lip or genitalia. With time bulla turns to ulceration. First attack of eruption occurs up to 2 weeks after drug exposure. Subsequent exposure to the medication results in reactivation at the same site within 30 minutes to 16 hours.

3rd INDERCOS

National Dermatology & Cosmetology Congress with International Participants

14-17 MARCH, 2018
HILTON ISTANBUL BOSPHORUS HOTEL
ISTANBUL, TURKEY



CHRONIC PARONYCHIA: WHAT'S NEW?

Burhan Engin

Chronic paronychia is an inflammatory disorder affecting the nail fold. The condition is defined as inflammation lasting at least six weeks involving one or more of the three nail folds. It is a common occupational disease, particularly prevalent in housemaids, bartenders, barbers, dishwashers, cooks, food handlers, swimmers and nurses.

Etiology is multifactorial including excessive moisture, contact irritants, contact allergy, food hypersensitivity, trauma and candida hypersensitivity. Contact sensitization to allergens shown by positive patch test reactions is high among patients with chronic paronychia. There is also a higher incidence of prick test reactions to *Candida* allergen proving that hypersensitivity to *Candida* is more important than *Candida* infection in the development of chronic paronychia.

Retinoids (eg, etretinate), epidermal growth factor receptor inhibitors (eg, cetuximab, gefitinib) and protease inhibitors (eg, indinavir, lamivudine) may cause chronic paronychia. Conditions such as diabetes mellitus and immunosuppression also predispose patients to development of chronic paronychia.

Diagnosis of chronic paronychia is based on physical examination of the nail unit. The condition mainly affects adult women and is more commonly seen in the hands than in the feet. Chronic paronychia is characterized by the erythema, edema and tenderness of the nail folds. Induration and rounding off of paronychium along with loss of cuticle is observed. Episodic exacerbations may occur. Nail plate changes are commonly observed in patients with chronic paronychia. Thickening and discoloration of the nail plate, onychomadesis, Beau's lines and pitting can be present.

A clinical staging system has been proposed by Daniel et al in order to have a standardized description of chronic paronychia. According to this classification stage I presents with mild redness and swelling of the nail folds with disruption of the cuticle. In stage II disease redness and swelling of the nail folds is pronounced. Stage III disease is characterized with loss of cuticle, some discomfort and some nail plate changes. In stage IV, symptoms of tenderness and pain are observed along with extensive nail plate changes. Stage V represents acute exacerbation of chronic paronychia.

Management of chronic paronychia consists of general preventive measures, medical management and surgical management. Preventive measures are crucial to help healing and reduce recurrence rates. Medical management consists mainly of anti-inflammatory treatments. In recalcitrant cases not responding to medical treatments and preventive measures various surgical modalities may be used.



3rd INDERCOS

National Dermatology & Cosmetology Congress with International Participants

14-17 MARCH, 2018
HILTON ISTANBUL BOSPHORUS HOTEL
ISTANBUL, TURKEY

WHEN, WHERE AND HOW TO MAKE A BIOPSY?

Günter Burg

When considering clinicopathologic correlations in the diagnostic procedure there basically are various scenarios. The diagnostic impact of histopathology may be high and decisive or moderate and just confirmative; it may be low or even zero and a biopsy is not advisable and dispensable. The site of biopsy must be carefully chosen. Depending on proliferative or inflammatory dermatoses the specimen should be taken from the border or from the center of the lesion, avoiding necrotic areas. An excisional or incisional biopsy is the gold standard. However a punch- or shave biopsy in some cases may be sufficient, provided the relevant changes are shown.

In any case a thorough history, the clinical presentation and the histomorphology are the basic elements for making a proper diagnosis. Nevertheless in a few cases additional special investigations may be helpful. However the high costs of special laboratory tests can be prohibitive.

COSMETIC AND ACADEMIC DERMATOLOGY. TWO SIDES OF ONE COIN

Günter Burg

Dermatology is the only medical discipline which cares not only for the integrity but also for the beauty of its organ; the obvious question however is „what is beauty“?

Both academic and cosmetic aspects are important features of dermatology.

Whereas cosmetology mainly is dealing with the surface of the skin, dermatology more precisely is looking for the pathophysiologic processes from inside of the organ. The goal of 5'000 years of cosmetic skills is natural preservation of youth and beauty as well as artificial makeup, pretending youth and beauty. Academic dermatology in its 200 years old history tends to prophylactically prevent damage and to restore the integrity of diseased skin.

The success rate in cosmetic dermatology is low at very high costs, whereas success usually is good at low costs in academic dermatology, targeting healing of specific dermatoses. The skin is the target for both, cosmetic and dermatologic procedures, which are two sides of one coin and the dermatologist is the specialist to take care for either aspect. However the activities on the cosmetic and the academic side should be well balanced.

3rd INDERCOS

National Dermatology & Cosmetology Congress with International Participants

14-17 MARCH, 2018
HILTON ISTANBUL BOSPHORUS HOTEL
ISTANBUL, TURKEY



SENSITIVE SKIN SYNDROME

Ivana Binic

In recent years, the number of patients with a subjective feeling of discomfort in the skin has increased. They complain about sensitivity when applying conventional cosmetic products, such as creams, soaps, and UV-protection products, with no apparent signs of irritation, contact hypersensitivity or phototoxicity.

It is commonly the condition of the skin that patients diagnose themselves, which later can be worsened in relation to external factors and phenotypic and genotypic characteristics. Clinically subjective symptoms can be very intense, and the objective finding is minimal or missing. To diagnose this condition, a detailed personal and family history and review is needed. Sometimes, it is necessary to do epicutaneous testing to exclude classic contact hypersensitivity.

Patients complain of subjective symptoms such as heat, burning, tingling, or itching. It is always difficult to quantify the intensity and nature of these symptoms, as it can vary greatly from one person to another. Some do not tolerate any skin care product, even the simplest formulation. This feeling of discomfort occurs after the application of any product, the start is usually fast, in a few minutes, but the symptoms may last for several hours. They usually apply constantly new products, but after persisting this subjective irritation, they usually eliminate all cosmetics. This condition lasts for a long time before it becomes permanent, obsessive and / or unbearable for patients.

Objective signs are minimal or absent. Doctors sometimes notice the skin's dryness, erythema or small desquamation. Basically, they are struggling with invisible dermatoses, with no visible signs of irritation or inflammation. Skin hyperreactivity is more common in women and in light-colored skin (phototype 2), although men with a thicker, greasy or dry skin can also complain of intolerance to cosmetic products including products used for and after shaving.

The use of soaps and various preparations for hygiene, preparations with UV protection and chemical exfoliants is not suitable for use in these patients. Also, local trauma, burns or cosmetic procedures such as dermabrasion, laser rejuvenation, or facial tightening procedures may exacerbate this syndrome. Other environmental factors include irritation with light, cold, heat, pollen. Nutrition rich in spices, alcohol, caffeine and hot drinks can also aggravate the condition of the skin. Often these patients are prescribed local corticosteroid preparations which make this skin extremely fragile, which can result in an increasingly intense erythema that soon becomes permanent. A large number of such patients have a skin disease that existed before the onset of a sensitive skin syndrome (rosacea, perioral dermatitis, atopic dermatitis).

In relation to the intensity of symptoms, there are several clinical forms of this syndrome. Treatment of this kind of skin is very difficult for both the doctor and the patient. It is necessary to find products for skin care that do not cause a sense of discomfort during use.



3rd INDERCOS

National Dermatology & Cosmetology Congress with International Participants

14-17 MARCH, 2018
HILTON ISTANBUL BOSPHORUS HOTEL
ISTANBUL, TURKEY

PERCUTANEOUS COLLAGEN INDUCTION THERAPY IN AESTHETIC DERMATOLOGY

Ivana Binic

As the demand for less invasive, highly effective cosmetic procedures grows, dermatologist and other doctors who deal with aesthetic problems, must explore and develop new treatment options. Collagen induction therapy or percutaneous collagen induction (PCI), or microneedling is now a well documented treatment option for skin rejuvenation, and in atrophic acne scars. The therapeutic indications for this treatment option have increased over the last few years and now include transdermal drug delivery, treatment of periorbital melanosis, actinic keratosis and varicella scars. Previously used on its own, it is now increasingly combined with other therapeutic modalities to obtain better results.

Microneedling relies on the principle of neocollagenesis and neovascularisation that occurs as a result of the release of growth factors following needle piercing of the stratum corneum. These growth factors are believed to be responsible for the beneficial effects of the procedure in the treatment of scars and photoageing.

Two hypotheses have been proposed to explain the mechanism of action of microneedling: 1. Formation of microchannels with resultant healing response. These microchannels create a confluent zone of superficial bleeding that acts as a powerful stimulus for the release of various growth factors such as platelet derived growth factor (PGF), transforming growth factor alpha and beta (TGF α and TGF β), and fibroblast growth factor (FGF), which initiate the normal process of wound healing by stimulating the migration and proliferation of fibroblasts that promote collagen deposition. 2. Production of a demarcation current: it has been hypothesised that when the microneedles penetrate the skin, a demarcation current is produced among cells rather than wounds. It is the demarcation current that triggers a cascade of growth factors that stimulate the healing phase.

Microneedling leads to reorganization of old collagen fibres and laying down of new collagen, elastin, and capillaries leading to the effect of skin tightening. A significant increase in level of collagen type I, III, and VII, newly synthesized collagen and tropoelastin from baseline was observed after multiple microneedling sessions. This percutaneous collagen induction leads to an overall youthful appearance of the skin by reducing fine lines and wrinkles, reducing pore size, more suppleness, and elasticity.

Percutaneous collagen induction or skin microneedling is minimally invasive technique that leads to rejuvenation with regeneration of the skin along with increased collagen production and proved to be an effective aesthetic treatment for numerous indications. However, multiple sessions are usually needed to maintain the improvement achieved.

3rd INDERCOS

National Dermatology & Cosmetology Congress with International Participants

14-17 MARCH, 2018
HILTON ISTANBUL BOSPHORUS HOTEL
ISTANBUL, TURKEY



INTRALESIONAL TREATMENTS IN DERMATOLOGY

Mustafa Tunca

Since skin is an easily accessible organ, intralesional treatments, which means direct delivery of medication percutaneously into skin lesions is an important part of dermatologic practice. Intralesional treatment has numerous advantages. It enables higher drug concentrations inside the lesions without significant systemic effects. You get rapid, and prolonged effect, since the skin serves as a reservoir, allowing medication deposited in the dermis to be delivered over a period of time. It is easily performed, and is relatively safe. Disadvantages are quite few; as an office-based treatment, you need a suitable injection area, a needle, and there may be minor local injection-site side effects.

Today there are many drugs that are suitable for intralesional injections, and they are used for a wide range of skin diseases. Common indications for intralesional treatment include acne, hidradenitis suppurativa, alopecia, keloid and hypertrophic scar, leishmania, and verruca. Not so common indications are non-melanoma skin cancer, kaposi sarcoma, hemangioma and vascular malformations, lymphoma, melanoma, immunobullous diseases, and psoriasis.

Intralesional injections in dermatology start with using steroids for this purpose. In acne triamcinolone acetonide (TA) is the option for nodules and cysts. There are two options for alopecia areata; several doses of either TA or betamethasone dipropionate. TA may also be used for cicatricial alopecia.

For keloid and hypertrophic scars, there are many options; TA, 5-fluorouracil, bleomycin, botulinum toxin, tamoxifen.

In cutaneous leishmaniasis amphotericin B, meglumine antimonate, sodium stibogluconate, hypertonic 10% sodium chloride, and pentamidine may be used intralesionally.

Intralesional verruca treatment also has lots of options; PPD, BCG, candida antigen, MMR vaccine, *Mycobacterium indicus pranii* vaccine are immunotherapy options, bleomycin, 5-FU, cidofovir and VitD3 are other options which have been reported effective.

Infantile hemangiomas and vascular malformations in adults may also be treated with intralesional injections of corticosteroids and bleomycin respectively.

Intralesional therapy for NMSC is a remarkable option. For this purpose, interferons, 5-FU, methotrexate (Mtx), and bleomycin may be used. Kaposi sarcoma may respond to intralesional vincristine, vinblastine, doxorubicin, 3% sodium tetradecyl sulfate, and interferon α .

Cutaneous lesions of lymphoma, metastatic melanoma, refractory lesions of pemphigus, mucous membrane pemphigoid, psoriasis, and erosive oral or nail lichen planus may also be treated with intralesional injections of different agents.

In conclusion, intralesional injection of drugs is an effective and safe option in a wide range of skin diseases and it is an essential part of dermatological practice.



3rd Indercos

National Dermatology & Cosmetology Congress with International Participants

14-17 MARCH, 2018
HILTON ISTANBUL BOSPHORUS HOTEL
ISTANBUL, TURKEY

TRICHLOROACETIC ACID, PHENOL AND SODIUM HYDROXIDE USES IN DERMATOLOGY

Fatma Pelin Cengiz

Sodium hydroxide, is one of the most widely used caustic agents in industry. Medically, it has been used externally to remove diseased or dead tissues and destroy warts and small tumors. Sodium hydroxide causes liquefaction necrosis. Its effect is terminated by neutralization with acetic acid. It heals more rapidly than coagulation necrosis. Sodium hydroxide matricectomy is reported only in a few studies.

Phenol, a mono-phenyl ring bonded to a hydroxyl group, is the most important representative of the phenolic compounds. Phenol is an antiseptic agent. It is usually used as a disinfectant, depending on the bacteria and duration of exposure. Phenol denatures the activity of protein. It is also considered a kerato-coagulant agent at a concentration of 88 % with similar effects to a 70 % trichloroacetic acid (TCA) peel, or CO2 nonfractional laser. Nonetheless, its skin penetration can be decreased by alcohol; for example, applying polyethylene glycol 400, or 70 % isopropanol diluted with water. Skin treated with topical application of phenol presents with immediate vascular coagulation, keratin epidermal coagulation, and injury to the upper reticular dermis. In addition, phenol decreases melanogenesis, as a peroxidase inhibitor, reducing the polymerization of melanogenic intermediates and decreasing melanocyte proliferation.

Trichloroacetic acid (TCA; also known as trichloroethanoic acid) is an analogue of acetic acid in which the three hydrogen atoms of the methyl group have all been replaced by chlorine atoms. TCA is a caustic chemical agent that causes coagulation necrosis, like phenol. It produces epidermal and dermal necrosis and then neutralizes by itself without serious systemic toxicity. It is used for superficial or medium-depth peeling, in which it penetrates the epidermis and papillary dermis with subsequent regeneration of the skin.

Herein, we aimed to summarize trichloroacetic acid, phenol and sodium hydroxide uses in dermatology.

3rd INDERCOS

National Dermatology & Cosmetology Congress with International Participants

14-17 MARCH, 2018
HILTON ISTANBUL BOSPHORUS HOTEL
ISTANBUL, TURKEY



BIOENGINEERING OF HUMAN SKIN SUBSTITUTES

Maja Hofmann

The skin plays a crucial role in protecting the body from the external environment. The structure of the skin, comprising of the epidermis, dermis and subcutis is integral to its function. Skin replacement has been a long interesting goal for modern medicine; from pioneering work using “fresh skin” allografts, to the biologic materials currently in use. Tissue-engineered skin substitutes represent an innovative therapeutical option for the treatment of acute and chronic skin wounds. Different option for bioengineering are currently used or are under investigation. One option are biomaterials which can be used as skin substitute. Biomaterials are acellular natural or synthetic substances used for creation of skin substitutes in clinical applications. Another bioengineering option are epidermal substitutes. Epidermal grafts consist of keratinocytes that are differentiated in vitro building a stratified epidermal layer. Dermal substitutes are also available. Mainly, they are created with or without a temporary synthetic epidermis. A further bioengineering technology are the composite substitutes, which are defined by epidermal cells growing on fibroblast-containing dermal substitutes. The use of stem cells as the basic material for skin engineering offers the potential to improve significantly the clinical outcome, both in wound healing and in gene therapeutic approaches. Bioprinting is involving the use of computer-controlled deposition of cells into precise 3-dimensional (3D) geometrical patterns. It has shown promise in accurate delivery of cells to replicate natural skin anisotropy rather than traditional low precision cell spraying and seeding techniques. In the future perspective, the tissue-engineered skin will resemble morphologically and functionally natural skin.



3rd INDERCOS

National Dermatology & Cosmetology Congress with International Participants

14-17 MARCH, 2018
HILTON ISTANBUL BOSPHORUS HOTEL
ISTANBUL, TURKEY

IFN-TREATMENT: DOES IT WORK IN DERMATOLOGY?

Maja Hofmann

Interferons (IFNs) are polypeptides produced by stimulated eukaryotic cells and naturally occur in the human body as a part of the innate immune response. The family of interferons mediates a broad spectrum of potent antiviral, antiproliferative, apoptosis-inducing, anti-angiogenic and immunomodulatory effects. The antitumor activity appear to be due to a combination of direct antiproliferative, as well as indirect immune-mediated, effects. Three different types of human IFN (IFN alpha, IFN beta, and IFN gamma) are widely used for the treatment of various diseases due to their immunomodulating, antiviral and antiproliferative properties. IFN-alpha is predominantly used, as there are the most published data. IFN- alpha possesses pleiotropic and potentially antagonistic activity in immune cells and tumors. Cytokines play an important role as mediators or regulators of tumor-host interactions during progression of malignant tumors. To date, the cytokine network induced by IFN-alpha has not been fully elucidated. Clinical activity of IFN-alpha is not only mediated by direct anti-proliferative effects, but also mediated by induction or modulation of secondary cytokines such as IL-2, IL-10 or TNF. INF-alpha is mostly applied subcutaneously, but also intravenous or intralesional treatments are described. In dermatology, IFN-treatment is used in dermatooncology, especially in the treatment of melanoma patients in the adjuvant setting as well as in cutaneous T-cell lymphoma patients and in patients with Kaposi sarcoma. Also in the treatment of viral diseases, like genito- or anal warts, IFN-alpha has been published to be effective. One major problem in IFN-alpha therapy are the side effects, which will often lead to stop therapy. In conclusion, the role of IFN-alpha in dermatology is still existing, but new treatment options especially in the adjuvant setting of melanoma are in the pipeline and perhaps the role of IFN-alpha has to be new determined.

3rd INDERCOS

National Dermatology & Cosmetology Congress with International Participants

14-17 MARCH, 2018
HILTON ISTANBUL BOSPHORUS HOTEL
ISTANBUL, TURKEY



TOPICAL IMIQUIMOD

Zoran Nedic

Imiquimod is topical immunomodulator. Its belongs to the imidazoquinoline class of immune response modifiers. Mechanism of action is unclear. It is believed that imiquimod, by binding to membrane toll-like receptors, activates macrophages that produce cytokines and then activates immune cells.

Due to its unique mode of action, it is used for therapy of some antiviral and antitumor disease of the skin: Condyloma acuminatum, Actinic Keratosis and Basal Cell Carcinoma. First time described in therapy 1997.

Each patients poses a unique clinical problem. The therapy should be tailored to each patient individually, taking into account the type of skin disease, including the number and distribution of changes, the lesion morphology and the possibility of application by the patients.

Based on these facts, we recommend the use of imiquimods, the frequency of application, and the duration of therapy.

During the use of imiquimod, local and sometimes systemic adverse reactions may occur.

Numerous clinical studies have confirmed the efficacy of imiquimod.

The use of imiquimod should be tried in all cases, wherever possible, before any other therapy, destructive or excision.



3rd INDERCOS

National Dermatology & Cosmetology Congress with International Participants

14-17 MARCH, 2018
HILTON ISTANBUL BOSPHORUS HOTEL
ISTANBUL, TURKEY

INNOVATIVE USE OF VITAMIN D

Habibullah Aktaş

Vitamin D is an essential steroid hormone for human body. While its main function is to regulate calcium homeostasis, it has also so many actions in the tissues such as cell proliferation, differentiation, immunomodulation and regulation of inflammation. These properties make vitamin D a substantial treatment tool in several medical conditions including dermatological disorders.

Oral vitamin D has been used as a systemic option in psoriasis treatments for years. More popularly in dermatology, topical synthetic vitamin D derivative, calcipotriol, became a good choice in topical treatment of psoriasis as a great steroid-sparing alternative. With the discovery of other actions of vitamin D, several dermatological diseases were treated successfully with vitamin D, either systemically or topically.

Apart from psoriasis, systemic vitamin D treatment has been found to be effective in non-scarring alopecia, vitiligo, sunburn and cutaneous malignant melanoma.

More recently, intralesional vitamin D administration was reported to be successful in recalcitrant warts in preliminary studies.

Topical synthetic vitamin D, calcipotriol, is effective in cutaneous warts, vitiligo, alopecia areata, seborrheic keratosis, actinic keratosis, epidermal nevus, discoid lupus erythematosus, morphea, radiation dermatitis, some benign skin tumours, palmar and plantar hypokeratosis, granuloma annulare, lichen sclerosis et atrophicus, erythrokeratoderma, ichthyosis, palmoplantar pustulosis, pityriasis rubra pilaris, grover disease, porokeratosis, hailey-hailey disease, acanthosis nigricans and wound healing.

Since long-term use of calcipotriol is considered safe unlike topical steroids, it is a great weapon in the hands of dermatologists for the treatment of various dermatosis.

3rd INDERCOS

National Dermatology & Cosmetology Congress with International Participants

14-17 MARCH, 2018
HILTON ISTANBUL BOSPHORUS HOTEL
ISTANBUL, TURKEY



PLACEBO & NOCEBO

Ilknur K. Altunay

Placebo and nocebo are psychobiological phenomena attributable to overall therapeutic context, occurring in the patients' brain following the administration of inert substances. While placebo is associated with positive effects of such inert substances, nocebo means negative adverse events.

Placebo effect has been well-known for a long time, whereas much less is known about nocebo effect which is negative counterpart of the first one. Although psychological and neurobiological mechanisms for both events include expectancies, conditioning, learning, memory, motivation, reward, somatic focus, anxiety, etc.; two principal processes are expectancy and classical conditioning. In recent years, neuroimaging techniques and biochemical measurements of neurochemical substances have increased our knowledge on the central nervous system, and thus on potential psychological /neurobiological mechanisms of placebo and nocebo effects. The interconnectedness of psychological and physiological drivers of these responses is a core feature. Yet, more research is needed to fully understand the roots of the phenomena.

Placebo and nocebo phenomena have been studied in several fields of the medicine such as neurology, psychiatry, gastroenterology and recently dermatology. Especially pain, depression and itch have been the main focus of interest in researches. Itch is the most common symptom of dermatological disorders and highly susceptible to both effects. Experimental and clinical studies show the importance of these effects in itch treatments and also offer possible mechanisms for itch sensitization in patients with chronic itch.

Dermatologists should be aware of placebo and nocebo effects. It should be considered that some contextual elements of medical practice such as environmental factors, personality traits and doctor-patient relationship modulate clinical outcomes. This is critically important regarding treatment adherence, the experience of adverse effects and the efficacy of possible therapies.

LITERATURES

- 1-Napadow V, Li A, Loggia M, Kim J, Mawla I, Gaëlle D et al. Placebo and nocebo effects: itch, mechanisms, and predictors. *Eur J Pain* 2016;20: 8-13
- 2-The imagined itch. Brain circuitry supporting nocebo-induced itch in atopic dermatitis patients *Allergy* 2015;70:1485-1492
- 3-A review of the Theoretical and biological understanding of the nocebo and placebo phenomena. *Clin Ther* 2017; 39:469-76
- 4-Misery L, Carre JL. Placebo and nocebo effects as major components of the treatment of itch. *Exp Dermatol*. 2017 Jan;26(1):24-25.



OMALIZUMAB TREATMENT IN CHRONIC SPONTANEOUS URTICARIA

Andrew Finlay

These are exciting times in the management of urticaria with the introduction of a powerful new biologic, omalizumab. Chronic spontaneous urticaria (CSU) has a major impact on quality of life (QoL). The severe itching is a burden in itself, but this also results in difficulty sleeping, chronic fatigue, impairment of physical and emotional well-being, work productivity and social functioning. These impacts are of great importance to a patient and add to the justification of the proposal for the new word "quimp" meaning "quality of life impairment" (1).

There are several ways to assess the impact of urticaria. Quality of life measures include the general dermatology measure, the Dermatology Life Quality Index (DLQI), and the urticarial specific measure, the Chronic Urticaria Quality of Life Questionnaire (CU-QoL). There is also a daily diary method of recording daily urticaria signs and symptoms, the Urticaria Activity Score (UAS7). When these were compared using data from several studies of omalizumab in CSU, there was a near-perfect association between changes in signs and symptoms and changes in dermatologic and urticaria-specific QoL measures (2). So it is reassuring to understand that all of these measures are able to similarly identify change.

DLQI scores were recorded in three large studies using omalizumab in CSU (Finlay 2017). When interpreting results from such studies it is not enough to know the statistical significance of change, it is arguably even more important to be able to interpret whether such change is of clinical importance to the patient. The concept of Minimal Clinical Important Difference (MCID) should be applied: for the DLQI the MCID is a score change of 4.

Omalizumab 300 mg/day significantly improved total DLQI scores vs. placebo (3). A shift from high disease impact on life at baseline towards less impact at week 12 was seen with omalizumab 300 mg vs. placebo ($P < 0.001$; all studies). The proportion of patients where change in mean total DLQI score from baseline to week 12 reached an MCID of ≥ 4 was 74.1%, 76.0% and 77.2% in three major studies ($p < 0.01$; all studies).

These data have added to the research evidence that the DLQI is a useful and appropriate tool to use in the assessment of urticaria. Further DLQI developments that may be of value in the management of urticaria include its potential use for triaging patients for therapy, and its validation when completed in e-format such as an iPad.

1. Finlay AY. Quimp: a word meaning "quality of life impairment". *Acta Derm Venereol* 2017; 97: 546-547.
2. Stull DE, McBride M, Houghton K, Finlay AY et al. Assessing Changes in Chronic Spontaneous/Idiopathic Urticaria: Comparisons of Patient-Reported Outcomes Using Latent Growth Modeling. *Advances in Therapy* 2016; 33: 214-224.
3. Finlay AY, Kaplan AP, Beck LA et al. Omalizumab substantially improves dermatology-related quality of life in patients with chronic spontaneous urticaria. *J Eur Acad Dermatol Venereol*. 2017;31:1715-1721.



TRICHOTILLOMANIA: NEW TREATMENT APPROACHES

Pelin Üstüner

Trichotillomania; is a behavioral disorder of recurring habit of pulling one's own hair classified previously as an impulse control disorder (ICD) by DSM-IV that results in secondary alopecia, distress, and social or functional impairment (1). Abnormalities in neurotransmitter system such as serotonin, dopamine, norepinephrine, glutamate have been shown as a trigger (2).

Nowadays the most common and first step treatments recommended in trichotillomania are psychological treatments including Habit reversal training (HRT), Cognitive behavioral therapy (CBT) and acceptance and commitment therapy (3). In HRT patients learn how to recognize situations (impulses) where they are likely to pull their hair and how to substitute other behaviors instead (redirect impulses) (3). Cognitive behavioral therapy (CBT) helps patients to identify and examine distorted beliefs they may have in relation to hair pulling (3). For mild disease, strategies that make hair pulling harder may be employed (e.g. placing bandages on fingers, wearing gloves, and putting on a hat) (3). In comparisons of behavioral versus pharmacologic treatment, CBT (including HRT) have shown significant improvement over medication alone (4).

Pharmacological treatment of trichotillomania includes basically tricyclic anti-depressants (TCAs), Selective serotonin reuptake inhibitors (SSRIs), dopaminergic atypical anti-psychotic drugs such as olanzapine (1,4,5). Besides an anti-convulsants or anti-epileptics like clonazepam, topiramate and mood stabilizers such as oxcarbazepine and lamotrigine have been reported in case series as treatment alternatives with variable results (6,7).

N-acetylcysteine (NAC), an amino acid, seems to restore the extracellular glutamate concentration in the nucleus accumbens (8). NAC shows benefits beyond being a precursor to the anti-oxidant, glutathione, modulating glutamatergic, neurotropic and inflammatory pathways (8). The use of NAC in disorders including addiction, compulsive and grooming disorders, schizophrenia and bipolar disorder have already been reported (9). As impulsivity and dysfunctional reward pathways occur in both trichotillomania and addictive disorders, the use of opioid antagonists has also been tried in trichotillomania. In a previous double-blind, placebo-controlled trial including 50 patients NAC was given in a dose of 1200 mg/day or placebo for 6 weeks, followed by a further 6 weeks of 2400 mg of NAC or placebo (10). Overall, NAC seemed to be efficacious in the treatment of trichotillomania with the treatment response seen first at week 9 (10). Promising preliminary results were seen in trichotillomania and also in other grooming disorders, including nail biting and skin picking (10-13). However, pharmacological interventions demonstrated that NAC is not effective in children as seen in adults with trichotillomania (14). Behavioral therapy before initiating pharmacological interventions has been recommended, as behavioral therapy has demonstrated efficacy in both children and adults with trichotillomania (3,4). Besides, in 6 randomized controlled studies an opioid antagonist naltrexone has been shown to be statistically significantly beneficial for trichotillomania symptoms as a broadly defined behavioral addiction (15). However, higher doses than 50 mg/day of naltrexone is believed to be needed to inhibit the μ receptors in the brain and peripheral nervous system that are responsible for impulsivity. Moreover, a cannabinoid agonist "dronabinol" commonly used to treat unresponsive nausea and vomiting after chemotherapy has been found to provide statistically significant reductions in trichotillomania symptoms, in the absence of negative cognitive effects in a previous pilot study in 2011 (16).



3rd INDERCOS

National Dermatology & Cosmetology Congress with International Participants

14-17 MARCH, 2018
HILTON ISTANBUL BOSPHORUS HOTEL
ISTANBUL, TURKEY

As a conclusion, the most promising results have been evident when CBT and opioid antagonist pharmacotherapy were implemented in trichotillomania. Naltrexone as a μ receptor antagonist via reducing impulsivity may be effective against broadly defined behavioral addictions such as trichotillomania and substance addiction disorders. The hypothesis of dopamine, glutamate or gamma-aminobutyric acid in trichotillomania underlined the use of mood stabilizers, anti-psychotic and dopamine related drugs. Large trials are required to expand on the preliminary evidence available for NAC, olanzapine and dronabinol.

References

- 1) Woods DW, Houghton DC. Diagnosis, evaluation, and management of trichotillomania. *Psychiatr Clin North Am.* 2014;37(3):301-17.
- 2) Twohig MP, Woods DW. A preliminary investigation of acceptance and commitment therapy and habit reversal as a treatment for trichotillomania. *Behavior Therapy.* 2004; 35,803-820.
- 3) Bloch MH, Landeros-Weisenberger A, Dombrowski P, Kelmendi B, Wegner R, Nudel J, Pittenger C, Leckman JF, Coric V. Systematic review: pharmacological and behavioral treatment for trichotillomania. *Biol Psychiatry.* 2007 Oct 15;62(8):839-46.
- 4) Ninan PT, Rothbaum BO, Marsteller FA, Knight BT, Eccard MB. A placebo-controlled trial of cognitive-behavioral therapy and clomipramine in trichotillomania. *J Clin Psychiatry.* 2000;61(1):47-50.
- 5) Van Ameringen M, Mancini C, Patterson B, Bennett M, Oakman J. A randomized, double-blind, placebo-controlled trial of olanzapine in the treatment of trichotillomania. *J Clin Psychiatry.* 2010;71(10):1336-43.
- 6) Virit O, Selek S, Savas HA, Kokaçya H. Improvement of restless legs syndrome and trichotillomania with aripiprazole. *J Clin Pharm Ther.* 2009;34(6):723-5.
- 7) Leombruni P, Gastaldi F. Oxcarbazepine for the treatment of trichotillomania. *Clin Neuropharmacol.* 2010;33(2):107-8.
- 8) Dean O, Giorlando F, Berk M. N-acetylcysteine in psychiatry: current therapeutic evidence and potential mechanisms of action. *J Psychiatry Neurosci.* 2011;36(2):78-86.
- 9) Lafleur DL, Pittenger C, Kelmendi B, Gardner T, Wasylinski S, Malison RT, Sanacora G, Krystal JH, Coric V. N-acetylcysteine augmentation in serotonin reuptake inhibitor refractory obsessive-compulsive disorder. *Psychopharmacology (Berl).* 2006;184(2):254-6.
- 10) Grant JE, Odlaug BL, Kim SW. N-acetylcysteine, a glutamate modulator, in the treatment of trichotillomania: a double-blind, placebo-controlled study. *Arch Gen Psychiatry.* 2009;66(7):756-63.
- 11) Barroso LAL, Sternberg F, Souza MNIFE, Nunes GJB. Trichotillomania: a good response to treatment with N-acetylcysteine. *An Bras Dermatol.* 2017;92(4):537-539.
- 12) Odlaug BL, Grant JE. N-acetyl cysteine in the treatment of grooming disorders. *J Clin Psychopharmacol.* 2007;27(2):227-9.
- 13) Berk M, Jeavons S, Dean OM, Dodd S, Moss K, Gama CS, Malhi GS. Nail-biting stuff? The effect of N-acetyl cysteine on nail-biting. *CNS Spectr.* 2009;14(7):357-60.
- 14) Bloch MH, Panza KE, Grant JE, Pittenger C, Leckman JF. N-Acetylcysteine in the treatment of pediatric trichotillomania: a randomized, double-blind, placebo-controlled add-on trial. *J Am Acad Child Adolesc Psychiatry.* 2013;52(3):231-40.
- 15) Mouaffak F, Leite C, Hamzaoui S, Benyamina A, Laqueille X, Kebir O. Naltrexone in the Treatment of Broadly Defined Behavioral Addictions: A Review and Meta-Analysis of Randomized Controlled Trials. *Eur Addict Res.* 2017;23(4):204-210.
- 16) Grant JE, Odlaug BL, Chamberlain SR, Kim SW. Dronabinol, a cannabinoid agonist, reduces hair pulling in trichotillomania: a pilot study. *Psychopharmacology (Berl).* 2011;218(3):493-502.

3rd INDERCOS

National Dermatology & Cosmetology Congress with International Participants

14-17 MARCH, 2018
HILTON ISTANBUL BOSPHORUS HOTEL
ISTANBUL, TURKEY



THE IMPORTANCE OF ORNITHINE DECARBOXYLASE IN DERMATOLOGY

Hilal Kaya Erdoğan

Ornithine decarboxylase (ODC) is the rate-limiting enzyme in the polyamine biosynthesis. It plays an important role in both normal cellular proliferation and the growth and development of tumors. The ODC amount is altered in response to many factors such as growth factors, oncogenes, tumor promoters and changes in polyamine levels. Polyamines are essential cell components for normal cellular functions and growth. Increases in activity of cutaneous ODC have been found to correlate with the administration of growth-promoting stimuli such as hair plucking, tumor promotion, and wounding. Experimentally it was shown that ODC levels increase in skin tumors, benign epidermal proliferative diseases such as psoriasis and response to injury, ultraviolet radiation, tumor-promoting agents.

Various drugs and chemicals have been shown to inhibit ODC activity. Some of these are retinoids, nitrofurazone, cyclosporine, cimetidine, curcumin, rapamycin, diclofenac, nitric oxide, resveratrol, agmatine (decarboxylated arginine), deguelin, apigenin and ginseng. These chemicals have remained in the experimental phase; none are used in routine clinical settings.

Difluoromethylornithine (DFMO, eflornithine) is a specific irreversible inhibitor of ODC and it was shown to inhibit development of the tumors. It was synthesized as an anti-cancer drug in 1970. Although there have been many studies concerning the effects of eflornithine on cancer prevention and treatment; its not used routinely for this indication. Phase 3 studies for the chemoprevention for non-melanoma skin cancers have been completed. Furthermore it was used in the treatment of African sleeping sickness and hair loss was seen as a side effect. On the other hand, topical eflornithine hydrochloride (13.9%) was approved by the Food and Drug Administration in July 2000 to treat facial hirsutism. Application of topical eflornithine twice daily for 8 weeks has been found to be effective and safe for reduction of the growth of unwanted facial hairs. Although systemic DFMO is associated with reversible ototoxicity at high doses; topical DFMO has shown no adverse effects. It also can be combined with mechanical hair removal methods such as shaving, plucking and laser epilation.

Studies on new inhibitors of ODC which are less toxic and more potent than eflornithine for suppression of skin and colon carcinogenesis are still proceeding. In the near future, ODC inhibitors seem to be used more frequently in the treatment of facial hirsutism and in the prevention and treatment of nonmelanoma skin cancers.



3rd INDERCOS

National Dermatology & Cosmetology Congress with International Participants

14-17 MARCH, 2018
HILTON ISTANBUL BOSPHORUS HOTEL
ISTANBUL, TURKEY

DEPOT-PENICILLIN IN DERMATOLOGY

Pinar Incel Uysal

Penicillins which belong to the beta lactam antibiotic group are extremely effective and are still commonly used. Beta lactam drugs mainly damage bacterial cell wall. Chemically, penicillins consist of two structures: nucleus and the side chain (R). Many of the antibacterial and pharmacological characteristics of penicillins are determined the side chain which is benzyl in natural penicillin (penicillin G). Among all the penicillins, penicillin G (benzylpenicillin) has the greatest antimicrobial activity. Depot-penicillins (benzathine penicillin and procaine penicillin) are salts with low solubility which occur as a result of interacting with amines. These are administered by intramuscular injection. Penicillin releases slowly and thus, long term effects of the drug are provided. The depot-penicillin G preparations are prescribed as a single daily, weekly, or monthly dose. The approximate dose for these long-acting penicillins is 1.2–2.4 million units.

Long acting penicillins are mainly used for the treatment of syphilis in dermatology. For patients without neurosyphilis, the appropriate formulation of parenteral penicillin is benzathine penicillin G (BPG). A single dose of 2.4 million unit benzathine penicillin intramuscularly (IM) is the standard therapy for most patients with primary, secondary and early latent syphilis. For patients with tertiary or late latent syphilis without evidence of neurosyphilis, benzathine penicillin 2.4 million units should be given intramuscularly once weekly for three weeks. Endemic treponemal diseases including pinta, yaws and bejel should be treated with a single dose of 0,6 million (in patients under the age of 10) and 1.2 million (in patients aged 10 or over) units of benzathine penicillin. IM administration of benzathine penicillin produces detectable serum concentrations for 30 days.

In the literature there are few studies addressing the prophylactic effects of penicillins in prevention of recurrence of erysipelas or cellulitis. BPG 1.2 million units once every 3 week has been shown to be effective and well tolerated prophylaxis of recurrent erysipelas. Clinical studies have revealed the efficacy of penicillin G in dermal fibrosis. Thus it has been used to treat circumscribed scleroderma. Also, for many years, nonspecific actions of penicillin G have been utilized in other dermatological conditions such as pityriasis rubra pilaris, lichen sclerosus, mucocutaneous symptoms of Behçet's disease, erythema nodosum.

The penicillins are completely safe in pregnancy. However, all penicillins may cause penicillin allergy, neuro- and nephrotoxicity, and uncommon hematologic toxicity. The most serious of hypersensitivity reactions are anaphylaxis and angioedema that occurs immediately after application (in less than 30 minutes) and are mediated by IgE. The incidence of anaphylaxis is about 0.01%. Parenteral administration appears the most likely route inducing anaphylaxis in humans. After IM injection of depot preparations, occasionally the medication enters an artery and induces arteriospasm which may lead ischemic necrosis of the overlying skin. This condition also known as Nicolau syndrome. Sometimes injection may cause nerve damage and paralysis. In addition, immediate non-allergic reactions (pseudoanaphylactic reactions) known as Hoigne syndrome may develop as a result of drug entry into the venous system.

3rd INDERCOS

National Dermatology & Cosmetology Congress with International Participants

14-17 MARCH, 2018
HILTON ISTANBUL BOSPHORUS HOTEL
ISTANBUL, TURKEY



THE ROLE OF CAPSAICIN IN DERMATOLOGY

Şule Güngör

Introduction

•Capsaicin (8-methyl-N-vanillyl-6-nonenamide), is a lipophilic alkaloid found in hot red chili peppers of the genus *Capsicum* (hot chili peppers).

Mechanism of action

- Topical capsaicin acts through transient receptor potential vanilloid 1 (TRPV1) expressed on sensory skin nerves to release neuropeptides such as substance P.
- Substance P is a chemical mediator of pain impulses along the central nervous system
- TRPV1 recently has been implicated in the pathogenesis of pruritus and thus may be the target through which capsaicin exerts its antipruritic effect.

Indications of topical capsaicin: Uremic pruritus, notalgia paraesthetica, brachioradial pruritus, post-herpetic neuralgia, burning mouth syndrome, lichen simplex chronicus, prurigo nodularis, uremic pruritus, aquagenic pruritus, idiopathic pruritus, perianal pruritus, psoriasis, diabetic neuropathy, oral neuropathic pain, trigeminal neuralgia, reflex sympathetic dystrophy, HIV-related neuropathy
Topically capsaicin is available as a cream, concentrations ranging from 0.025% to 0.75%, or as a patch, concentration 8%.

Capsaicin and carcinogenesis: There are conflicting studies and results about the carcinogenic effect of capsaicin. There are different pathways showing cocarcinogenic or anticarcinogenic effects. Capsaicin acts as an anticarcinogen by inhibiting cell growth, invasion and angiogenesis; and by inducing apoptosis.

The cocarcinogenic effect of capsaicin is mediated through the TRPV1 and tyrosine kinase epidermal growth factor receptor (EGFR). The absence of TRPV1 in mice resulted in a striking increase in skin carcinogenesis. The chronic blockade of TRPV1 might increase the risk for skin cancer development.

Pregnancy category C

Side effects

*Feeling of warmth and stinging, or a sensation of burning after application

- This sensation is related to the action of capsaicin on the skin and is to be expected.
- Approximately 50% of patients will experience some mild to moderate stinging or burning.
- This sensation usually diminishes after the first few days of application and in most cases will disappear with time and continued use.



3rd INDERCOS

National Dermatology & Cosmetology Congress with International Participants

14-17 MARCH, 2018
HILTON ISTANBUL BOSPHORUS HOTEL
ISTANBUL, TURKEY

REFERENCES

Manuel P. Pereira MP. Intraepidermal Nerve Fiber Density: Diagnostic and Therapeutic Relevance in the Management of Chronic Pruritus: a Review. *Dermatol Ther* (Heidelb) (2016) 6:509–517.

Farahnik B. Topical Botanical Agents for the Treatment of Psoriasis: A Systematic Review. *Am J Clin Dermatol* DOI 10.1007/s40257-017-0266-0 .

Chandra Pal H . Phytochemicals for the Management of Melanoma. *Mini Rev Med Chem*. 2016 ; 16(12): 953–979.

Simona-Roxana Georgescu. Capsaicin: Friend or Foe in Skin Cancer and Other Related Malignancies? *Nutrients* 2017, 9, 1365; doi:10.3390/nu9121365.

Alexandru DP Papoiu. Topical capsaicin. The fire of a ‘hot’ medicine is reignited. *Expert Opin. Pharmacother*. (2010) 11(8):1-13.

Manuel P. Pereira. Chronic Pruritus: Current and Emerging Treatment Options. *Drugs* DOI 10.1007/s40265-017-0746-9.

Juliane Reuter. Botanicals in Dermatology An Evidence-Based Review. *Am J Clin Dermatol* 2010; 11 (4): 247-267.

Till Weidner. Primary Localized Cutaneous Amyloidosis: A Systematic Treatment Review. *Am J Clin Dermatol* DOI 10.1007/s40257-017-0278-9.

C. Zeidler. Successful treatment of lichen amyloidosis using capsaicin 8% patch. *JEADV* 2016, 30, 1195–1252.

3rd INDERCOS

National Dermatology & Cosmetology Congress with International Participants

14-17 MARCH, 2018
HILTON ISTANBUL BOSPHORUS HOTEL
ISTANBUL, TURKEY



PHOTODYNAMIC THERAPY IN DERMATOLOGY

Amor Khachemoune

Photodynamic therapy (PDT) could be carried out using a procedure consisting of topical application of the porphyrin-precursor, 5-aminolevulinic acid (ALA) to the skin, followed after some time by illumination with various light parameters. PDT is an FDA approved treatment for actinic keratoses (AK's). Its off-label indications have expansive and now cover most aspects of dermatological diseases. Some of the reported uses include non-melanoma skin cancer, reversal of photo-damage, and enhancement of dermal remodeling. Skin appendage disorders treated with ALA-PDT include acne, folliculitis decalvans, hidradenitis suppurativa, sebaceous hyperplasia and onychomycosis. There is also a body of literature on its use in a wide range of other dermatological conditions such as scleroderma, psoriasis, viral warts, cutaneous leishmaniasis, linear porokeratosis, localized scleroderma, chondrodermatitis nodularis helices, and port-wine stains. PDT is a promising, well-tolerated option for the treatment of localized lesions of relapsed or refractory mycosis fungoides.



3rd INDERCOS

National Dermatology & Cosmetology Congress with International Participants

14-17 MARCH, 2018
HILTON ISTANBUL BOSPHORUS HOTEL
ISTANBUL, TURKEY

DERMATOLOGY AND PARA-AMINOBENZOIC ACID (PABA)

Müge Göre Karaali

Para-Aminobenzoic Acid (PABA, 4-aminobenzoic acid, $C_7H_7NO_2$) is an aminobenzoic acid isomer that combines with pteridine and glutamic acid to form folic acid. It is called as vitamin B₉ because of being essential nutrient for some bacteria. It is not essential for human due to synthesis of PABA by some intestinal bacteria. Grains, egg, mushrooms, milk, spinach, meat especially kidney and liver meat, Brewer's yeast are rich for PABA.

PABA helps to maintain intestinal flora, important for healthy skin and hair and skin pigment, helps in the utilization of pantothenic acid (vit B₅), prevents accumulation of abnormal fibrous tissue and assists formation of red blood cells. Long term use of antibiotics may cause PABA deficiency and its signs include constipation, premature wrinkling of skin, premature grey hair, irritability, depression and headache.

PABA is best known as the active ingredient in sunscreen. It is a chemical sunscreen product absorbs light throughout the UVB range with maximum absorbance at about 290 nm. Dermatologists became aware that it is a fairly common topical and systemic photosensitizer. For that reason PABA is not found much in sunscreens any longer. PABA esters replaced PABA, which are less irritating. There is cross-sensitivity with ester-type anesthetics, aniline type dyes, thiazides, sulfonyleurea, paraphenylenediamine drugs which are structurally similar to PABA. PABA is also a part of ester type local anesthetic agents.

In literature oral PABA was used for Peyronie's disease, scleroderma, lupus erythematosus, dermatomyositis, morphea, lichen scleroatrophicus, vitiligo, pemphigus, dermatitis herpetiformis, vitiligo, darkening of gray hair etc. with controversial results.

3rd INDERCOS

National Dermatology & Cosmetology Congress with International Participants

14-17 MARCH, 2018
HILTON ISTANBUL BOSPHORUS HOTEL
ISTANBUL, TURKEY



TOPICAL PEPTIDES IN AESTHETIC DERMATOLOGY

Zahide Eriş Eken

Peptides, which are short chain sequences of amino acids, are a rapidly expanding category of cosmeceuticals. The positive of one amino acid will conjoin with the negative of another, creating what is referred to as the peptide bond. They are known to have diverse biological roles, most prominently as signaling regulatory molecules in a broad variety of physiological processes including defense, immunity, stress, growth, homeostasis and reproduction.

There are three main categories of cosmeceutical peptides: "signal" peptides, "neurotransmitter-affecting" peptides, and "carrier" peptides. The first commercialised peptides were carrier peptides. The first carrier peptide was designed to deliver copper, a trace element necessary for wound healing. The largest peptide family currently used in marketed cosmeceuticals is made of the signal peptides. Signal peptides provide a multitude of actions, most notably stimulating collagen, elastin, fibronectin, proteoglycan and glycosaminoglycans. Neurotransmitter peptides function by inhibiting the release of acetylcholine at the neuromuscular junction. Enzyme modulating peptides directly or indirectly inhibit the function of a key enzyme in some metabolic processes.

Over the last 20 years, their use in cosmetics has been steadily growing because they help to battle signs of aging. They have the ability to penetrate the upper layer of the skin and act as dispatchers capable of triggering specific functions, such as collagen support so that skin can be firmer, thicker, and more elastic.

The advantages of using peptides as cosmeceuticals include their involvement in many physiological functions of the skin, their selectivity, their lack of immunogenicity and absence of premarket regulatory requirements for their use. However, there are disadvantages: clinical evidence for efficacy is often weak, absorption may be poor due to low lipophilicity, high molecular weight and binding to other ingredients, and prices can be quite high.



3rd INDERCOS

National Dermatology & Cosmetology Congress with International Participants

14-17 MARCH, 2018
HILTON ISTANBUL BOSPHORUS HOTEL
ISTANBUL, TURKEY

INNOVATIONS IN DERMATOLOGY: RADIOFREQUENCY ABLATION IN DERMATOLOGY

Fatih Göktaş

The naming relation between radio and electrosurgery arises from the similarity of the frequency of the alternating electric current used in electrosurgery to the frequency of electromagnetic radio waves. Radiofrequency electrosurgery, therefore, can be described as electrosurgery at the frequency interval of radio waves.

Hertz (Hz) is the unit of measurement for frequency. It refers to the number of cycles per second. One kilohertz (KHz) is 1,000 hertz, one megahertz (MHz) is 1 million hertz, and one gigahertz (GHz) is 1 billion hertz. The radio spectrum ranges from 3 KHz up to 300 GHz. Within this spectrum, a frequency interval is considered to be very low frequency (VLF) at 3 KHz to 30 KHz, low frequency (LF) at 30 KHz to 300 KHz, medium frequency (MF) at 300 KHz to 3 MHz and high frequency (HF) at 3 MHz to 30 MHz. Electrosurgical units used in dermatology operate within a frequency interval of 0.3 MHz to 5 MHz. Therefore, it may be argued that all electrosurgical devices work within the frequency interval of radio waves. However, the literature in this subject tended to refer to devices operating at frequencies of 3 MHz to 4 MHz as radiofrequency or high frequency electrosurgical devices. In this context, it would be more appropriate to call devices operating at 3 MHz and above "high frequency" electrosurgical devices rather than "radiofrequency" electrosurgery devices when distinguishing them from others that operate outside of this range.

Collateral thermal damage during electrosurgery is inversely related to the frequency of the electrosurgical instrument and directly proportional to the electrode diameter and contact time. High frequency electrosurgical devices cause minimal collateral thermal damage, resulting in rapid recovery after surgery and a good cosmetic outcome. Another advantage of high frequency electrosurgical devices is that cutting and coagulation can be performed at the same time.

In a dermatology practice, high frequency electrosurgery can be used as an ablative treatment option for a wide spectrum of dermatological diseases such as warts, seborrheic keratosis, skin tags, spider angioma, cherry angioma, rhinophyma, angiofibroma lesions of tuberous sclerosis, Bowen's disease, actinic keratosis, basal cell carcinoma and squamous cell carcinoma. In recent years, intralesional radiofrequency ablation has emerged as a new method for the successful treatment of angiolymphoid hyperplasia and keloid scars.

Understanding of the principles of high frequency electrosurgery, the effects of different modes (such as cut, cut and coagulation, and coagulation), appropriate power adjustments, and the selection of suitable electrodes for each lesion can contribute to treatment efficiency for the above-mentioned diseases, reduce the rate of complications, help to optimise the use of these devices in a dermatology practice and promote the discovery of new treatment areas.

3rd INDERCOS

National Dermatology & Cosmetology Congress with International Participants

14-17 MARCH, 2018
HILTON ISTANBUL BOSPHORUS HOTEL
ISTANBUL, TURKEY



MICROSPHERE TECHNOLOGY: HYPE OR HELP?

Leon Kircik

The role of vehicles is very important in topical treatment in dermatology. Novel formulations such as microsphere technology make the existing active molecules more user friendly by increasing tolerability.

We will discuss the role of microsphere technology in treatment of acne and actinic keratosis.

EVIDENCE - BASED SKINCARE

Leon Kircik

The role of skincare in dermatologic treatment is utmost important. We always use concomitant skin care in acne, rosacea, atopic dermatitis patients as well as photodamage. Therefore, it is crucial that our skincare regimen is evidence based. We will discuss the role of scientifically based skin care in dermatology



3rd INDERCOS

National Dermatology & Cosmetology Congress with International Participants

14-17 MARCH, 2018
HILTON ISTANBUL BOSPHORUS HOTEL
ISTANBUL, TURKEY

WHEN AESTHETIC CONCERNS ARE CLUES OF MORE SEVERE DISEASES?

Laura Atzori

Aesthetic issues are a current challenge of daily clinical practice, affecting the patient's relational life and consequently seeking for intervention. A superficial approach is deceiving since trivial events can be a clue to hidden severe pathological conditions that require prompt recognition and appropriate treatment. The dermatologist is in a lead position having the clinical eye trained to guess minimal details, completely changing the diagnosis. A series of emblematic cases will be presented, from genetic disorders to infections, whose consultation was required for aesthetic or minor dermatologic complaints.

WHEN THE CURE IS WORSE THAN THE DISEASE?

Laura Atzori

Dermatology is one of the most eclectic specialty, with acknowledge private practice opportunities. One of the major income is the critical examinations of the effectiveness of the prescribed treatment, and procedures, especially in the fields of aesthetic concerns.

A series of emblematic cases, from adverse drug reactions to skin damage and scarring, will be presented to alert on the risks of very common procedures, not to undervalue the role of training and expertise .

3rd INDERCOS

National Dermatology & Cosmetology Congress with International Participants

14-17 MARCH, 2018
HILTON ISTANBUL BOSPHORUS HOTEL
ISTANBUL, TURKEY



PLA THREAD USES FOR ANTIAGING

Şükran Sarıgül

Since the pioneering report of Sulamanidze et al. in the late 1990s by non-absorbable polypropylene sutures, thread lifting for facial ptosis has gained attention and become increasingly popular as a part of office based procedures for lifting face and neck. PLA is a biodegradable polymer which has been used in a variety of biomedical devices for over 40 years as absorbable plates, screws, and suture materials because of its excellent biocompatibility.

Currently, worldwide known PLA threads are available in two forms: 1) One part of the thread is made of PLA, while the other part is made of polylactide co glycolide (PLGA) and 2) As a copolymer with caprolactone (PLA/Caprolactone) to increase lasting effect of the suture.

Although the procedure has an extensive coverage, few publications exist in the literature regarding safety, efficacy, longevity or complications of these devices. However the procedure can be accepted as safe when implantation is carried out properly and satisfying when patient selection is performed accurately.



3rd INDERCOS

National Dermatology & Cosmetology Congress with International Participants

14-17 MARCH, 2018
HILTON ISTANBUL BOSPHORUS HOTEL
ISTANBUL, TURKEY

MITOCHONDRIAL THEORY OF AGING

Kansu Büyükaşar

Aging is a natural and inevitable process, which is influenced and modified by various genetic and biochemical factors as well as other systems working in close contact. The causes of normal aging are likely to be multifactorial with no single mechanism able to explain all aspects. There are several molecular hallmarks of aging such as mitochondrial dysfunction, depletion of stem cell reserves, genomic instability, epigenetic alterations, altered intracellular communication, deregulated nutrient sensing and loss of proteostasis.

Proposed Mechanisms of Aging

There are several theories of the biological causes of aging, which include: (a) Damage to mitochondria and cellular proteins from free radicals such as reactive oxygen species (ROS), (b) Accumulation of mutations in mitochondrial DNA over time, (c) Mitochondrial dysfunction such as disruption in Ca^{2+} homeostasis (d) Increased cell apoptosis, (e) Decrease in mitochondrial mass and characteristic changes of mitochondrial morphology.

Mitochondrial Theory of Aging: This theory comprises (1) Mitochondrial Free Radical Theory and (2) Mitochondrial DNA Mutations.

1. Mitochondrial Free Radical Theory: Mitochondria are the main unit of chemical power supply in the cell. By utilizing oxygen, it produces 95% of a cell's energy. Oxygen (O_2) is crucial for our life but it has a dark side as well. Normally, an O_2 absorbs 4 electrons and is safely converted into water. But if O_2 only takes up 1 or 2 electrons, a group of highly unstable molecules called ROS occur that can damage many kinds of biological molecules by stealing their electrons. 2–3% of the oxygen atoms taken up by mitochondria escape as free radicals, mainly as superoxide anions ($\text{O}_2^{\cdot-}$). The production of $\text{O}_2^{\cdot-}$ leads to oxidative stress, which is essentially an imbalance between the production of oxygen-derived free radicals and the ability of cells to detoxify their harmful effects. Oxidative stress determines lifespan, being the main culprit of accelerated senescence (Harman-1950s). Enzymatic sources of $\text{O}_2^{\cdot-}$ include: NADPH oxidases, cytochrome P450-dependent oxygenases, the proteolytic conversion of xanthine dehydrogenase to xanthine oxidase. Other numerous superoxide anion producing enzymes also exist.

3rd INDERCOS

National Dermatology & Cosmetology Congress with International Participants

14-17 MARCH, 2018
HILTON ISTANBUL BOSPHORUS HOTEL
ISTANBUL, TURKEY



2. Mitochondrial DNA Mutations: Until recently the production of ROS and subsequently mtDNA mutations has been the central hypothesis in aging. However, it has been proposed that mtDNA mutations may be generated by replication errors rather than by accumulated oxidative damage. Furthermore, interventions to modulate ROS levels in humans and animal models have not produced consistent results in terms of delaying disease progression and extending lifespan. So, it has been suggested that ROS generation is not a cause of aging, but rather represents a stress signaling in response to age-dependent damage. A mutation resulting from a single mtDNA molecule can expand clonally during mtDNA replication in somatic cells. This leads to random segregation of mtDNA mutations as the cell divides. Increased mtDNA mutations, by affecting mitochondrial bioenergetic capacity, ROS production, or redox status of the cell, contribute to deregulated stem cell homeostasis and premature aging phenotypes.

Summary of Causative Role of Mitochondria on Aging

1. Accumulation of reactive oxygen and nitrogen species
2. Damage to mitochondrial genome
3. Impaired mitochondrial gene expression
4. Inability of mitochondria to replicate, divide, further reducing energy production, etc.

Can we stop aging? What should be done to decelerate aging? As a matter of fact, aging cannot be avoided. However, there are some clues to turn back our biological clock and help us live longer. The secret answer seems to be the healthy mitochondria.

Epilogue: Mitochondria boosted our evolution but it triggered our aging and death as well.



3rd Indercos

National Dermatology & Cosmetology Congress with International Participants

14-17 MARCH, 2018
HILTON ISTANBUL BOSPHORUS HOTEL
ISTANBUL, TURKEY

SMOKING AND SKIN AGING

Deniz Demirseren

Smoking is the main modifiable cause of disease and death in the world. Tobacco consumption is directly linked to cardiovascular disease, chronic bronchitis, and many malignant diseases. Smoking is also closely associated with several dermatologic diseases such as psoriasis, pustulosis palmoplantaris, hidrosadenitis suppurativa, and systemic and discoid lupus erythematosus, as well as cancers such as those of the lip, oral cavity, and anogenital region.

The first proposed correlation between smoking and premature skin aging was made by Solly in 1856, when he reported a sallow complexion, wrinkled skin, and gaunt facial appearance in smokers. In 1971, Daniell emphasized a link between prominent periorbital wrinkling and smoking habits. In 1985, Model associated the term smoker's face with a list of telltale signs physicians can watch for to determine which of their patients had been smoking for at least 10 years.

Despite these clinical impressions, O'Hare et al asserted that cigarette smoking played a minor role in causing wrinkling, noting that previous studies, linking smoking and increased wrinkling failed to consider confounding variables such as sun exposure history and were unblinded and therefore subject to bias. O'Hare et al found that a positive smoking history accounted for only 6% of the explained variance in wrinkle scores between smokers and nonsmokers.

On the other hand, The relationship between cigarette smoking and skin aging is supported with a lot of studies between cigarette smoking and wrinkling. Smoker's skin has been characterised by prominent facial wrinkling particularly around the mouth and upper lip and eyes. Pursing the lips during smoking with contraction of the facial muscles and squinting due to eye irritation from the smoke might cause the formation of wrinkles around the mouth and eyes (crows feet). Facial pigmentation changes may also occur. Epidemiological evidence exists to indicate female Japanese smokers have darker skin color. One twin study estimated that, 10 years of smoking corresponded to a difference of appearance of roughly 2.5 years older. Smoking is one of the many factors that contribute to premature skin aging, but the exact mechanism by which smoking induces facial wrinkling is still poorly understood. There are 3,800 chemical substances; nicotine, carbon monoxide, tar, formaldehyde, cyanhydric acid, ammonia, mercury, lead cadmium...

Smoking probably exerts its deleterious effects on skin directly through its irritant components on the epidermis and indirectly on the dermis via the blood circulation. The decreased moisture in the stratum corneum of the face contributes to facial wrinkling due to direct toxicity of the smoke.

The changes in the macromolecular metabolism of the dermis are a major factor leading to skin aging. Specifically, the accumulation of elastosis material is accompanied by the degradation of matrix proteins, which is mediated by matrix metalloproteinase (MMPs) in skin aging. Molecular alterations in the dermis include decreased collagen synthesis, MMP induction, and abnormal accumulation of elastic fibers and proteoglycans.

Cigarette smoke alters biological processes in the skin promoting skin aging. However, we still do not know what cumulative doses induce these clinical signs, and how much is due to direct skin exposure versus systemic exposure following inhalation.

3rd INDERCOS

National Dermatology & Cosmetology Congress with International Participants

14-17 MARCH, 2018
HILTON ISTANBUL BOSPHORUS HOTEL
ISTANBUL, TURKEY



SPORTS & SKIN: BENEFITS (ANTI-AGING EXERCISES) AND DAMAGE

Gül Yıldırım

While we get older many changes occur in our body and skin. Age-related changes can be summarized as below; sarcopenia, osteoporosis, cardiovascular diseases, diabetes, metabolic syndrome, central obesity, neurodegeneration, cancer, depression and asthma.

Aging of the skin is associated with deterioration of the dermal and epidermal layers of the skin; resulting from reductions in cell proliferation, collagen synthesis, extracellular matrix remodeling and altered epidermal morphology. These pathophysiological changes are thought to be driven by aged cells that reduced energy metabolism, higher mitochondrial oxidative stress and pronounced mitochondrial deletions. This reflects characteristics of mitochondrial free radical theory of aging.

Physical exercise has been well demonstrated as an effective anti-aging intervention. Although exercise cannot reverse the aging process, regular exercise has multi-system anti-aging effects. The broad systemic benefits of exercise on the aging process are likely complexly regulated among many organs. Mainly secretion of the molecules from skeletal muscle is related with benefits of exercise.

There is only a few research about the direct effect of exercise on skin . An important one of which showed that endurance exercise attenuates age-associated changes to skin in humans and mice with exercise-induced IL-15 as a regulator of mitochondrial function in aging skin. Exercise controls IL-15 expression in part through skeletal muscle AMP-activated protein kinase (AMPK) as a central regulator. Elimination of muscle AMPK causes a deterioration of skin structure and daily IL-15 therapy mimics some of the anti-aging effects of exercise on muscle and skin in mice.

To achieve antiaging effects the duration and amount of exercise must be well managed. ACSM declares quantity and quality of exercises which is required for cardiovascular, musculoskeletal and neuromotor fitness. This is a well defined guidance for whom is interested in exercise for anti-aging purposes.



3rd INDERCOS

National Dermatology & Cosmetology Congress with International Participants

14-17 MARCH, 2018
HILTON ISTANBUL BOSPHORUS HOTEL
ISTANBUL, TURKEY

WOUNDS AND BECAPLERMIN

Necmettin Akdeniz

Becaplermin (recombinant human platelet-derived growth factor (PDGF) BB) is a dimeric glycoprotein. Whilst PDGF occurs naturally as homodimers or heterodimers of A and B chains, becaplermin comprises only the BB homodimer. It is a homodimer composed of two identical polypeptide chains that are bound together by disulfide bonds. Becaplermin is produced by recombinant DNA technology by insertion of the gene for the B chain of platelet derived growth factor (PDGF) into the yeast, *Saccharomyces cerevisiae*.

Platelet-derived growth factor is a protein that is normally secreted by platelets, macrophages, endothelial cells, and, in some cases, fibroblasts. This cytokine is known to stimulate fibroblast proliferation and angiogenesis. Becaplermin is used as a topical wound healing agent and is approved for the treatment of lower extremity, neuropathic, diabetic ulcers that extend into the subcutaneous tissue or beyond and **have an adequate blood supply**. The efficacy of becaplermin has not been established for diabetic neuropathic ulcers that do not extend through the dermis into subcutaneous tissue, for ischemic diabetic ulcers, for venous stasis ulcers, or for pressure ulcers. In addition to helping heal certain lower extremity, neuropathic, diabetic ulcers, becaplermin may help heal ulcerated hemangiomas of infancy; ulcer healing occurred within 3—21 days of becaplermin 0.01% application daily in 7 infants

A gel containing becaplermin 0.01% has been demonstrated to accelerate healing of deep diabetic ulcers and pressure ulcers. The gel is applied directly to the wound for 12 h daily.

Pharmacoeconomic studies reinforce the cost effectiveness of becaplermin as an adjunct to good wound care. Studies showed that when used with good wound care, complete healing significantly increased and the ulcers healed on average 6 weeks faster.

Becaplermin must not be used at patients with known neoplastic disease at the site of application, and cautious use of becaplermin is advised for patients with known cancer of any type. Becaplermin also is contraindicated in situations such as the breast-feeding children, corticosteroid therapy, cresol hypersensitivity, infants, infection, neonates, paraben hypersensitivity, peripheral vascular disease, pregnancy.

3rd INDERCOS

National Dermatology & Cosmetology Congress with International Participants

14-17 MARCH, 2018
HILTON ISTANBUL BOSPHORUS HOTEL
ISTANBUL, TURKEY



WOUND HEALING

Tamer İrfan Kaya

Wound healing is the restoration of injured tissues by replacement of dead tissue with viable tissue; this starts immediately after an injury, may continue for months or years. In recent years, the amount of knowledge about wound healing has significantly increased. Wound healing is a complex process that includes many biological and physiological events, which has temporally overlapping processes including inflammation, blood clotting, and cellular proliferation and extracellular matrix remodeling. It is a multi-cellular, multi-molecular process involving co-ordinated inter-play between complex signalling networks. Different cell types (such as platelets, macrophages, neutrophils, endothelial cells, and fibroblasts) release growth factors during the healing process. Growth factors induce proliferation of fibroblasts, endothelial cells, and epithelial cells with subsequent tissue formation. Wound healing is affected by various local and systemic factors, including diabetes mellitus, infection, ischemia, and aging. A wound that fails to heal within 3–4 months may be regarded as chronic wound. In dermatology, the preferred term for 'chronic wound' is 'chronic cutaneous ulcer'. Despite being clinically heterogeneous, chronic ulcers are generally assigned to one of three major clinical categories: venous leg ulcers, diabetic foot ulcers or pressure ulcers. Although we have much knowledge about the fundamental cellular and molecular mechanisms of acute wound healing from various animal models, we have learned much less about chronic wound repair pathology from these models, accordingly the management of a chronic wound has become a major therapeutic challenge throughout the World.



3rd INDERCOS

National Dermatology & Cosmetology Congress with International Participants

14-17 MARCH, 2018
HILTON ISTANBUL BOSPHORUS HOTEL
ISTANBUL, TURKEY

WOUND CARE AND SCARS

Severin Laeuchli

Every wound healing process results in scar tissue. Normal scars take up to one year to mature. Pathologic scar types include hypertrophic scars and keloids, the latter appear later, extend beyond the margins of the original wound and show little spontaneous regression. Risk factors for keloids include genetic predisposition (HLA-B14,-B1,HLA-BW16, HLA-DR5), darker skin types, age 10-30 and skin trauma in certain body areas (presternal, shoulders). Furthermore, prolonged wound healing and especially a prolonged inflammatory phase of wound healing increase the risk of pathological scars. A central role in the complex interplay of cytokines and the mechanisms of scar formation is played by TGF- β which exists in 3 isoforms that have pro-fibrotic and anti-fibrotic effects and also induce α -SMA which is important for scar contraction.

Therefore, one of the important aspects in the prevention of scars especially in individuals prone to hypertrophic scarring is avoiding prolonged inflammatory phases of wound healing. This includes proper surgical technique reducing wound tension, infection and hematoma. Other measures of prevention include taping to reduce wound tension, pressure therapy and the early use of silicone sheets / gels and other topical scar treatments. Hypertrophic wounds and keloids can be treated with intralesional chemotherapy. The most common substance for injection is corticosteroids, alternatives include 5-FU and Bleomycin. Keloids are usually treated with combination treatments of cryotherapy or surgical excision and intralesional injections or radiotherapy.

3rd INDERCOS

National Dermatology & Cosmetology Congress with International Participants

14-17 MARCH, 2018
HILTON ISTANBUL BOSPHORUS HOTEL
ISTANBUL, TURKEY



CLOSING LECTURE VITILIGO

Torello Lotti

Vitiligo as a systemic disease Torello Lotti MD Abstract Vitiligo is an acquired depigmentary skin disorder of unknown etiology. Vitiligo is not only a disease of melanocytes of the skin. Human melanocytes are derived from the neural crest and are located on various parts of the body. The involvement of skin melanocytes is the most visible one, but a systemic involvement of melanocytes can be observed. Some types of vitiligo (nonsegmental vitiligo) may also be associated with various diseases, mainly with autoimmune pathogenesis. Vitiligo represents a spectrum of many different disorders with different etiologies and pathogeneses, causing a common phenotype: the loss of melanocytes and/or their products. This phenotype is always consistent with a systemic involvement.



Oral Presentations



3rd INDERCOS

National Dermatology & Cosmetology Congress with International Participants

14-17 MARCH, 2018
HILTON ISTANBUL BOSPHORUS HOTEL
ISTANBUL, TURKEY



OP-01

[RESEARCH IN D/V, EXPERIMENTAL D/V]

BETATROPHIN AND IRISIN LEVELS IN PATIENTS WITH PSORIASIS

Bengisu Ozarslan¹, Selda Isik Mermutlu² ¹Department of Dermatology and Venereology, Kırklareli State Hospital ²Department of Dermatology and Venereology, Onsekiz Mart University, Canakkale

INTRODUCTION & OBJECTIVES: Psoriasis is a chronic, inflammatory skin disease associated with the components of metabolic syndrome (MS); obesity, diabetes mellitus, insulin resistance, hypertension, and dyslipidemia. Betatrophin and irisin are newly defined novel hormones and have been proposed to regulate glucose and lipid metabolism. Levels of circulating betatrophin and irisin alter in several metabolic diseases. In this study, we aimed to define the link between betatrophin, irisin and psoriasis and the predictive value of the hormones in indicating the coexistence of psoriasis with metabolic syndrome.

MATERIALS & METHODS: A total of 91 patients was included in the study. The first group consisted of 33 psoriasis patients with metabolic syndrome diagnosed due to International Diabetes Foundation metabolic syndrome criteria. For the second group, 26 psoriasis patients who did not carry any of the metabolic syndrome criteria were selected. 32 healthy subjects were enrolled in the control group. Patients having any other chronic systemic disease and systemic treatment for the last 3 months were not included in the study. Age, gender, onset and duration of the disease, body mass index, Psoriasis area severity index (PASI) were recorded. Serum, fasting blood glucose, lipid profile and insulin levels were assessed. To evaluate insulin resistance, the Homeostasis Model Assessment (HOMA-IR) was used. Serum betatrophin, irisin levels were assessed by enzyme-linked immunosorbent assay (ELISA) method. Statistical analysis was performed by using Statistical Package for the Social Sciences (SPSS version 19.0)

RESULTS: Serum levels of betatrophin decreased in patients with psoriasis and significantly higher in control group ($p = 0.001$, $p = 0.004$, respectively). In addition, betatrophin level of the MS (-) patient group was significantly higher than MS (+) patient group ($p < 0.001$). Irisin levels showed no significant difference between groups. Betatrophin was positively correlated with irisin ($p < 0.001$, $r = 0.69$) and negatively correlated with BMI, insulin, HOMA-IR, fasting blood glucose in psoriatic patients ($p = 0.020$, $r = -0.302$; $p < 0.001$, $r = -0.470$; $p < 0.001$, $r = -0.531$; $p = 0.001$, $r = -0.425$). On the other hand, there was no significant correlation between betatrophin, irisin levels and PASI ($p = 0.254$, $r = -0.151$; $p = 0.160$, $r = -0.185$)

CONCLUSIONS: We concluded that serum betatrophin level decreased in psoriasis, further reduced in metabolic syndrome-psoriasis concomitance. According to these results, we think that betatrophin and indirectly irisin may be a predictor of comorbidities that may accompany psoriasis. Our study was the first clinical study in this area. We think that it should be supported by further comprehensive studies

Keywords: psoriasis, betatrophin, irisin, metabolic syndrome

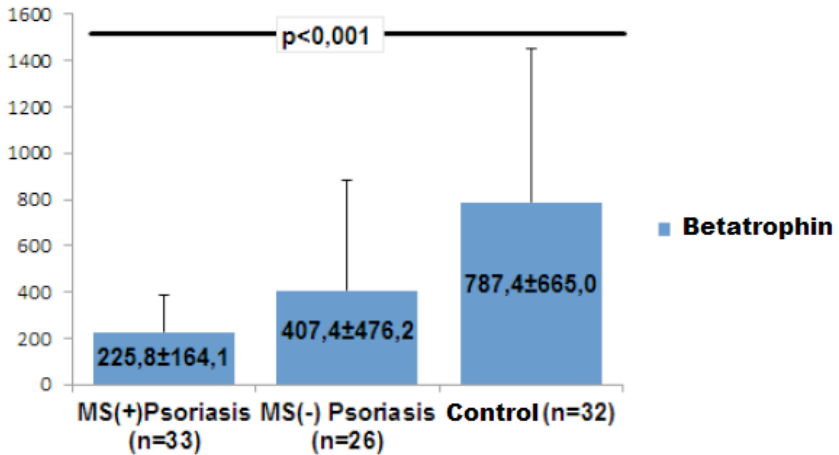


3rd INDERCOS

National Dermatology & Cosmetology Congress with International Participants

14-17 MARCH, 2018
HILTON ISTANBUL BOSPHORUS HOTEL
ISTANBUL, TURKEY

Evaluation of betatrophin values between groups



p: Kruskal Wallis analysis of variance, n:number, MS:metabolic syndrome

OP-02

[INFECTIOUS DISEASES, PARASITIC DISEASES, INFESTATIONS]

HERPES ZOSTER IN HEALTHY CHILDREN: A TOTAL OF 38 CASES

Hamza Aktaş¹, Semahat Alp Erdal², Şahinan Karlı³

¹Hamza Aktaş: Private Sultan's Hospital, Department of Dermatology, MD. Diyarbakır, Turkey

²Semahat Alp Erdal: SBÜ Diyarbakır Gazi Yaşargil Training and Research Hospital, Department of Dermatology, MD. Diyarbakır, Turkey

³Şahinan Karlı: Erdemli State Hospital, Department of Infectious Diseases and Clinical Microbiology, MD. Mersin, Turkey

BACKGROUND: Herpes Zoster (HZ) caused by the reactivation of the latent Varicella Zoster Virus (VZV) infection is a painful vesicular dermatomal eruption that can rarely developed in childhood. HZ essentially occurs in immunocompromised children. HZ is primarily considered to be a disease of adults, but recent reports show that there is an increase in the number of cases in childhood. This study was designed to evaluate the demographic and clinical features, comorbidities, treatments and complications in children with HZ.

3rd INDERCOS

National Dermatology & Cosmetology Congress with International Participants

14-17 MARCH, 2018
HILTON ISTANBUL BOSPHORUS HOTEL
ISTANBUL, TURKEY



METHODS: Data of 38 patients diagnosed with HZ in Dermatology and Infectious Disease outpatient clinic between October 2011 and December 2015 were retrospectively evaluated in terms of age, gender, dermatome, used drugs, underlying disease, story of Chickenpox and VZV vaccine, laboratory data, onset time as month, choice of treatment.

RESULTS: A total of 38 cases were 24 males and 14 females. Mean of age was 8.14 ± 4.99 (range; 6 months- 16 years). 29 subjects had pruritus, yet 21 subjects had pain. In 12 patients, there were thoracic dermatomal involvement, while in the others, according to descending order, there were cervical (n=10), lumbar (n= 9), sacral (n=5) and trigeminal (n=2) involvement. Whereas Acyclovir was prescribed in 21 cases and valacyclovir in 9 cases as antiviral therapy, symptomatic treatment was considered in 8 patients. No one had any complication.

CONCLUSION: HZ may also occur in healthy children without any immunosuppression. In children, pain appears less, but pruritus is more frequent than in adults. Complications are rare in these subjects.

Keywords: Herpes zoster, healthy children, childhood.

Figure 1. The seasons in which the infection appeared.

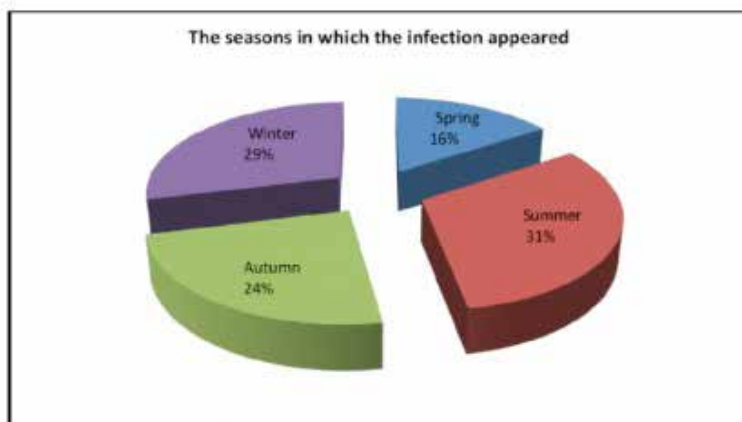


Figure 1. The seasons in which the infection appeared.



3rd INDERCOS

National Dermatology & Cosmetology Congress with International Participants

14-17 MARCH, 2018
HILTON ISTANBUL BOSPHORUS HOTEL
ISTANBUL, TURKEY

Table1. Demographic and clinical characteristics of cases with HZ

Age	Gender	Dermatome	ChickenPoxinf	ChickenPoxVaccine	Add. Illness	Therapy	Triggering Factor	Season
6 month	M	Thoracal	+	-	-	Acyelovir	-	October
12 month	M	Cervical	Indefinite	-	-	Acyelovir	-	October
12 month	M	Cervical	Indefinite	+	-	Acyelovir	-	March
14 month	M	Cervical	Indefinite	+	-	Acyelovir	-	September
2 age	F	Thoracal	+	-	-	Acyelovir	-	June
2 age	M	Sacral	+	-	-	Acyelovir	Stress	June
2 age	F	Cervical	+	-	-	Symponatic	-	May
3 age	F	Sacral	+	-	+	Acyelovir	Stress	May
3 age	M	Trigeminal	+	-	-	Acyelovir	Stress	August
3 age	M	Sacral	+	-	Tonsillitis	Acyelovir	+	August
5 age	M	Cervical	+	-	-	Acyelovir	-	January
5 age	F	Lumbar	+	-	+	Acyelovir	+	January
5 age	M	Thoracal	+	-	-	Acyelovir	-	October
5 age	F	Cervical	+	-	-	Symponatic	Stress	December
6 age	M	Sacral	+	-	-	Acyelovir	-	June
6 age	M	Trigeminal	+	-	-	Acyelovir	Stress	August
7 age	K	Lumbar	+	-	-	Acyelovir	-	July
7 age	M	Thoracal	+	-	-	Acyelovir	Stress	October
8 age	M	Cervical	+	-	-	Acyelovir	Stress	October
8 age	K	Lumbar	+	-	-	Acyelovir	-	August
8 age	K	Lumbar	?	-	-	Symponatic	-	August
8 age	K	Lumbar	+	-	-	Symponatic	Stress	October
10 age	K	Lumbar	?	-	-	Acyelovir	-	October
11 age	M	Sacral	?	-	-	Valacyclovir	-	May
11 age	K	Thoracal	+	-	Influenza	Acyelovir	-	August
12 age	K	Thoracal	-	-	-	Valacyclovir	Stress	December
13 age	K	Lumbar	-	-	-	Valacyclovir	-	January
13 age	M	Lumbar	-	-	-	Symponatic	-	February
13 age	M	Thoracal	?	-	-	Symponatic	-	December
13 age	M	Thoracal	?	-	-	Acyelovir	-	October
13 age	K	Thoracal	+	-	Globlastoma	Valacyclovir	-	March
14 age	M	Thoracal	?	-	-	Valacyclovir	Stress	May
14 age	M	Lumbar	+	-	-	Valacyclovir	-	December
15 age	M	Thoracal	?	-	-	Valacyclovir	Stress	January
15 age	M	Thoracal	+	-	-	Valacyclovir	Stress	December
15 age	M	Cervical	-	-	-	Symponatic	-	December
15 age	M	Cervical	-	-	-	Symponatic	-	December
16 age	M	Cervical	-	-	-	Valacyclovir	Stress	June

Table 2. Affected Dermatome

Affected Dermatome	Female n (%)	Male n (%)	Total n (%)
Thoracal	4 (33,3)	8 (66,7)	12 (31,6)
Cervical	2 (20,0)	8 (80,0)	10 (26,3)
Lumbar	7 (77,8)	2 (22,2)	9 (23,7)
Sacral	1 (20,0)	4 (80,0)	5 (13,2)
Trigeminal	0 (0)	2 (100)	2 (5,3)

3rd INDERCOS

National Dermatology & Cosmetology Congress with International Participants

14-17 MARCH, 2018
HILTON ISTANBUL BOSPHORUS HOTEL
ISTANBUL, TURKEY



OP-03

[PIGMENTARY DISEASES]

FACIAL MELANOSSES IN INDIAN POPULATION

Meghna Sharma

Meghna Sharma

The variability of skin colour worldwide is a well known fact and so are the variations in climate, diet and social parameters. All of these account for the differences in the multitude of pigmentary disorders worldwide. There is a discrepancy in the size of the melanosomes from one geographic location to the other: with Africans having the largest melanosomes followed by Indians, Mexicans and Chinese. Facial melanoses, therefore, are a common presentation in the Indian population. Data from Asian countries reveal that pigmentary conditions are amongst the top ten conditions for which patients seek treatment. In addition, the rising economic prosperity in India, seeking treatment for pigmentary conditions, esp. facial, is becoming a priority amongst this population. Facial melanoses are not just trite cosmetic changes because they can have a strong psychosocial impact on the individuals facing them. An in depth review of the psychological impact of these disorders also helps the dermatologist to tailor therapy attuned with the patient's clinical, psychological and socioeconomic profile. In this study we will present the spectrum of facial melanoses in our part of the country. The psychological impact and the treatment modalities used shall also be discussed.

Keywords: melanoses, QoL, facial



3rd INDERCOS

National Dermatology & Cosmetology Congress with International Participants

14-17 MARCH, 2018
HILTON ISTANBUL BOSPHORUS HOTEL
ISTANBUL, TURKEY

OP-04

[Genetics]

Investigation of some miRNA expression levels associated with melanogenesis in vitiligo patients

Gurbet Doğru¹, Özlem İzci Ay¹, Mehmet Emin Erdal¹, Mustafa Ertan Ay¹, Merve Türkegün², Ümit Tursen²

¹Mersin University, Faculty of Medicine Department of Medical Biology and genetic

²Mersin University, Faculty of Medicine Department of Dermatology ³Mersin University, Faculty of Medicine Department of Bioistatistic and Medical Informatics

INTRODUCTION & OBJECTIVES: Vitiligo is the most common depigmenting and acquired chronic disorder of the skin resulting from selective destruction of melanocytes. Vitiligo is characterized by the appearance of patchy discoloration evident in the form of milky white macules. Lesions can change in size and shape over time and can develop at any age, but in approximately half of all cases the disease onset is before the age of twenty. Exact prevalence is difficult to estimate the prevalence of vitiligo is often referred to as 0.5–1% of the world's population. There are many theories about the etiology of vitiligo. Autoimmune theory is the strongest theory in explaining the pathogenesis of the vitiligo. A lot of researches have paid attention to the possibility that miRNAs play a role in the pathogenesis of various human disorders including skin diseases and have a major impact on several physiological and pathological cellular processes including modulation of the innate and the adaptive immune system. The clinical implications of miRNAs are intriguing, both from a diagnostic and a therapeutic perspective. Accordingly, there is emerging evidence for the clinical potential of miRNAs as both biomarkers and possible therapeutic targets in skin diseases.

MATERIALS & METHODS: 56 patients diagnosed as vitiligo in the Department of Dermatology, Mersin University Faculty of Medicine were included in the study. After a detailed history and a careful physical examination of each patient involved in the study, the diagnose was confirmed by a Wood lamp examination. Patients were queried comprehensively about age, gender, the clinical types of the lesions of vitiligo, duration of the disease, family history of vitiligo, presence of any stress factor before the onset of the disease. 56 individuals were included in the study as a control group. Molecular analyses of expressions that belong to hsa-miR-3163, hsa-miR-6783-3p, hsa-miR-1343-3p hsa-miR-4696, hsa-miR-6824, hsa-miR-5197-3p, hsa-miR-4495, hsa-miR-3680-3p, miR-26b genes, that respectively belong to MITF, SOX 10, TYR, TYRP1, BCL2 genes are performed for each subject using the method of Real-Time PCR, whereafter RNA and cDNA are isolated from blood samples of the patients and control subjects.

RESULTS: Expression levels of hsa-miR-3163, hsa-miR-6783-3p, hsa-miR-1343-3, hsa-miR-4696, hsa-miR-5197-3p, hsa-miR-3680-3p were not significantly different between patient and control groups. A statistically significant relationship between the expression levels of hsa-miR-4495 and hsa-miR-6824 genes and the risk of Vitiligo disease was found ($p < 0.05$). **CONCLUSION:** According to the genetic hypothesis, vitiligo inheritance is multigenic. In conclusion, these data indicate that hsa-miR-6824 which targeting the TYR gene and hsa-miR-4495 which targeting BCL2 gene may play a role in the pathogenesis of vitiligo. This finding has shown that in the future miRNAs may be important molecules in establishing treatment models for vitiligo.

Keywords: Vitiligo, melanogenesis, miRNA expression, Real Time PCR

3rd INDERCOS

National Dermatology & Cosmetology Congress with International Participants

14-17 MARCH, 2018
HILTON ISTANBUL BOSPHORUS HOTEL
ISTANBUL, TURKEY



OP-05

[CUTANEOUS ONCOLOGY]

RADIOTHERAPY OF MALIGN MELANOMA: A SINGLE INSTITUTION EXPERIENCE FROM NORTHEAST

Mustafa Kandaz

Karadeniz Technical University, Faculty of Medicine, Department of Radiation Oncology

BACKGROUND: Radiation therapy is used for adjuvant therapy on the patients with recurrence or lymphadenectomy in the malign melanomas. Also the treatment is used for palliative on metastatic patients.

PATIENTS AND METHODS: Between 1996 and 2017, 35 patients who received adjuvant radiotherapy and 55 patients who received palliative radiotherapy were retrospectively analyzed.

RESULTS: Of the 90 patients included in the study, 56 (62%) were men and 34 (38%) were women. The mean patient age was 63 ± 15.6 years (age range: 22–95 years). For all patients, the overall survival time was 32.23 ± 7.87 months (95% CI, 16.8–47.6). As adjuvant therapy, 48 Gy (hypofractionated) radiotherapy was used in 4 patients and 50–66 Gy radiotherapy was used in 31 patients. Overall survival in these patients was 66.14 ± 15.04 (95% CI 36.6–95.6) months. Mean metastases occur in patients is 37.19 ± 41.6 months (range: 2–138 months), which 37 (41%) patients in the brain, 12 (13%) patients in the bone and 6 (7%) patients in the with non-regional lymph nodes metastasis. 20–30 Gy radiotherapy was used for metastasis treatment. Overall survival in brain metastasis, bone metastasis and lymph nodes metastatic patients was 4.22 ± 0.81 (95% CI 2.62–5.82), 7.6 ± 3.29 (95% CI 1.14–14.05) and 7.33 ± 3.93 (95% CI 0–15.03) months respectively.

CONCLUSIONS: Although the regional nodal disease can be favorably controlled with lymphadenectomy and radiotherapy, the risk of distant metastases and the risk of disease-related death is high. In addition, metastasis-related symptoms (particularly pain) can be controlled by radiotherapy.

Keywords: Malign Melanoma, Radiotherapy, Overall Survival



3rd INDERCOS

National Dermatology & Cosmetology Congress with International Participants

14-17 MARCH, 2018
HILTON ISTANBUL BOSPHORUS HOTEL
ISTANBUL, TURKEY

OP-06

[INFLAMMATORY SKIN DISEASES]

THE MICROVASCULAR CHANGES IN PSORIATIC PATIENTS WITH NAIL DISEASE; A LINK BETWEEN A GRAY SCALE AND NAIL VESSEL RESISTIVE INDEX FINDINGS BY ULTRASOUND AND NAILFOLD VIDEOCAPILLAROSCOPY FINDINGS

Rabia Oztas Kara¹, Sibel Bakirci Ureyen², Zeynep Erturk³, Mahizer Yaldiz¹

¹Department of Dermatology, Sakarya Education and Research Hospital, Sakarya, Turkey

²Department of Division of Rheumatology, Sakarya Education and Research Hospital, Sakarya, Turkey

³Department of Internal Medicine, Sakarya Education and Research Hospital, Sakarya, Turkey

BACKGROUND: The pathogenesis of nail disease in patients with psoriasis has been incompletely understood to date, therefore there has been increasing interest to better understand microvascular changes of psoriatic nail disease (PND). The objective of this study is to evaluate the link between nail fold vessel resistive index (NVRI) measured using ultrasound (US) and capillary loops diameters measured using nailfold videocapillaroscopy (NVC), as well as to assess the morphological appearance of the nail bed in patients with PND as compared with healthy controls (HC).

METHODS: This study was conducted in patients with PND admitted to the psoriasis unit of the dermatology outpatient clinic and HC. General demographic data were collected from all subjects. Psoriasis Area and Severity Index (PASI), Nail Psoriasis Severity Index (NAPSI) and Dermatology Quality of Life Index (DQOL) were assessed for clinical evaluations. The nail plate thickness (NPT) was measured on gray scale using US. The NVRI was measured using color Doppler (CD) US. The measurements of the apical, arterial, venous limb diameters and morpho-structural changes (tortuous, cross-linked capillaries) were assessed using NVC.

RESULTS: Thirty-four patients with PND and 15 HC were enrolled in this study. The two groups were matched for age and body mass index (BMI). Patients with PND had higher NPT and NVRI in comparison with HC [(20 (17-23) vs 14 (14-15), $p<0,001$), (0,55(0,51-0,61) vs 0,43 (0,38-0,49), $p<0,001$), respectively]. A higher proportion of patients with PND had tortuous capillaries than HC (62% and 20% respectively, $p=0,005$). The mean NVRI was higher in patients with PND who had tortuous capillaries than patients who did not have tortuous capillaries (0.58 (0.7) and 0.52 (0.09), respectively $p=0.033$).

CONCLUSION: Microvascular changes can be detected easily using non-invasive methods such as US and NVC. These methods can provide an objective data to better assess PND. Further longitudinal studies are necessary to understand the significance and implications of microvascular changes in the psoriatic nail.

Keywords: Psoriasis, nail disease, ultrasound, nailfold capillaroscopy, nailfold resistive index

3rd INDERCOS

National Dermatology & Cosmetology Congress with International Participants

14-17 MARCH, 2018
HILTON ISTANBUL BOSPHORUS HOTEL
ISTANBUL, TURKEY



OP-07

[Lasers]

COMPARATIVE STUDY OF TREATMENT OF RECALCITRANT WARTS WITH ABLATIVE CO2 LASER AND QS-ND-YAG LASER

Eman Moustafa Sanad, Ahmed Mohamed Hamed
Department of dermatology and andrology, Benha university, Egypt

INTRODUCTION: Warts are common viral infection that are usually challenging in treatment. Conventional treatment methods are usually invasive, have low efficacy, and need long recovery periods.

MATERIAL / METHODS: The study included 20 patients with multiple warts that were randomly divided equally into two groups, patients of group I were treated with ablative CO2 (power, 2 to 4 watt) in a continuous mode for only one session. Group II were treated with long pulsed Nd:YAG once a month for a maximum of three sessions (spot size, 5 mm; fluence 200 J/cm²; pulse duration 30 ms and frequency 1 Hz/sec). Patients were followed up monthly for six months after completing treatment regimen.

RESULTS: Both CO2 and Nd:YAG lasers were effective in the treatment of recalcitrant warts. Nd:YAG laser therapy had less side effects and less recurrence rate.

CONCLUSIONS: Long pulsed Nd:YAG laser is recommended in treatment of recalcitrant warts.

Keywords: warts, CO2 laser, Nd-YAG laser



3rd INDERCOS

National Dermatology & Cosmetology Congress with International Participants

14-17 MARCH, 2018
HILTON ISTANBUL BOSPHORUS HOTEL
ISTANBUL, TURKEY

OP-08

[GYNAECOLOGICAL D/V, GENDER D/V]

INTRAVAGINAL COG THREAD APPLICATIONS

Ozgur Leylek

Department of Obstetric and Gynecology - Cosmetic Gynecology, Female Private Women Health Center, Istanbul, Turkey

INTRODUCTION: There are many kind of COG threads are used in aesthetic medicine. Developings in their production technology made their using field more larger then before. Newly, COG thread applications entered the cosmetic gynecology as a different field. In this study, we aimed to show the efficiency of COG threads for tightening of vaginomucosal relaxation.

MATERIALS-METHODS: We choose the subjects between from the patients who applied our clinic for sexual pleasure deficiency via to vaginal relaxation. The patients who have sexual pleasure deficiency caused by other problems except vaginal relaxation were excluded. And the patients who have cystocele and/or rectocele and/or uterin decensus/prolapsus and the other sistemic contrindications were also excluded. Under the local anesthesia, we performed the COG threads into the vaginal mucosa by our two new technics, VTT-L (Vaginal Thread Tightening-Longitudinal) and VTT-C (Vaginal Thread Tightening-Circular). All patients were evaluated by FSFI scoring (Female Sexual Function Index) before and after the COG applications.

RESULTS: We determined that vaginal COG applications provide the vaginal tightening via to vaginal mucosal tickening by both biological and mechanical effect of the threads. As a result, we found an acceptable difference between before and after FSFI scoring of the patients.

CONCLUSION: Although there isn't any study published about intravaginal COG application in literature yet and we could not have enough number of patients, most of the women included in the study declerated that they were pleased from the results. We belive that intravaginal COG applications will be a certain alternative way to the other non-surgical vaginal tightening methods soon.

Keywords: cog, thread, vaginal, tightening,

3rd INDERCOS

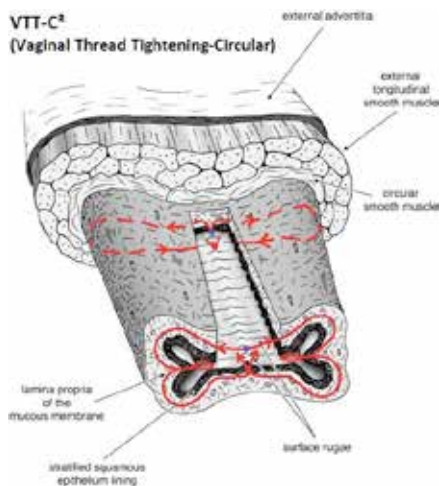
National Dermatology & Cosmetology Congress with International Participants

14-17 MARCH, 2018
HILTON ISTANBUL BOSPHORUS HOTEL
ISTANBUL, TURKEY



VTT-C

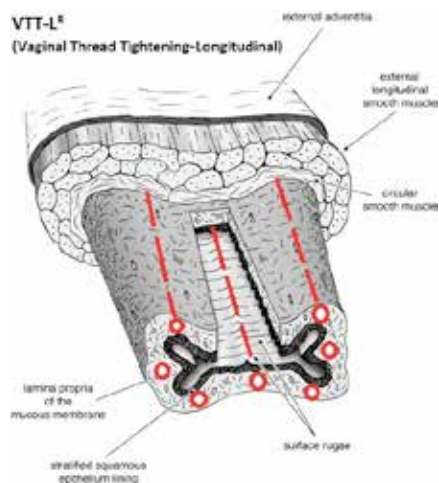
VTT-C⁺ (Vaginal Thread Tightening-Circular)



Circular COG Threads insertion in to the vaginal mocosa

VTT-L

VTT-L⁺ (Vaginal Thread Tightening-Longitudinal)



Longitudinal COG Threads insertion into the vaginal mucosa



3rd INDERCOS

National Dermatology & Cosmetology Congress with International Participants

14-17 MARCH, 2018
HILTON ISTANBUL BOSPHORUS HOTEL
ISTANBUL, TURKEY

OP-09

[PIGMENTARY DISEASES]

STUDY OF THE CUTANEOUS EXPRESSION OF THYMIC STROMAL LYMPHOPOIETIN (TSLP) IN A SAMPLE OF VITILIGO PATIENTS: A CASE-CONTROL STUDY

Noha Abdel Rehim Nagui¹, Maha Fathy Elmasry¹, Laila Ahmed Rashed², Reem El Darbi³

¹Dermatology Department, Faculty of Medicine, Cairo University, Egypt ²Medical Biochemistry & Molecular Biology department, Faculty of Medicine, Cairo University, Egypt ³Cairo, Egypt

BACKGROUND & OBJECTIVE: Thymic stromal lymphopoietin (TSLP) is a major pro-allergic cytokine that promotes T helper 2 responses through dendritic cell activation. Polymorphism for the TSLP gene-847C>T was found to increase susceptibility to generalized vitiligo by decreasing TSLP messenger ribonucleic acid expression levels. Our objective is to study and verify the hypothesis of the role of TSLP in the pathogenesis of vitiligo aiming to find newer therapy for vitiligo in the future.

MATERIALS & METHODS: The study was conducted on twenty-five patients with generalized non-segmental vitiligo (recruited from the Dermatology outpatient clinic, Kasr El Ainy, Faculty of Medicine, Cairo University), and twenty-five healthy controls fulfilling the inclusion criteria in a randomized controlled study over a period of 7 months (January 2017-July 2017). Patients were subjected to complete medical history, detailed assessment of vitiligo and photography taking. Skin biopsies were taken from vitiliginous skin and from normal skin of controls for which TSLP tissue levels were measured using quantitative real time polymerase chain reaction technique.

RESULTS: There was a statistically significant difference between the levels of TSLP in vitiligo patients and normal healthy controls ($P < 0.001$) with lower levels of TSLP in vitiligo patients.

CONCLUSION: Based on the fact that TSLP upregulates the T helper 2 inflammatory response and that vitiligo is considered as T helper 1-related disease, results of this study revealed lower TSLP levels in vitiliginous skin versus normal skin suggesting an imminent role of TSLP in the pathogenesis of vitiligo. Exacerbation of co-existent vitiligo is also expected in atopics treated with TSLP.

Keywords: Thymic stromal lymphopoietin, TSLP receptor, T helper-2 cells, vitiligo, pathogenesis of vitiligo

3rd INDERCOS

National Dermatology & Cosmetology Congress with International Participants

14-17 MARCH, 2018
HILTON ISTANBUL BOSPHORUS HOTEL
ISTANBUL, TURKEY



OP-10

[CUTANEOUS ONCOLOGY]

HLA TYPE DETERMINATION IN PATIENTS DIAGNOSED WITH MYCOSIS FUNGOIDES AND SEZARY SYNDROME

Ali Reza Fenjanchi¹, Burhan Engin², Muazzez Çiğdem Oba², Erkan Yılmaz³, Zekayi Kutlubay², Server Serdaroglu²

Department of Dermatology and Venerology, Usak University, Education and Research Hospital, Usak, Turkey ²Department of Dermatology and Venerology, Istanbul University, Cerrahpaşa Medical Faculty, Istanbul, Turkey ³Department of Medical Laboratory Tecnics, Istanbul University, Cerrahpaşa Medical Faculty, Istanbul, Turkey

INTRODUCTION & OBJECTIVES: Mycosis fungoides is a rare cutaneous primary T cell lymphoma characterized by patches, plaques and tumors. The purpose of our study was to investigate the relation between Mycosis fungoides and Sézary Syndrome and human leukocyte antigen (HLA) alleles, which play an important role in tumor response and immunity.

MATERIALS & METHODS: Two mililiter blood samples were taken from 30 patients with mycosis fungoides and Sézary Syndrome in the Department of Dermatology of Istanbul University Cerrahpaşa Medical Faculty. DNA was extracted in the tissue typing laboratory using the EZ1 Advanced isolation device. The HLA was determined using the Luminex Labscan 100 and One-Lambda kits.

RESULTS: 30 patients with mycosis fungoides and 30 control subjects were included in the study. In our study, HLA A31, B51, DR3 have been determined as significantly positive in our patients (Table 1). The significantly high presence of HLA-B35 and DR4 in the control group may suggest that these alleles may be protective against tumoral growth.

CONCLUSIONS: A definite connection was not found between the significant antigens in the study and the disease, but the HLA system is believed to have strong connections to mycosis fungoides.

Keywords: human leukocyte antigen (HLA), mycosis fungoides, T cell lymphoma

Table 1

	Mycosis Fungoides	Control	p< 0.05
A31	4	0	0.046
B51	13	6	0.014
DR3	7	1	0.017

Significant HLA groups in patients with mycosis fungoides



3rd INDERCOS

National Dermatology & Cosmetology Congress with International Participants

14-17 MARCH, 2018
HILTON ISTANBUL BOSPHORUS HOTEL
ISTANBUL, TURKEY

OP-11

[CORRECTIVE, AESTHETIC AND COSMETIC DERMATOLOGY] BEAUTY TREATMENTS- THE TWO SIDES OF A COIN

Neena Khanna

All India Institute of Medical Sciences, New Delhi, India

INTRODUCTION: With large number of people visiting beauty salons to improve their appearance, there is need for dermatologists to evaluate the 'pluses' as well as 'minuses' of procedures done in salons so as to validate (or refute) the claims of beauticians especially with regards to ageing and improving hair and nail health.

OBJECTIVES: To study the positive effects and adverse effects of beauty treatments provided in salons.

METHODS: Facial beauty treatment (FBT) which is touted as a procedure to rejuvenate the face consists of facial massage, steaming of the face and application of a face mask. We observed 142 women over 12 weeks after they had received a FBT. On questioning, the subjects reported rejuvenation (59.1%), suppleness of skin (53.5%) and a delay in onset of wrinkles (14.9%). However, immediately after FBT, 40% developed erythema (usually transient, sometimes persistent) and puffiness of the face and over the next 3-10 weeks a third (33.1%) of the patients developed an acneiform eruption consisting of indolent deep-seated nodules which healed with unsightly hyperpigmentation but unlike in acne vulgaris, comedones were infrequent. Interestingly, the lower part of cheeks especially along the mandible and chin were most frequently involved - these being the sites which are most vigorously massaged during FBT. Histopathologically the lesions showed dermal lymphohistiocytic, perifollicular infiltrate often with presence of polymorphs. In 43% of the biopsies, however, the infiltrate was granulomatous, a reflection of the clinical indolence of the lesions. Large areas of unwanted body hair are managed in salons by epilation by waxing. In a study to evaluate the effect of waxing, we followed up 50 women who underwent waxing. Ten percent of subjects who underwent this procedure, developed usually asymptomatic (sometimes itchy), tiny, follicular papules, often surmounted with pustules. These papules developed usually 1-2 weeks after waxing and usually subsided in another 2 weeks, but 10% of the patients had residual, discrete hyperpigmentation after subsidence of the papules. We noted that the papules were most frequently seen on the lateral aspects of the proximal part of the extremities - deltoid region in the upper extremities and lateral aspect of thighs in the lower extremities. This was probably because of the haphazard direction of hair growth in these areas compounded by the erratic direction of 'pulling off' of the waxing strips. Histopathological evaluation of these papules showed features of pseudofolliculitis and fibrosis. As we followed up these 'waxed' patients over period of time, we observed that with regular waxing, the hair growth decreased, probably because each 'episode' of waxing was associated with inflammation, followed by small amount of fibrosis which over period of time eventuated into decreased hair growth.

CONCLUSION: Procedures done in beauty salons can result in adverse effects.

Keywords: Salons, facial beauty treatment, acneiform eruption, waxing, pseudofolliculitis

3rd INDERCOS

National Dermatology & Cosmetology Congress with International Participants

14-17 MARCH, 2018
HILTON ISTANBUL BOSPHORUS HOTEL
ISTANBUL, TURKEY



OP-12

[HAIR DISORDERS/DISEASES]

A RARE CASE OF FACIAL HYPERTRICHOSIS IN FEMALES; SEGMENTAL ODONTOMAXILLARY DYSPLASIA

Salih Levent Cinar

Department of Dermatology, Erciyes University, Kayseri, Turkey

INTRODUCTION: Segmental odontomaxillary dysplasia (SOD) is a rare developmental disorder of the maxilla and the surrounding tissue. Until today a few dozens of cases of SOD have been reported in the literature. Maxillary enlargement, delayed tooth eruption, lack of some of the premolar teeth, gingival malformations and fibrous hyperplasia of the neighboring soft tissue are the most common clinical features of the disease. Some dermatological findings can also accompany these such as benign fibromas and hypertrichosis. In this oral presentation i aim to report a female patient with a diagnosis of SOD whose main complaint was the hypertrichosis of her eyelids.

CASE : A fourteen year-old female patient was referred to the Dermatology and Venereology Clinic of Erciyes University Faculty of Medicine with a complaint of hypertrichosis of her right eyelid and the dorsum of her nose. Dermatological examination revealed some intraoral abnormalities. She had gingival enlargement, dental deformities and multiple pink to red papules on her palate. She was under orthodontic treatment for the treatment of dental deformities. Her parents stated that her primary teeth had erupted when she was four years old. Extra orally, she had a slight facial asymmetry and apparent hypertrichosis of her right eyelid and the nasal dorsa. There was no additional dermatopathology. She was referred to the Erciyes University Faculty of Dentistry for a detailed dental examination. Dental examination and panoramic radiograph revealed gingival hyperplasia, hypoplasia of the premolars and slight enlargement of the maxillary bone with a sclerotic appearance. An incisional biopsy of palatal papule was performed. It was reported as fibroepithelial papilloma. Based on clinical examination and laboratory findings SOD diagnosis was made. The patient and her parents were informed about the diagnosis, benign nature and treatment options of the disease. Due to her aesthetic concern, laser hair removal and the continuation of her dental treatment was recommended.

Keywords: dental abnormality, fibroma, hypertrichosis, maxillary dysplasia



3rd INDERCOS

National Dermatology & Cosmetology Congress with International Participants

14-17 MARCH, 2018
HILTON ISTANBUL BOSPHORUS HOTEL
ISTANBUL, TURKEY

OP-13

[PSORIASIS]

ASSOCIATION BETWEEN SERUM ADROPIN AND ISCHAEMIA-MODIFIED ALBUMIN LEVELS AND PSORIASIS VULGARIS

Suzan Demir Pektas

Mugla Sitki Kocman University, Faculty of Medicine, Department of Dermatology, Mugla/TURKEY

INTRODUCTION: Psoriasis vulgaris (PV) is chronic inflammatory skin disorder. Recent studies showed that PV is reported to have a association with cardiometabolic disorders. Adropin, is important protein for energy homeostasis and maintaining insulin sensitivity. Moreover, adropin and ischaemia-modified albumin (IMA) is closely related to the development and progression of atherogenesis.

OBJECTIVE: The aim of this study was to investigate the association between serum adropin concentration and PV.

METHODS: 44 PV patients (20 males and 24 females) and 41 age and sex matched healthy individuals (23 females and 18 males) were included in the study. Demographic data, clinical features of patients, anthropometric measures, laboratory findings, and blood pressure levels were recorded. Serum adropin levels were measured using a commercial ELISA kit.

RESULTS: PV patients and healthy controls were statistically similar with respect to age and sex. PV patients had higher values for weight (72.1 ± 13.2 kg vs. 63.1 ± 7.7 kg, $p=0.001$), BMI (27.7 ± 5.2 kg/m² vs. 23.3 ± 1.4 kg/m², $p<0.001$), WHR (0.8 ± 0.1 vs. 0.77 ± 0.0 , $p<0.001$), FPG (89 ± 14.5 mg/dL vs. 83.8 ± 8.2 mg/dL, $p<0.001$), triglyceride (126.6 ± 60.2 mg/dL vs. 104.2 ± 55.5 mg/dL, $p<0.05$) and CRP (9.9 ± 3.4 mg/dL vs. 3.4 ± 0.8 mg/dL, $p<0.001$) compared to the control group. While IMA levels increased, adropin was decreased in the serum of PV patients ($p<0.001$, for both). When compared to healthy controls, PV patients with PASI ≤ 10 and PASI > 10 had significantly lower adropin levels ($p<0.05$ for all). The PV patients with PASI > 10 had significantly lower adropin than psoriasis patients with PASI ≤ 10 ($p<0.05$). In patient group, adropin was negatively correlated with duration of disease, PASI and CRP, while IMA was positively correlated with duration of disease, PASI and CRP.

CONCLUSION: There are decreased adropin and increased IMA in PV patients. Decreased adropin and increased IMA levels may have a role in the pathogenesis of increased inflammation in PV.

Keywords: Psoriasis vulgaris, adropin, ischaemia modified albumin, metabolic disorders.

3rd INDERCOS

National Dermatology & Cosmetology Congress with International Participants

14-17 MARCH, 2018
HILTON ISTANBUL BOSPHORUS HOTEL
ISTANBUL, TURKEY



OP-14

[HAIR DISORDERS/DISEASES]

EXAMINATION OF CLINICAL AND DEMOGRAPHIC CHARACTERISTICS OF 14 CASES WITH FRONTAL FIBROSING ALOPECIA

Ayşe Akbas, *Fadime Kılınc*, Ataturk Training and Research Hospital, Ankara, Turkey

INTRODUCTION: Frontal fibrosing alopecia (FFA) is a rare type of cicatricial alopecia seen in postmenopausal women characterized with band-type frontal/frontotemporal hair traction and/or significant or complete loss of the eyebrows. We aimed to present the demographic, clinical and laboratory characteristics of female patients diagnosed and followed-up with FFA in our clinic by comparing these with the literature data.

METHOD: A total of 14 patients who admitted to our outpatient clinic with alopecia on the frontotemporal/frontal hairline and were clinically and/or histopathologically diagnosed with FFA between 2011 and 2016 were evaluated in a retrospective manner. The patients were reviewed in terms of the age of lesion onset, localization, accompanying symptom or disease, and treatment options.

RESULTS : The ages of the patients who were followed-up in our outpatient clinic with FFA were between 52 and 73 (mean 2 years). Eight patients (57%) had total eyebrow loss. Laboratory tests were in normal limits or negative. Comorbidities included thyroid disease, hypertension and coronary artery disease diabetes mellitus. For treatment, all patients were given systemic, intralesional and topical steroid, and topical minoxidil at various times. Four patients received hydroxychloroquine, 2 patients acitretin, 2 patients Vitamin E, 1 patient itraconazole, and 1 patient topical tacrolimus.

CONCLUSION: FFA should be considered in middle aged and elderly postmenopausal women presenting with hair loss complaints and were detected to have frontal hairline traction and cicatricial alopecia, and the diagnosis should be supported by biopsy. Thereby, the disease progression may be prevented or delayed with early diagnosis and proper treatment.

Keywords: Cicatricial alopecia, frontal fibrosing alopecia, lichen pilonipilaris



3rd INDERCOS

National Dermatology & Cosmetology Congress with International Participants

14-17 MARCH, 2018
HILTON ISTANBUL BOSPHORUS HOTEL
ISTANBUL, TURKEY

OP-15

[GYNAECOLOGICAL D/V, GENDER D/V]

GERIATRIC DERMATOSES IN WOMEN PRESENTING TO A DERMATOLOGY OUTPATIENT CLINIC

Ragıp Ertas¹, Emin Özlü²

Department of Dermatology, Kayseri Education and Research Hospital, Health Sciences University, Kayseri, Turkey

²Department of Dermatology, Duzce University, Duzce University, Duzce, Turkey

BACKGROUND: A high number of patients present with skin problems to dermatology outpatient clinics throughout the world and most of these patients are women. There is an increase in the rate of geriatric patients throughout the world, especially Europe and therefore, more and more patients are admitted to dermatology clinics. However, there have been very few studies on dermatological diseases in the geriatric population.

OBJECTIVE: The present study was directed towards a retrospective analysis of skin disorders and their prevalence in women during the geriatric period.

METHODS: The study has a retrospective design and it was conducted in a tertiary health care hospital in central Anatolia, in Turkey, between December 2013 and December 2015. In this retrospective study directed towards determining frequencies of dermatological problems women experience, outpatient records of 12,785 women were analyzed in the geriatric age period (age 65+). A hundred and thirty-one different diseases are examined.

RESULTS: The mean age of the women was 72,25±6,36. The most frequent causes of presentations to the outpatient clinics in geriatric age period of women, were eczema and pruri simplex. Followed by actinic keratosis, xerosis cutis and tinea pedis. Fungal infection tinea pedis was the fifth most frequent dermatological disease in this age group. Distribution of the dermatological diseases which have a frequency ≥ 0,5 % in geriatric period was shown in Figure 1.

CONCLUSION: Aging is an inevitable and continuous process which affects all organ systems of the body including skin. During this process, there is a decrease in the ability of the skin to fulfill its regular functions. As a result, such inevitable changes as roughness, wrinkling, and laxity of the skin, and atypical presentations of dermatologic diseases occur in older patients. Aging related dermatological diseases have been increasing in females. This seems to be due to growth of aging population and desire for having a high quality of life. Precautions taken to reduce aging of skin and identification of aging related diseases and symptoms have become of importance. There is an increase in the rate of geriatric patients throughout the world, especially Europe and therefore, more and more patients are admitted to dermatology clinics. The current study also revealed that eczematous dermatitis and pruritus were the most frequent dermatological diseases in geriatric patients. In conclusion, the present study, which has been the largest of all reported from Turkey so far, yielded results similar to those of the previous retrospective studies. This is the first study to include only

3rd INDERCOS

National Dermatology & Cosmetology Congress with International Participants

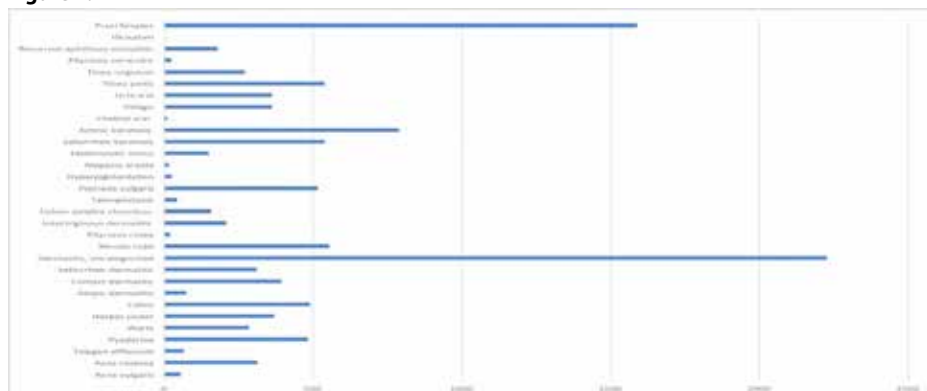
14-17 MARCH, 2018
HILTON ISTANBUL BOSPHORUS HOTEL
ISTANBUL, TURKEY



women and to reveal dermatological problems they encounter during the geriatric period of women life. As frequencies of female dermatological diseases are important for dermatology and community health, further studies about these diseases are needed.

Keywords: Women, Dermatoses, Geriatric period

Figure 1.



Distribution of the Dermatological Diseases Which Have a Frequency $\geq 0,5$ %



3rd INDERCOS

National Dermatology & Cosmetology Congress with International Participants

14-17 MARCH, 2018
HILTON ISTANBUL BOSPHORUS HOTEL
ISTANBUL, TURKEY

OP-16

[LASERS]

USING OF A PULSED DYE LASER FOR THERAPY OF CHRONIC DERMATOSES. SOME CLINICAL CASES

Alena Soha¹, Anna Sviridova¹, Silvestrs Rubins², Pier

Luigi L.m. Cornaggia Medici²

¹Era Esthetic clinic, Riga, Latvia

²Latvian Dermatology Institut, Riga, Latvia

INTRODUCTION: Pulsed dye laser (PDL) has become the treatment of choice for a number of conditions with cutaneous vascular ectasia (port-wine stains, haemangiomas), and has been used to treat rosacea-associated erythema, teleangiectasia. It is often used for many other vascular-dependent and non-vascular indications (psoriasis, postacne scars, lupus erythematoses, granuloma faciale, sarcoidosis, eczematous lesions, rosacea, lichen sclerosis, granuloma annulare). PDL (595-nm) is effective in improving the vascularity, color, height, texture of hypertrophic scars and keloids by selective damage to the microvasculature of the scar. Low fluence PDL is able to stimulate procollagen synthesis in the skin because of a nonlethal heating of dermal perivascular tissues and to improve the appearance atrophic scars. The mode of action of PDL is based on the principle of selective photothermolysis, a targeted damaging of vascular lesions through selective absorption of light by oxyhaemoglobin, while the pulse duration and cooling prevent damage to the epidermis and surrounding dermis.

MATERIALS AND METHODS: PDL (595 nm) was used for our therapeutic purposes. The objectives of this study were to evaluate the clinical effects of PDL as an additional option of treatment on rosacea, postacne scars and plaque of psoriasis.

RESULTS: In case of psoriasis PDL treatment decreased the number of dermal papillary microvessels. Dermal papillary microvessels are important pathogenetic targets of psoriasis, and PDL therapy is a valid therapeutic approach. All patients have noted reduced itching and disappearing of plaques after several sessions. The effect lasts for 6-12 months without any medication. Such parameters as 7mm, 1,5ms, 9J were used. PDL effects on the stimulation of superficial dermis collagen remodeling and improves the appearance of atrophic acne scars. We use PDL treatment as additional method for the combined treatment of postacne scars (7mm, 3ms, 6J, or 10mm, 6 ms, 10J, session interval was 4 weeks). Patients with rosacea complain of facial flushing, erythema and telangiectasia, unresponsive to topical or systemic therapy. A multimodal approach with medical and physical options is recommended. Diffuse erythema, telangiectasia of rosacea can be reduced by the use of PDL (7mm, 20ms, 14, or 12mm, 20ms, 9J, every 4-6 weeks).

CONCLUSION: Although none of the treatment options provide a complete cure, the patient's quality of life and self-esteem have significantly improved. It is important to combine different methods of etiopathogenetic treatment. The emotional state of the patients has improved considerably with the presence of compliance in subsequent treatment, which is an important factor for the success of the therapy. The use of PDL as an additional method of treatment in complex therapy of chronic dermatoses can reduce the number of steroid drugs, increase the duration of remission, improve the quality of life and skin condition of patients.

Keywords: pulsed dye laser, psoriasis, rosacea, acne

3rd INDERCOS

National Dermatology & Cosmetology Congress with International Participants

14-17 MARCH, 2018
HILTON ISTANBUL BOSPHORUS HOTEL
ISTANBUL, TURKEY



OP-17

[PSORIASIS]

THE RELATIONSHIP BETWEEN THE SEVERITY OF PSORIASIS, BODY MASS INDEX AND WAIST CIRCUMFERENCE

Nermin Karaosmanoğlu

Department of dermatology, Ankara Training and Research Hospital, Ankara, Turkey

INTRODUCTION AND OBJECTIVES: Psoriasis vulgaris is a chronic, immune-mediated, inflammatory disease of the skin. Mediators that cause chronic inflammation may increase the incidence of atherosclerosis, obesity, insulin resistance, hypertension, dyslipidemia, metabolic syndrome and type 2 diabetes mellitus in patients with psoriasis through pro-inflammatory cytokines. In previous studies, it has been shown that as the psoriasis area and score index (PASI) increases, the risk of these chronic diseases also increases.

MATERIALS-METHODS: In this study; gender, age, height, weight, body mass index (BMI) and waist circumference values of 75 psoriasis vulgaris patients who applied to our clinic were recorded. The relationship between waist circumference and BMI with PASI was then evaluated statistically.

RESULTS: A total of 75 patients, 47 men and 28 women, were included in the study. The mean age of the patients was 38,8 ($\pm 16,5$). The relationship between the PASI value, waist circumference and BMI of each patient was evaluated. There was no statistically significant relationship between PASI and BMI; while as the PASI increases, the waist circumference was found to increase statistically significantly.

CONCLUSIONS: Psoriasis vulgaris is a chronic inflammatory disease that may be associated with obesity. In this study, the finding that the waist circumference increases while PASI increases supports the thesis that raised adipocytokines with the augmentation of central obesity increases the risk of systemic inflammation and obesity suggested in previous studies. New studies in larger patient groups are needed in order to shed light on this subject.

Keywords: psoriasis, body mass index, waist circumference



3rd INDERCOS

National Dermatology & Cosmetology Congress with International Participants

14-17 MARCH, 2018
HILTON ISTANBUL BOSPHORUS HOTEL
ISTANBUL, TURKEY

OP-18

[DERMATOLOGICAL PRACTICE MANAGEMENT]

ARSENICOSIS IN BANGLADESH: DERMATOLOGICAL MANIFESTATIONS AND MANAGEMENT

Mohammad Abdul Hye

Department of Dermatology, Jalalabad Ragib-Rabeya Medical College, Sylhet, Bangladesh.

INTRODUCTION: Arsenic- a metalloid element- is a natural component of earth's crust in some parts of the world. High concentration of arsenic in drinking water are found in various parts of the world. Prior to the 1970s, Bangladesh had one of the highest infant mortality rate due to improper water purification sewage system. Millions of wells were constructed as a result. Because of this action infant mortality and diarrheal diseases were reduced by 50%. But among 8.4 million wells, approximately 1 in 5 of these wells is now contaminated with arsenic.

MATERIALS AND METHODS: Review of all the published English literature, Government and non-government project statistics and newspaper reports regarding epidemiology, pathogenesis, dermatological manifestations, social impact and management of arsenicosis.

RESULTS: It is now estimated that 67 million people in Bangladesh are exposed to 0.05 mg/ litre or above of arsenic in their drinking water and it is now considering a biggest crisis in health and social sector in the modern world. Prolong ingestion of arsenic chiefly affect skin, liver and following vital system of body like urinary, cardiovascular, and respiratory system. Many epidemiological data showed that skin involvement occur in 80% of the patients of arsenicosis with urinary excretion of arsenic value between 1-3 mg/litre. Major dermatological manifestations are arsenical melanosis, palmo-planter keratosis and Bowen's disease. There is no specific treatment of chronic arsenic toxicity in human health. Stoppage of further intake of arsenic contaminated water is the main remedy. However, many food supplements like selenium, spirulina etc are tried with good result.

CONCLUSION: In this presentation, speaker emphasizes the dermatological manifestations of arsenicosis and its management in context of Bangladesh. Author opine that arsenicosis is not only problem of few underdeveloped countries like India and Bangladesh but it is now discovered in many developed countries like USA, so physicians of all countries should be oriented about the above mentioned health problem.

Keywords: arsenic, arsenicosis, melanosis, keratosis, diagnosis, management

3rd INDERCOS

National Dermatology & Cosmetology Congress with International Participants

14-17 MARCH, 2018
HILTON ISTANBUL BOSPHORUS HOTEL
ISTANBUL, TURKEY



OP-19

[TOPICAL THERAPY]

LIPOSOME INCORPORATED CLOVE OIL IN THE TREATMENT OF IDIOPATHIC PALMAR HYPERHIDROSIS: SINGLE BLINDED PLACEBO CONTROLLED STUDY

*Ibrahim Mohammed Abdel Kareem, Ibrahim Mearag Ibrahim, Mohammed Ahmed Elghobashy
department of dermatology and venereology - Al-Azhar university - Cairo - Egypt*

INTRODUCTION: Palmar hyperhidrosis is of great concern to patients because of its physical, occupational, and psychological impact on quality of life. Topical clove oil has been used in many conditions due to its major component Eugenol that exerts blocking effect on nerve transmission.

AIM OF THE WORK: To assess the efficacy of topical liposome incorporated clove oil in decreasing the rate of sweating among patients with idiopathic palmar hyperhidrosis.

PATIENTS AND METHOD: Forty patients with palmar hyperhidrosis were treated with clove oil 45% in liposome and another twenty patients were treated as a control group with 0.9% saline solution and evaluation was carried out before and after treatment through gravimetry testing and hyperhidrosis disease severity scale (HDSS).

RESULT: The gravimetry testing among clove oil-treated group showed that the mean sweating rate before treatment was 80.5 ± 41.85 (SD) mg/min which decreased significantly after treatment to 52.98 ± 37.94(SD) mg/min (P value <.001). On the other hand, the placebo-treated group,(control) the mean sweating rate before treatment was 77.40 ± 29.29(SD) which did not show significant improvement after placebo application 77.35 ± 28.29(SD; P value =.957).

CONCLUSION: The topical application of 45% clove oil in liposome twice daily for 2 weeks showing promising result evidenced by declining in the rate of palmar sweating among patients with idiopathic palmar hyperhidrosis.

Keywords: clove oil, Eugenol, palmar hyperhidrosis



3rd INDERCOS

National Dermatology & Cosmetology Congress with International Participants

14-17 MARCH, 2018
HILTON ISTANBUL BOSPHORUS HOTEL
ISTANBUL, TURKEY

OP-20

[CUTANEOUS ONCOLOGY]

ROLE OF RADIOTHERAPY IN PALLIATIVE OUTCOME AND LOCAL CONTROL OF NON-AIDS ASSOCIATED KAPOSI'S SARCOMA

Elif Emine Ozkan¹, Selma Korkmaz²

¹Suleyman Demirel University

Department of Radiation Oncology

²Suleyman Demirel University

Department of Dermatology

BACKGROUND: There is no definite consensus on standard local or systemic treatment either for Kaposi's sarcoma (KS). Radiotherapy (RT) can be a good alternative therapeutic modality especially in non-AIDS associated KS (NAKS) for both local control and symptom palliation. In this study we aimed to investigate the therapeutic role of radiotherapy in terms of local control or symptom palliation.

MATERIALS-METHODS: Twelve KS patients treated with RT from February 2011 to January 2017 were retrospectively evaluated. Totally 17 lesions of 12 patients were treated. Localization of the lesion, field size, age, comorbidity, second primary malignancy were the variables evaluated for prognostic effect on symptom palliation or local control.

RESULTS: The median follow-up period was 38.3(7 – 120) months. Median age of the patients was 72.9 (53 – 86) years. All lesions were located at lower extremities except one which was located at elbow. Most of the patients were suffering from pain, itching and local swelling as the initial presentation. None of the patients had detected immunodeficiency. All patients but one were treated to a total dose of 30 Gy. A patient has left his treatment at 2500 cGy due to personal problems. Complete response and partial response were obtained in 13 (71.5 %) lesions in 10 patients other than 2 with short-term follow-up (< 3 months). Three of the lesions were detected as stabile where 1 has shown local progressive behavior. Symptom improvement was achieved in 10 (83.33 %) of 12 patients. Grade 2 skin toxicity was seen in 10 lesions but all was completely responsive to topical treatment. In 10 patients, subcutaneous lymphedema was reported as late toxicity. Doppler ultrasound was nonsignificant for all of these patients. Three of 12 patient were dead, none of which was KS related. When responsive, stabile and progressive patients were investigated, none of the variables were found related to symptom palliation or local control.

DISCUSSION: In AIDS-related KS, the response rate was 60% to 90% as it has a systemic and aggressive nature. On the contrary; majority of NAKS tend to behave indolent and limited to skin. So in clinical practice local treatment seems to provide adequate local control and palliation. Various local modalities such as, surgical excision, cryotherapy, intralesional vinblastine injection, alitretinoin gel, laser therapy, electrochemotherapy are also advocated other than RT. Optimal dose, appropriate timing of treatment, whether to start at the initial presentation or when symptom occurs are some of the ongoing conflicting issues about radiation treatment of NAKS. The dose schedule of fractionated RT varied from total dose of 30 Gy in 20 fractions to 8 Gy in a single fraction. Our standart RT schedule was 30 Gy in 10 fractions and symptom relief was observed in 10 of 12 patients. As conclusion; RT is an effective modality in symptom palliation or local control for NAKS regardless of any variable.

Keywords: kaposi's sarcoma, radiotherapy, local treatment

3rd INDERCOS

National Dermatology & Cosmetology Congress with International Participants

14-17 MARCH, 2018
HILTON ISTANBUL BOSPHORUS HOTEL
ISTANBUL, TURKEY



OP-21

[PSORIASIS]

SERUM AND SKIN LEVELS OF ADIPONECTIN, CARTONECTIN (CTRP-3) AND OSTEOPONTIN IN PSORIASIS VULGARIS AND EFFECT OF TREATMENT WITH METHOTREXATE

Emine Büyük¹, Zeynep Nurhan Saraçoğlu¹, Işıl Bulur¹, Funda Canaz², Evrim Yılmaz², Bilgin Kaygısız³

¹Department of Dermatology, Eskisehir Osmangazi University, Eskisehir, Turkey

²Department of Pathology, Eskisehir Osmangazi University, Eskisehir, Turkey

³Department of Pharmacology, Eskisehir Osmangazi University, Eskisehir, Turkey

BACKGROUND: Psoriasis is a chronic immune-mediated inflammatory disease associated with metabolic syndrome (MetS) and cardiovascular disorders. Many studies report that adipokines and cytokines have potential role in inflammation in psoriasis.

OBJECTIVE: The aim of this study was to investigate the relationship of adiponectin, cartonectin (CTRP-3) and osteopontin with psoriasis, independent of MetS.

METHODS: We measured baseline serum and skin levels of adiponectin, CTRP-3 and osteopontin in 41 psoriasis patients and 14 healthy controls without MetS and cardiovascular disease. The equivalent data from 19 patients who achieved PASI 75 after methotrexate treatment were also evaluated. ELISA was used to measure serum and skin samples.

RESULTS: The serum levels of adiponectin were lower in psoriasis patients compared with healthy controls but there was no statistical differences. The adiponectin levels in skin samples were significantly lower in psoriasis patients than in healthy controls. The cartonectin levels in both serum and skin samples were significantly lower in psoriasis patients compared to healthy controls. The osteopontin levels in serum were significantly higher in the post-treatment group compared to the pre-treatment group.

CONCLUSION: Adiponectin and cartonectin might have a potential rol in psoriasis pathogenesis regardless of the presence MetS. Further studies involving large scales and lacking counfounding factors such as MetS, obesity and cardiovascular disease may better identify the role of osteopontin in psoriasis.

Keywords: Psoriasis, Adiponectin, Cartonectin/CTRP-3, Osteopontin



3rd INDERCOS

National Dermatology & Cosmetology Congress with International Participants

14-17 MARCH, 2018
HILTON ISTANBUL BOSPHORUS HOTEL
ISTANBUL, TURKEY

OP-22

[INFLAMMATORY SKIN DISEASES]

EVALUATION OF ESTROGEN AND ANDROGEN RECEPTOR EXPRESSION, CLINICAL SEVERITY AND AUTOIMMUNE ASSOCIATION IN LICHEN SCLEROSIS

Fatma Uzun¹, Cem Leblebic², Ayşe Esra Koku Aksu¹, Ezgi Hacıhasanoğlu², Mehmet Salih Gürel¹

¹Department of Dermatology, İstanbul Training And Research Hospital, İstanbul, Turkey

²Department of Pathology, İstanbul Training And Research Hospital, İstanbul, Turkey

Lichen sclerosus (LS) is a chronic inflammatory dermatosis. Its etiopathogenesis has not been exactly understood. It is known that autoimmunity and hormonal factors play a role in the etiopathogenesis of the disease. The occurrence of the disease at the time when the physiological levels of estrogen are lowest in women suggests the role of sex hormones in the pathogenesis of the disease. There have been a small number of studies on androgen and estrogen receptors performed in LS.

The aim of this study was to investigate the association between sex hormones and autoimmunity in female LS patients. It was aimed to determine the expression of androgen receptor (AR), estrogen receptor alpha (ER α) and beta (ER β) in lesions of female LS patients followed up in the dermatology clinic of İstanbul Training and Research Hospital, to compare with control group and to evaluate the relation of receptor expression between disease severity and autoimmunity.

Thirty-five patients who diagnosed histopathologically and clinically with LS in the dermatology clinic of İstanbul Training and Research Hospital between January 2014 and July 2017 were included in the study. Excisional biopsy specimens with pathologically non-LS findings and with normal skin without lesions were selected as the control group. Of the 35 LS patients in the case group, in 15 patients the lesions were located extragenitally, in 13 patients anogenitally, and in 7 patients genitally + extragenitally. At least one autoantibody (ANA, anti TPO, anti TG, RF) positivity was present in 14 (40.0%) of LS patients. Twenty-three patients had an autoimmune disease history. AR, ER α and ER β expression in epidermis and dermis of case group were significantly ($p < 0.05$) lower than the control group. Significant loss was detected in AR, ER α and ER β expression in our study. It suggests that sex hormones play a role in the pathogenesis of LS.

Keywords: Autoimmunity, androgen receptor, estrogen receptor, lichen sclerosus

3rd INDERCOS

National Dermatology & Cosmetology Congress with International Participants

14-17 MARCH, 2018
HILTON ISTANBUL BOSPHORUS HOTEL
ISTANBUL, TURKEY



OP-23

[CONTACT AND OCCUPATIONAL DERMATITIS]

THE STATE OF OCCUPATIONAL DERMATOSIS IN TURKEY

Şafak Metekoğlu¹, Mehmet Melikoğlu², Semih Güder³, İlteriş Oğuz Topal⁴

¹Department of Dermatology, Beyazıt Medico-Social Center, Istanbul University, Istanbul, Turkey

²Department of Dermatology and Venerology, Ataturk University School Of Medicine, Erzurum, Turkey

³Department of Dermatology, Istanbul Occupational Diseases Hospital, Istanbul, Turkey

⁴Department of Dermatology, Okmeydanı Training and Research Hospital, Istanbul, Turkey

We would like to review occupational disease in Turkey in this study and we share collected knowledge.

Due to the difficulties in diagnosing occupational diseases and deficiencies in statistical data, occupational diseases are underreported in Turkey. The average number of records in our country is around 10, when at least 100,000 new occupational skin diseases need to be diagnosed annually. This is due to the shortcomings in the diagnosis and notification of the occupational disease in our country. In this study, we analyzed occupational skin diseases and their ICD codes, and how they are diagnosed medically and legally, and the difficulties in diagnosing these diseases. The article emphasises that the dermatologists should be trained in occupational diseases and occupational health code in order to improve diagnosing and reporting occupational diseases.

Given the fact that the incidence of occupational diseases in working population ranges between 4 and 12 per thousand according to the data of ILO (International Labour Organisation), it can be concluded that 100,000 to 300,000 workers suffer from an occupational disease annually in Turkey. Considering the long average working hours and the prevalence of insecure and flexible working conditions in Turkey, it is more likely that the expected annual number of occupational diseases would be about 300,000. 2, 3

According to statistical data of SSI for the period 2009-2015 in Turkey, the number of legally diagnosed occupational skin diseases is very limited 8 (Table 3). Given the fact that the annual average number of occupational diseases has been reported to be about 500 in the period 2009-2015 and on average, 30% of these must have been skin diseases, the annual number of occupational skin diseases diagnosed legally must be at least 150. In addition, as the expected annual number of newly diagnosed occupational diseases in working population of Turkey is 300,000, the annual number of newly diagnosed occupational skin diseases must be minimum 100,000. However, this was reported as low as 17 even in 2011 when the number of occupational diseases diagnosed reached to the maximum.

In conclusion, there appear to be some problems with the occupational diseases, their prevention, communication and statistics in our country. Effective protection programs require a multidimensional approach. Therefore, a common approach taken by the employees, employers, union representatives, safety engineers and occupational physicians is important. 9 We believe that there is a need for many studies for diagnosis and prevention of occupational dermatologic diseases and promising progress may be achieved by the verbal or written information studies and meetings to be conducted by the dermatology societies.

Keywords: Occupational skin diseases, occupational dermatosis, occupational diseases



3rd Indercos

National Dermatology & Cosmetology Congress with International Participants

14-17 MARCH, 2018
HILTON ISTANBUL BOSPHORUS HOTEL
ISTANBUL, TURKEY

OP-24

[TOPICAL THERAPY]

TOPICAL POLYPHENOL TREATMENT OF SACROCOCYGEAL PILONIDAL SINUS DISEASE: USE OF ULTRASONOGRAPHY TO EVALUATE RESPONSE TO TREATMENT - CLINICAL CASE SERIES STUDY

Hasan Mete Aksoy¹, Berna Aksoy², Ezgi Özkur³, Emel Çalıkoğlu⁴

¹Bahcesehir University, Faculty of Medicine, Department of Plastic and Reconstructive Surgery, Istanbul, Turkey

²Bahcesehir University, Faculty of Medicine, Department of Dermatology, Istanbul, Turkey

³Health Sciences University, Sisli Etfal Training and Research Hospital, Department of Dermatology, Istanbul, Turkey

⁴Near East University, Faculty of Medicine, Department of Dermatology, Nicosia, Cyprus

BACKGROUND: Sacrococcygeal pilonidal sinus disease (SPSD) is a common disorder and encountered more frequently in hairy young males after puberty. PSD is associated with a requirement for hospitalization and is a cause of considerable loss of productivity.

OBJECTIVE: The aim of this study is to assess effectiveness of topical polyphenol treatment of PSD by using physical examination and ultrasonography. USG was performed to achieve high sensitivity in evaluating treatment results.

METHODS: Fourteen patients with PSD diagnosis were treated with two natural polyphenol product forms and were included in this study. Retrospective analysis of patient files were performed. All of the patients in this study were assessed by superficial ultrasonography before and after treatment. Demographic and clinical information of the patients were obtained from medical records.

RESULTS: The disease duration in fourteen PSD patients aged 18-45 years was median 2 years. The most common findings in physical examination were sinus openings and subcutaneous nodules at the pre-treatment clinical visit. The most common ultrasonographic findings were abscess/cyst formation and presence of fistula at the pre-treatment visit. All of the patients applied topical polyphenols for a mean 3.8 months. Topical polyphenol treatment was effective in 92.9% of patients. In 3 patients (21.4%) disease recurred after a mean 12.3 months. Follow up examinations performed in mean 18.3 months revealed that 12 patients (85.7%) were free of disease. Control physical examination and ultrasonographic assessment were completely normal in 11 patients (78.6%).

CONCLUSION: Topical polyphenol therapy is a promising alternative treatment for PSD. It is advised that topical polyphenols should be tried first in every young and active patient with PSD. Majority of these patients can avoid demanding and expensive alternative treatment methods such as complex surgical procedures.

Keywords: Pilonidal sinus, polyphenol, topical, treatment

3rd INDERCOS

National Dermatology & Cosmetology Congress with International Participants

14-17 MARCH, 2018
HILTON ISTANBUL BOSPHORUS HOTEL
ISTANBUL, TURKEY



OP-25

[SEXUALLY TRANSMITTED INFECTIONS, HIV/AIDS]

NEUROSYPHILIS IN THE DIFFERENTIAL DIAGNOSIS OF NEUROPSYCHIATRIC DISORDERS

Betül Şerefliçan¹, Şule Aydın Türkoğlu²

¹Department of Dermatology, Abant İzzet Baysal University, Bolu, Turkey

²Department of Neurology, Abant İzzet Baysal University, Bolu, Turkey

INTRODUCTION: Syphilis is a sexually transmitted disease caused by *treponema pallidum*. Neurological involvement is one of the most important manifestations of syphilis. Typically, neurosyphilis is observed in late-stage syphilis, but neuroinvasion and neurological disease may appear in both early and late syphilis. The clinical spectrum includes ischemic cerebrovascular disease, meningitis, meningovascular disease and late manifestations of syphilis such as tabes dorsalis and paraesthesia. In recent years, many studies have been conducted about the HIV negative syphilis patients, especially those with neurological symptoms. This study aimed to investigate neurological manifestations of HIV-negative syphilis patients.

MATERIAL AND METHODS: For this study, seven male and seven female patients who admitted to the neurology clinic along with VDRL and TPHA positivity were examined. The neuropsychiatric findings of these patients were researched.

RESULTS: The average age of the patients was 72 years. There were 11 patients with ischemic cerebrovascular disease. There were 12 patients with dementia and 3 patients with parkinsonism.

DISCUSSION: Here we present 14 patients with varying neuropsychiatric complaints, diagnosed with neurosyphilis during diagnostic work-up. We wanted to draw attention to neurosyphilis via the cases with neurological manifestations such as ischemic cerebrovascular disease, dementia, parkinsonism and neuropsychiatric findings. Syphilis can be overlooked and left untreated.

CONCLUSION: Neurosyphilis is a rare disease that should be kept in mind during the differential diagnosis of neurological and psychiatric disorders.

Keywords: Syphilis, VDRL, TPHA, neurosyphilis

Table 1

gender	M	M	M	M	M	M	M	F	F	F	F	F	F	F
age	74	56	72	72	81	58	88	61	72	76	81	84	58	74
stroke	+	+	+	+	+	-	+	+	-	+	+	+	+	-
dementia	+	-	+	+	+	+	-	+	+	+	+	+	+	+
parkinsonism	-	-	-	-	+	-	-	-	+	-	-	-	-	+

Demographic and clinical features of neurosyphilis cases



3rd Indercos

National Dermatology & Cosmetology Congress with International Participants

14-17 MARCH, 2018
HILTON ISTANBUL BOSPHORUS HOTEL
ISTANBUL, TURKEY

OP-26

[ANGIOLOGY, HAEMANGIOMAS, VASCULAR MALFORMATIONS, VASCULITIS] OCULAR BEHÇET'S DISEASE - TWO TREATMENT METHODS FOR TWO SEVERE CASES

Özgür Gündüz¹, Nesrin Büyüktortop Gökçınar², Nurgül Örneş²

¹Department of Dermatology, Kırıkkale University, Kırıkkale, Turkey

²Department of Ophthalmology, Kırıkkale University, Kırıkkale, Turkey

INTRODUCTION: Depending upon the population studied, ocular involvement can be observed about in 25 - 75% of patients with Behçet's Syndrom (BS). Ocular disease of BS may manifest itself usually through bilateral, episodic (pan)uveitis. Anterior uveitis (with hypopyon), posterior uveitis, retinal vasculitis, vascular occlusion, retinal vasculitis are other forms of ocular involvement seen in BS. Particularly, posterior uveitis, retinal vasculitis, optic neuritis are critical conditions which may easily progress to blindness. In this presentation, clinical follow-up of two patients with BS will be described. Both of the patients presented with very mild mucocutaneous symptoms, but found to have severe ocular involvement.

Case 1

A 24-year-old male patient presented with blurred vision. He also complained recurrent oral aphtae. At the time of his first visit, no other symptom suggestive of BS was present. Ophthalmologic examination revealed vitreous hemorrhages and fundus fluorescein angiography (FFA) showed fern-like pattern, suggestive of BS. (Fig 1). Hemorrhages were acutely treated with laser photocoagulation and then subcutaneous interferon injections were started. About six months there were no progression of ocular involvement and blurred vision was completely gone.

Case 2

A 19-year-old male patient presented with recurrent oral aphtae, scrotal cutaneous ulcers. At the time of his first visit, he did not mention any ocular symptoms. Routine ophthalmological consultation revealed retinal ischemia and also neovascularisations (Fig 3). He was started on systemic steroid + cyclophosphamide + azathioprin. 2 months later, retinal ischemia and neovascularisations were regressed (Fig 4).

CONCLUSIONS: Severe ocular involvement in patients with BS may be observed in the setting of a mild mucocutaneous disease. Routine eye controls should not be neglected and as BS is usually diagnosed, treated and followed-up in dermatology clinics, dermatologists should have an up to date knowledge of the systemic treatment methods for ocular BS.

Keywords: Behçet's Syndrom, Ocular Involvement, Neovascularisation of Optic Disc, Interferon, Cyclophosphamide

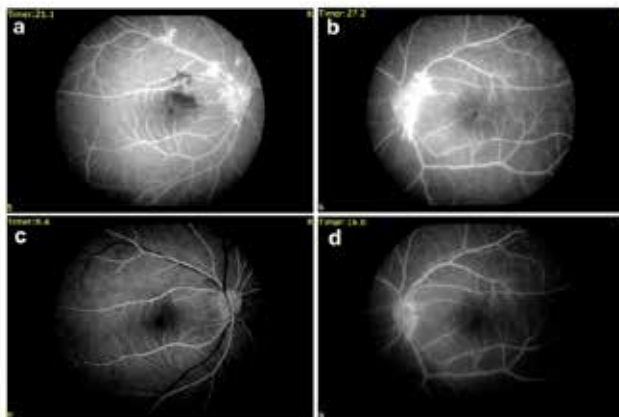
3rd INDERCOS

National Dermatology & Cosmetology Congress with International Participants

14-17 MARCH, 2018
HILTON ISTANBUL BOSPHORUS HOTEL
ISTANBUL, TURKEY

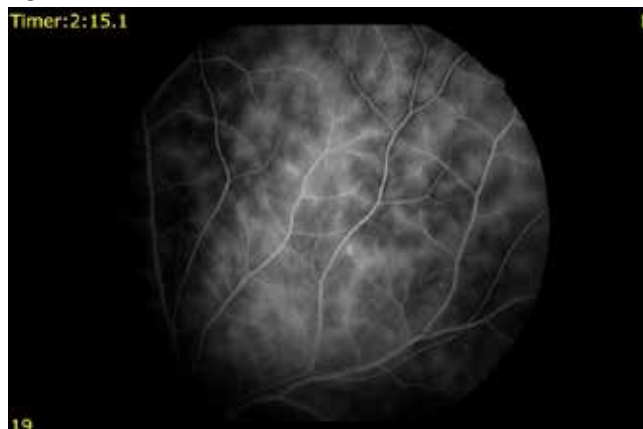


Figure 1



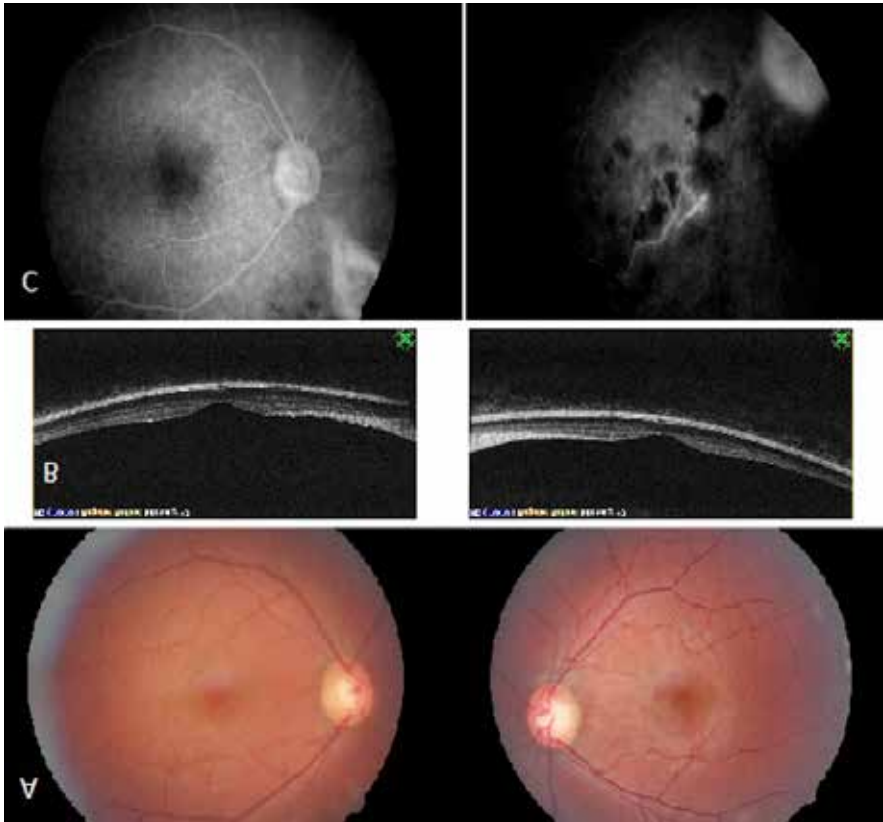
Case 1. 24-year-old male patient with blurred vision. Fundus Fluorescein Angiography (FFA) at the first visit; (a) Neovascularisation at disc (NVD) and neovascularisation elsewhere (NVE) in the right eye (b) NVD in the left eye. 6 months later; (c) Remission of neovascularisation and active hemorrhages in the right FFA (d) NVD with decreased intensity in the left FFA and retinal laser spots.

Figure 2



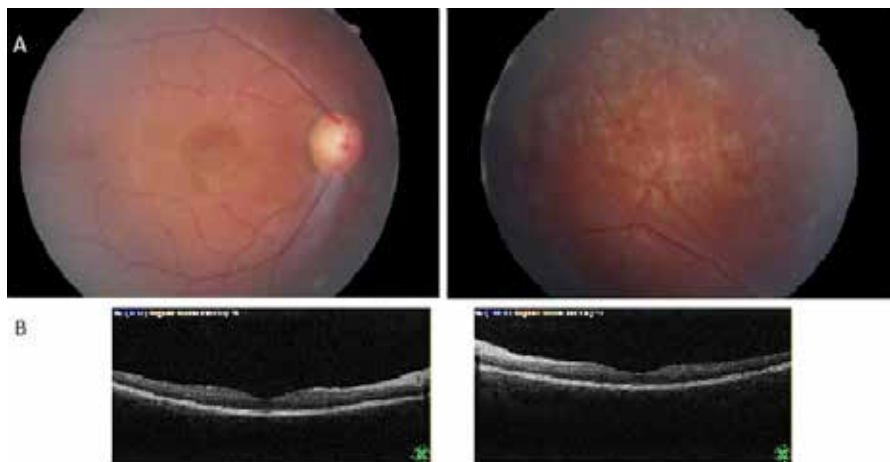"Fern-like pattern" seen on FFA.

Figure 3



(a) Color photograph of fundus, right and left eyes. Right macular pucker, normal left fundus. (b) Macular optical coherence tomography, right and left eyes. Creases on right maculopapillary region, normal left macula. (c) FFA, right eye. NVE can be seen as hypofluorescence on the nasosuperior quadrant relative to the optic nerve. Distal to the NVE, ischaemic retina can be seen.

Figure 4



Control after 2 months. (a) Color photography of fundus, right and left eyes. Normal right macula and retina. After laser photocoagulation of ischaemic areas in the superior and superiortemporal regions. NVE can not be seen. (b) Macula optic coherence tomography, right and left eyes. Normal right and left macula.



3rd INDERCOS

National Dermatology & Cosmetology Congress with International Participants

14-17 MARCH, 2018
HILTON ISTANBUL BOSPHORUS HOTEL
ISTANBUL, TURKEY

OP-27

[AUTOIMMUNE CONNECTIVE TISSUE DISORDERS]

CUTANEOUS AND SUBCUTANEOUS 18F-FDG PET/CT FINDINGS IN 195 SARCOIDOSIS PATIENTS

Effrosyni D Manali¹, Alexandros Georgakopoulos², Nikoletta K Pianou², Lykourgos Kolilekas³, Ioanna Korbila¹, Georgia Papadaki¹, Aneza Roussou¹, Paschalina Giouleka¹, Andriana I Papaioannou¹, Evaggelia Papadavid⁴, Sofia Chatziioannou², Spyros Papiris¹

¹2nd Pulmonary Medicine Department, Attikon University Hospital, Medical School, National and Kapodistrian University of Athens, Greece

²Biomedical Research Foundation of the Academy of Athens, Nuclear Medicine Division, Athens, Greece

³7th Pulmonary Department, Sotiria Chest Hospital, Athens Greece

⁴2nd Department of Dermatology, Attikon University Hospital, Medical School, National and Kapodistrian University of Athens, Greece

INTRODUCTION: 18F-fluoro-2-deoxyglucose (18F-FDG) positron emission tomography (PET) computed tomography (CT) has been reported useful in estimating active inflammatory sites in sarcoidosis, pulmonary and extrapulmonary, even when clinically and physiologically silent. Cutaneous lesions are one of the commonest manifestations of sarcoidosis and are equally detected by detailed observation of the skin, physical examination and by increased 18F-FDG uptake.

OBJECTIVE: To evaluate the role of 18F-FDG PET/CT in detecting cutaneous and subcutaneous sites of involvement in sarcoidosis and to associate these findings with pulmonary disease and treatment decisions.

METHODS: All consecutive sarcoidosis patients referred to us between 01/2012 and 06/2017 were investigated. Epidemiologic, demographic, clinical, radiographical, functional, laboratory and treatment data were recorded. After informed consent, all patients underwent 18F-FDG PET/CT for evaluation of both thoracic and extrathoracic disease activity and extent.

RESULTS: One hundred ninety five patients, a median age (IQR) of 51 years (41-60), 101 (51.8%) female were included in the study. Cutaneous and subcutaneous increased 18F-FDG uptake was detected in 24 (12.3%) and 27 (13.8%) patients respectively, whereas 36 patients overall had a positive history of dermal disease. The most common sites of increased skin 18F-FDG uptake were the lower extremities: thighs, knee joints, cnemis and ankles followed by the trunk and gluteal regions. One patient presented with lesions of the face including the areas around the nose and the ears. Skin lesions were associated with the detection of subdermal nodules of the same anatomical site in 58.3% of patients, whereas 7.6% of patients presented subdermal lesions alone. In the majority of patients dermal (92%) and subdermal (96.2%) lesions were associated with active pulmonary disease (lymph nodes, parenchymal disease or both) in 18F-FDG PET/CT. No gender predilection was observed. Plaques and papules were the most commonly encountered lesions involving 1-2 and very rarely up to 5 sites, creating interesting patterns

3rd INDERCOS

National Dermatology & Cosmetology Congress with International Participants

14-17 MARCH, 2018
HILTON ISTANBUL BOSPHORUS HOTEL
ISTANBUL, TURKEY



of cutaneous involvement on 18F-FDG PET/CT. Several lesions mimicked psoriasis. Tissue biopsy was performed in all cases to document diagnosis and guide accurate treatment based on expert dermatological evaluation. In a median (IQR) follow-up of 34 (19-46) months, 2 patients presented persistent cutaneous disease besides treatment and one patient with a history of dermal sarcoidosis developed new skin lesions proved to be a neoplasm of the skin.

CONCLUSIONS: Based on 18F-FDG PET/CT cutaneous and subcutaneous sarcoidosis develop in the majority of cases in association with active pulmonary disease. Besides interesting patterns of increased cutaneous 18F-FDG uptake expert dermatological evaluation and tissue biopsy should guide diagnosis, clinical and therapeutic decisions.

Keywords: sarcoidosis, cutaneous, subcutaneous, 18F-FDG PET/CT



3rd INDERCOS

National Dermatology & Cosmetology Congress with International Participants

14-17 MARCH, 2018
HILTON ISTANBUL BOSPHORUS HOTEL
ISTANBUL, TURKEY

OP-28

[HAIR DISORDERS/DISEASES]

A NUCLEOSIDE REVERSE TRANSCRIPTASE INHIBITOR-INDUCED DYSTROPHIC ANAGEN ALOPECIA

Betül Tas¹, Kamuran Turker²

¹Department of Dermatology, Health Science University, Istanbul Bagcilar Research and Training Hospital, Turkey

²Department of Infectious Diseases, Health Science University, Istanbul Bagcilar Research and Training Hospital, Turkey

INTRODUCTION: Nucleoside reverse transcriptase inhibitors (NRTIs) are current antiviral (AV) drugs used in the treatment of hepatitis B (HBV) infections. Entecavir (ETV) is a NRTI, which inhibits reverse transcription and DNA replication. We report a 47-year-old woman with a female-pattern dystrophic anagen effluvium (DAE), which was developed under the ETV therapy.

METHODS: The lesion of the patient was evaluated with the medical-history, clinical, laboratory, trichological and histopathological examination findings.

RESULTS: The patient was diagnosed with chronic HBV infection, 6 months ago (HBsAg, anti-HBeAg and anti-HBc were positive. HBV DNA level was 6380 IU/ml. In the liver biopsy, hepatic activity index (HAI) was 4/18, and disease stage was 2/6), and began to be treated with ETV 0.5 mg/day, p.o. HL began one and a half months after the therapy. Laboratory examinations including complete blood count, glucose, glycated hemoglobin, iron, total iron binding capacity, ferritin, vitamin B12, vitamin E, folic acid, zinc, 25-hydroxy-vitamin D3, 1-25-dihydroxy-vitamin D3, IgG subtypes, thyroxine, triiodothyronine, thyroid stimulated hormone, anti thyroid autoantibodies, FSH, LH, progesterone, DHEA-S, SHBG, prolactin, testosterone, parathormone and complement levels (C3, C4) all were within the normal values, or age and sex compatible levels. Dermatological examination revealed a female-pattern androgenetic alopecia (FPAA) of Ludwig stage-2 (Fig 1). There were no exclamation mark hairs, scaling, erythema, scarring, atrophy and induration. Dermoscopic examination showed a lot of miniaturized hairs. Hair pull test was positive. In the forcible hair pluck test, the ratios of dystrophic-anagen, anagen, telogen and catagen hairs were 54%, 30%, 14% and 2%, respectively. The distal part of the hairs were pointed, discoloured and curled. (Fig 2). Histopathology showed a moderate perifollicular lymphocytic infiltration including some eosinophils, dominance of dystrophic anagen follicles, normal anagen and telogen follicles at the second and third frequencies, and few catagen follicles in the dermis (Fig 3). Because other causes that can lead to HL were excluded, the lesion was diagnosed ETV-induced DAE. After the patient was informed, the antiviral therapy was changed to tenofovir disoproxil fumarate. The patient is in the 19th month of new therapy, and still following. During this time no progress in HL was observed.

CONCLUSIONS: Cutaneous manifestations of NRTIs have been described as nail and mucocutaneous pigmentations, hair color changes, vasculitis, and morbilliform eruptions. Besides the pegilated

3rd INDERCOS

National Dermatology & Cosmetology Congress with International Participants

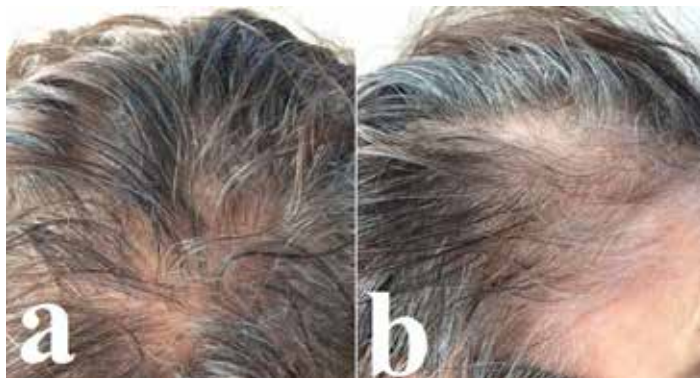14-17 MARCH, 2018
HILTON ISTANBUL BOSPHORUS HOTEL
ISTANBUL, TURKEY



interferons, only few and non-detailed AV-associated alopecia reports that related with two NRTIs (lamivudine and didanosine) have been reported. To the best of our knowledge, this is the first report about ETV-associated DAE. The possibility of development of DAE must be kept in mind, when especially in patients receiving AV therapy with NRTIs.

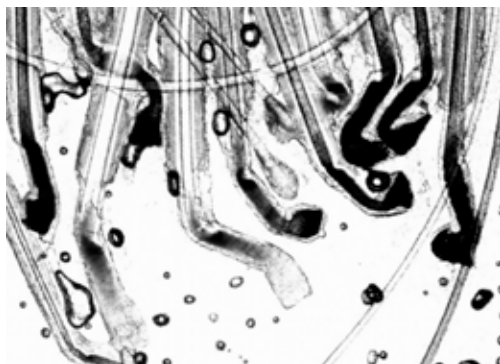
Keywords: Adverse effect, alopecia, anagen, dystrophic, entecavir

Figure 1



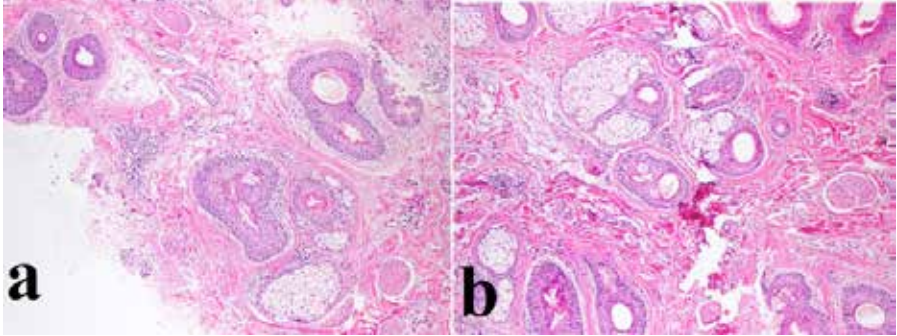
Clinical views of alopecia of the patient (a. top of the scalp, b. right side)

Figure 2



Dominance of dystrophic anagen follicles and a few telogen hairs on trichogram (X40).

Figure 3



Moderate perifollicular lymphocytic infiltration including some eosinophils, dominance of dystrophic anagen follicles with dystrophic changes (a.HEX100, b.HEX100).

3rd INDERCOS

National Dermatology & Cosmetology Congress with International Participants

14-17 MARCH, 2018
HILTON ISTANBUL BOSPHORUS HOTEL
ISTANBUL, TURKEY



OP-29

[LASERS]

HAIRY THROAT: A CASE REPORT

Meghna Sharma¹, Rakesh Gautam²

¹Neoskin Laser Clinic, Punjab, India

²MMU, Haryana, India

HAIRY THROAT: A CASE REPORT

Anterior cervical hypertrichosis or “Hairy throat” is a rare form of localized hypertrichosis that refers to the presence of a tuft of terminal hair on the anterior neck. Mostly, ACH occurs as an isolated finding. It can, however be associated with systemic findings like neurological defects (peripheral neuropathy, developmental delay, mental retardation), ophthalmological disorders (optic atrophy and chorioretinal changes), hallux valgus and dorsal hypertrichosis. As per our knowledge, only 40 cases of ACH have been reported worldwide. Primary generalized hypertrichotic conditions may be easily recognizable but primary localized hypertrichotic conditions like ACH may be overlooked/undiagnosed and hence underreported. We present an eleven year old girl who presented with ACH as an isolated finding. The girl was brought by her parents to the OPD as she had started getting stressed out because of her condition since the last few months. After adequate counseling and informed consent, the girl was taken up for diode laser hair reduction. There was satisfactory and noticeable improvement right from the first session.

Primary hypertrichotic conditions are rare in paediatric patients and of unknown origin. They may be benign but add to significant cosmetic disfigurement and psychosocial discomfort. Patients and their families should be counselled and offered both temporary and permanent methods of hair reduction/removal.

Keywords: Anterior cervical, hypertrichosis, laser,



3rd INDERCOS

National Dermatology & Cosmetology Congress with International Participants

14-17 MARCH, 2018
HILTON ISTANBUL BOSPHORUS HOTEL
ISTANBUL, TURKEY

OP-30

[DERMOSCOPY]

SKIN MANIFESTATIONS IN COMMON RHEUMATOLOGIC DISEASES IN PEDIATRIC POPULATION

Melike Kibar Öztürk¹, İlkin Zındancı¹, Betül Sözeri²

¹Department of Dermatology, Umraniye Training and Research Hospital, Istanbul, Turkey

²Department of Child Rheumatology, Umraniye Training and Research Hospital, Istanbul, Turkey

INTRODUCTION: Specific skin lesions can be the hallmark of certain common rheumatologic diseases while it is not always easy to perform skin biopsy in pediatric population to differentiate skin involvement of a rheumatologic disease so skin findings in rheumatologic diseases can both help dermatologists and rheumatologists.

OBJECTIVE: Our aim was to alert clinician to detect these skin, nail and scalp findings in a patient with rheumatic disease to help to diagnose and follow up the disease course and possible adverse skin reactions to the systemic drugs.

MATERIALS AND METHODS: Nineteen patients with juvenil idiopathic arthritis (JIA), five patients with familial mediterranean fever (FMF), five patients with scleroderma (SSc), three patients with systemic lupus erythematosus (SLE), and three patients with dermatomyositis (DM) were included in this study. The complete medical data of patients diagnosed with these disorders between September 2017 and December 2017 were examined. The age, sex, duration of disease, site and type of lesions on skin, nails and scalp and systemic drug use of patients prior to admission were recorded.

RESULTS: A total of 35 patients were admitted to the hospital with a diagnosis of rheumatologic disease between September 2017 and December 2017. Thirteen (37.1%) males and 22 (62.8%) females, with an age range of 3–16 years and a mean age of 11.6 years included in this study. The duration of the diseases ranged between 1 and 10 years (mean 2.5 years). Plaque psoriasis was the most common type of psoriasis in JIA, was as well the most frequent type in our study. Psoriatic lesions in JIA were smaller, thinner and less scaling than adult psoriasis and tend to develop more often on the face and flexural areas. The scalp was also frequently involved and often the first site of presentation in children in our cases. Distal onycholysis was the most common nail finding of JIA in our cases. In our study, all three patients with SLE showed photosensitivity, malar rash, subtle nailfold capillary abnormalities and non-scarring alopecia clinically. Common skin findings of DM like photosensitivity, violet poikiloderma, Gottron's papules, distinct nailfold abnormalities, nail fold erythema and cuticular dystrophy were seen in all three patients with DM in our study. Distinct nailfold changes like prominent large, tortuous capillaries and areas of marked avascularity were as well seen in patients with DM in our study. Patients with SLE were having more subtle nailfold capillary abnormalities than do patients with scleroderma or dermatomyositis. In our study almost all the patients with FMF showed signs of atopy; xerosis, pityriasis alba, periorbital hyperpigmentation, leukonychia punctata and pitting. Three of the patients with FMF suffered from anagen effluvium.

Keywords: juvenil idiopathic arthritis, familial mediterranean fever, scleroderma, systemic lupus erythematosus, dermatomyositis

3rd INDERCOS

National Dermatology & Cosmetology Congress with International Participants

14-17 MARCH, 2018
HILTON ISTANBUL BOSPHORUS HOTEL
ISTANBUL, TURKEY



OP-31

[SYSTEMIC TREATMENT]

EFFECTS OF OMALIZUMAB ON THE HEMATOLOGICAL AND INFLAMMATORY PARAMETERS IN PATIENTS WITH CHRONIC SPONTANEOUS URTICARIA

Ersoy Acer¹, Hilal Kaya Erdoğan¹, Nihan Yüksel Çanakçı¹, Zeynep Nurhan Saracoğlu¹, Muzaffer Bilgin²

¹Department of Dermatology, Ekisehir Osmangazi University, Eskisehir, Turkey

²Department of Biostatistics, Ekisehir Osmangazi University, Eskisehir, Turkey

INTRODUCTION: Omalizumab is a human monoclonal anti-Ig E autoantibody used in the treatment of chronic spontaneous urticaria. In this study, we aimed to evaluate the effects of omalizumab on hematological and inflammatory parameters in chronic spontaneous urticaria patients.

MATERIAL-METHODS: One hundred and twelve (76 females and 30 males) chronic spontaneous urticaria patients treated with omalizumab were evaluated retrospectively. Complete blood count and C reactive protein (CRP) levels of the patients before the treatment and at the third month of treatment were recorded.

RESULTS: The mean age of the patients was 45.02 ± 12.50 (min: 19, max: 78). A statistically significant decrease was observed in the white blood cell, platelet, neutrophil counts, CRP, neutrophil-lymphocyte ratio, platelet-lymphocyte ratio. A statistically significant increase was observed in the eosinophil count, mean platelet volume, eosinophil-lymphocyte ratio, eosinophil-neutrophil ratio. An increase was observed in basophil count but it was not statistically significant.

CONCLUSIONS: It can be thought that our results support anti-inflammatory and anti-coagulant effects of the omalizumab treatment in chronic spontaneous urticaria patients.

Keywords: eosinophil, lymphocyte, neutrophil, omalizumab, platelet, urticaria



3rd Indercos

National Dermatology & Cosmetology Congress with International Participants

14-17 MARCH, 2018
HILTON ISTANBUL BOSPHORUS HOTEL
ISTANBUL, TURKEY

OP-32

[TOPICAL THERAPY]

COMPARISON OF TOPICAL 3% DICLOFENAC GEL AND 5% IMIQUIMOD CREAM IN THE TREATMENT OF ACTINIC KERATOSIS: CLINICAL AND HISTOPATHOLOGICAL STUDY

Fatma Tunçöz Akyürek¹, Mukadder Koçak², Pınar Atasoy³, Ahu Birol Kocaalp⁴, Mehmet Ali Can Emeksiz⁵, Gülcan Saylam Kurtipek¹

¹Department of Dermatology Selçuk University, Konya, Turkey

²LOSANTE Child and Adult Hospital, Ankara, Turkey

³Kırıkkale University Faculty of Medicine Department of Pathology, Kırıkkale, Turkey

⁴Lifemed Medical Center, Istanbul, Turkey

⁵Keciören Private Hospital Clinics of Dermatology, Ankara, Turkey

INTRODUCTION: Actinic keratoses (AKs) are relatively common premalignant lesions which affect large proportion of individuals with light skin that has been exposed to sun and/or artificial UV radiation. There are many treatment alternatives, both surgical and topical, in the treatment of AKs. However, determining effective and well-tolerated treatment is also important for patient comfort. In this study, we aimed to evaluate the clinical and histopathological efficacy of topical diclofenac sodium and imiquimod for the treatment of AKs.

METHODS: Twenty patients aged between 38-83 years and had a clinical and histopathological diagnosis of AKs were included in the study. At the initiation visit, photographs were taken from patients and skin biopsy samples were taken from lesional areas of the skin by a 3mm punch biopsy tool. Subjects who had histopathological confirmed, AKs were randomized to apply imiquimod or diclofenac sodium cream for 2 months. In order to decrease the error rates, pre and post-treatment punch biopsy samples were evaluated using classification of keratinocyte intraepithelial neoplasia (KIN) by the same pathologist.

RESULTS: The mean age of the patients in the imiquimod group were 56.70 ± 14.74 years and 58.60 ± 10.70 years for the diclofenac group respectively. There was no statistically significant difference in age, sex distribution and skin type between imiquimod and diclofenac group ($p=0.745$, $p=1.00$ and $p=1.00$, respectively). At the baseline, the numbers of total lesions in the imiquimod group were 4.5 ± 2.63 and 8.30 ± 6.41 for the diclofenac group respectively. After 2-month treatment period, these numbers had declined to 1.80 ± 1.22 (median 1.50) for the imiquimod group and 4.60 ± 6.88 (median 3.00) for the diclofenac group. There was no statistically significant difference in numbers of total lesions between two groups before the treatment and after the 2-month treatment period ($p=0.100$, $p=0.222$). There was significant clinical improvement in both groups at 2-month treatment visit compared with the baseline ($p=0.025$, $p=0.005$). A significant histopathological improvement was observed at 2-month treatment period compared with the baseline (imiquimod $p=0.004$, diclofenac $p=0.008$). There was no statistically significant difference in histopathological analysis between two groups before the treatment and after 2-month treatment ($p=0.789$, $p=0.198$).

3rd INDERCOS

National Dermatology & Cosmetology Congress with International Participants

14-17 MARCH, 2018
HILTON ISTANBUL BOSPHORUS HOTEL
ISTANBUL, TURKEY



DISCUSSION: Although there are many studies comparing the clinical and histological efficacy of imiquimod and/or diclofenac with placebo in the literature, there are no studies comparing the two topical therapies for AKs both clinically and histopathologically. In our study, we investigated the efficacy of the two drugs clinically and histopathologically. We showed that both drugs are effective in clinical and histopathological improvement of AKs after the therapy. We believe that the multicenter longer follow-up studies are performed with more patients may provide more significant results.

Keywords: Actinic keratosis, topical 3% diclofenac sodium, topical 5% imiquimod

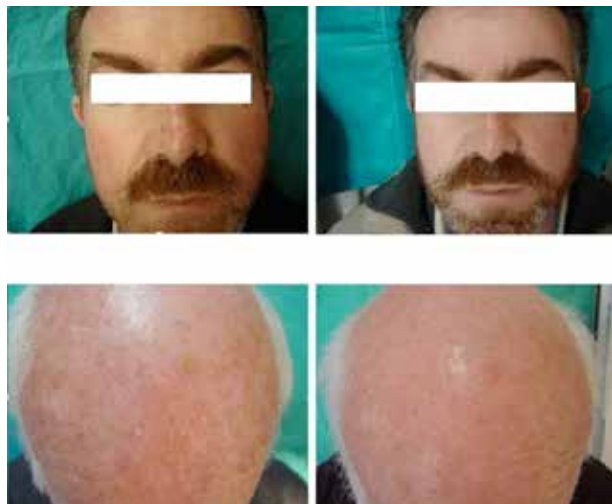Table 1

	Diclofenac (n = 10)	Imiquimod (n = 10)	p value
Age, Years			
Mean±SD	58.60±10.70	56.70±14.74	0.745
Interval	46-78	38-83	-
Gender, n (%)			
Male	4 (40%)	4 (40%)	1
Female	6 (60%)	6 (60%)	1
Skin type, n (%)			
II	3 (30%)	3 (30%)	1
III	7 (70%)	7 (70%)	1

SD, standard deviation

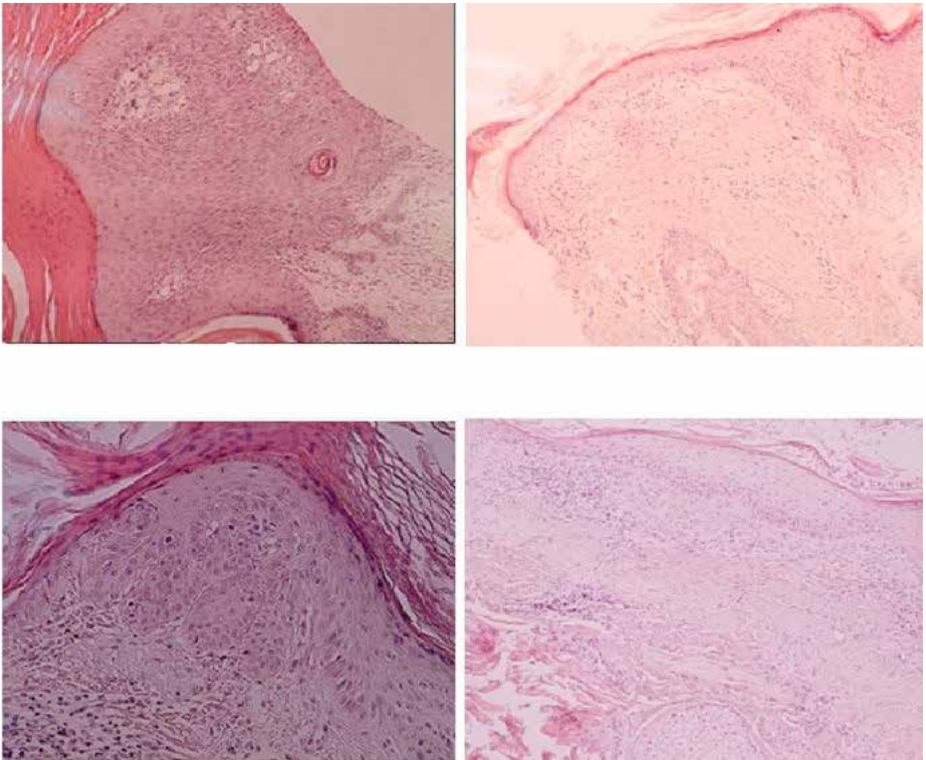
Demographic data of patients

Figure 1



Upper row: before treatment (left) and after treatment with imiquimod (right).
Lower row: before treatment (left) and after treatment with diclofenac (right).

Figure 2



Upper row: H&E, objective x100; before treatment (left) and after treatment with imiquimod (right). Lower row: before treatment (left) and after treatment with diclofenac (right).

3rd INDERCOS

National Dermatology & Cosmetology Congress with International Participants

14-17 MARCH, 2018
HILTON ISTANBUL BOSPHORUS HOTEL
ISTANBUL, TURKEY



Table 2

	Diclofenac	Imiquimod	p value
Number Lesions (Mean±SD)			
Baseline	8.30±6.41	4.50±2.63	0.1
1.Month	6.0±6.39	4.30±2.11	0.435
2.Month	4.60±6.88	1.80±1.22	0.222
p value			
Baseline-1.month	0.018	0.943	
Baseline-2.month	0.005	0.008	
KIN, n (%)			
Pre-treatment			
Grade I	0 (%0)	1 (%10)	
Grade II/a	3 (%30)	0 (%0)	
Grade II/b	5 (%50)	8 (%80)	
Grade III	2 (%20)	1 (%10)	
Post-treatment Resolution	1 (%10)	3 (%30)	
Grade I	6 (%60)	6 (%60)	
Grade II/a	2 (%20)	0 (%0)	
Grade II/b	1 (%10)	1 (%10)	
Grade III	0 (%0)	0 (%0)	
p value Pre-post treatment	0.008	0.004	

Clinical and histological finding before and after treatment

Figure 3

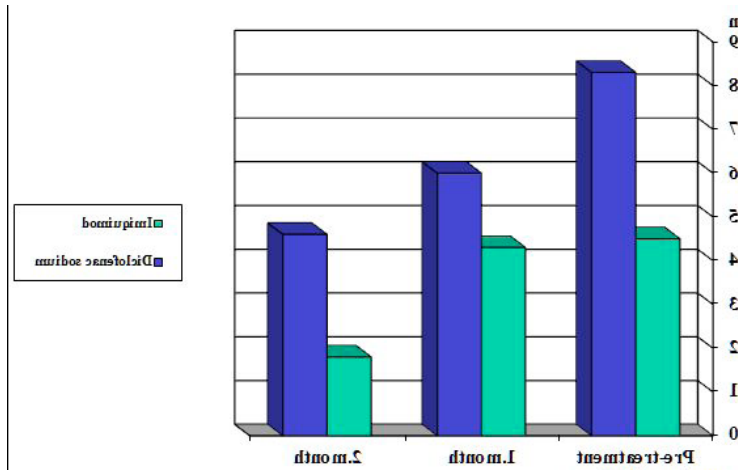
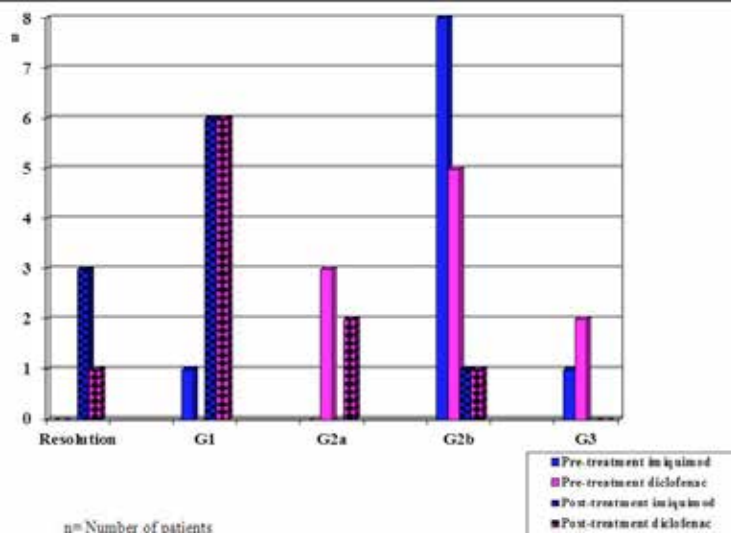


Figure 4



3rd INDERCOS

National Dermatology & Cosmetology Congress with International Participants

14-17 MARCH, 2018
HILTON ISTANBUL BOSPHORUS HOTEL
ISTANBUL, TURKEY



OP-33

[NAIL DISORDERS/DISEASES]

CLINICAL AND DEMOGRAPHICAL CHARACTERISTICS AND TREATMENT OUTCOMES OF DIGITAL MYXOID PSEUDOCYSTS

Fatih Göktay, Güldehan Atış

Department of Dermatology, University of Health Sciences, Haydarpaşa Numune Training and Research Hospital, İstanbul, Turkey

INTRODUCTION AND OBJECTIVES: Digital myxoid pseudocysts (DMP) or mucous cysts are relatively common lesions of the fingers. The lesions are usually localized on the proximal nail fold (PNF) and dorsal or lateral regions of the distal interphalangeal joint (DIJ) as a single translucent or normochromic nodule. The purpose of this retrospective study was to evaluate clinical and demographical features and treatment outcomes in patients with DMP.

MATERIAL-METHODS: Thirty patients with 31 DMPs were included into the study retrospectively. Clinical data were obtained on the gender, age of patients, duration of lesions, dermatological examination findings, family history, presence or absence of trauma history, localization of lesions, treatment methods, follow up duration and presence of recurrence were recorded.

RESULTS: Of the 30 patients, 17 patients (56.7 %) were female and 13 patients (43.3 %) were male. The mean age of the patients was 57.7 ± 9.58 . Symptoms were pain and swelling ($n=8$, 25.9 %), swelling ($n=8$, 25.9 %), swelling and nail plate changes ($n=7$, 22.4 %), and nail plate changes ($n=2$, 6.4 %). Only one patient (3.3 %) has trauma history. The mean duration of symptoms was 9.83 ± 9.16 months. No patient had family history. Lesions were located on the right hand third finger ($n=8$, 25.9 %), on the right hand second finger ($n=5$, 16 %), on the left hand second finger ($n=4$, 12.8 %) and on the left hand third finger ($n=4$, 13.2 %). The localizations of lesions were PNF ($n=24$, 74.4 %), DIJ ($n=4$, 12.8 %), PNF and DIJ ($n=1$, 3.2 %), lateral nail fold ($n=1$, 3.2 %) and nail bed ($n=1$, 3.2 %). Dermatological examination revealed single normochromic nodule on the proximal nail fold ($n=5$, 16 %), single translucent nodule on the proximal nail fold ($n=3$, 9.6 %), single normochromic nodule on the proximal nail fold with nail plate crumbling ($n=3$, 9.6 %), single ulcerated normochromic nodule on the proximal nail fold ($n=2$, 6.4 %). Of the 31 lesions, 21 (68 %) lesions were excised, 5 lesions (16 %) were treated with drainage and digital compression, 2 lesions (6.4 %) were aspirated and 3 lesions (9.6 %) were not treated. 15 patients (50 %) had follow up data. The mean duration of follow up was 5.56 ± 2.28 months. Recurrence was observed in 3 lesions (20 %).

CONCLUSION: Not uncommonly, the dermatologists encounter patients with DMP seeking treatment for the complaints of pain, swelling and nail changes in their clinical practice. Lesions can be successfully treated by excision, and drainage and compression. However, it should be kept in mind that recurrences may be seen after treatment.

Keywords: digital myxoid pseudocysts, mucous cysts, nail disorder,



3rd INDERCOS

National Dermatology & Cosmetology Congress with International Participants

14-17 MARCH, 2018
HILTON ISTANBUL BOSPHORUS HOTEL
ISTANBUL, TURKEY

OP-34

[HAIR DISORDERS/DISEASES]

IS THERE A RELATIONSHIP BETWEEN HAIR LOSS AND CEPHALALGIA?

Serkan Demirkan¹, Murat Alpua²

¹Department of Dermatology and Venerology, Kırıkkale University, Kırıkkale, Turkey

²Department of Neurology, Kırıkkale University, Kırıkkale, Turkey

INTRODUCTION: It is thought that oxidative stress may play an important role in migraine and tension type headache. It is also stated that oxidative stress may be effective in the formation of androgenetic alopecia and telogen effluvium. Upon seeing a headache complaint in some of the patients who applied to the dermatology outpatient clinic with the complaint of hair loss, it was wondered whether this was a meaningful coexistence or a coincidence. Because oxidative stress is thought to be an important point in the process both alopecia and headache. In this study, it is aimed to have knowledge about whether there is a relationship between alopecia and headache.

METHODS: Digital trichoscopic findings of patients who complained of hair loss in the dermatology outpatient clinic were examined and evaluated by a neurologist in terms of complaints of headache. Headache was diagnosed according to the International Headache Committee Classification Criteria. Digital trichoscopic findings of patients who complained of hair loss in the Kırıkkale University dermatology outpatient clinic were examined and evaluated by a neurologist in terms of complaints of headache.

RESULTS: This prospective clinical study was conducted between 2016 and 2017 in accordance with the tenets of the Declaration of Helsinki. The trial protocol was approved by the Local Ethical Committee of the Kırıkkale University. Trial registration was requested on February 9, 2016 (decision no:03/03). All patients and control subjects voluntarily participated in the study and signed an informed consent form prepared according to the ethical protocol. A total of 200 subjects, 114F, 86M) were included in the study.

CONCLUSION: Each type of hair loss has unique trichoscopic findings. In the literature, cases of regional headache accompanied by hair loss are presented. However, there was no study of the relationship between headache and hair loss. Emotional stress is an important factor, especially in tension-type headaches. The emotional state of a person with hair loss can be affected badly, thinking that this is pathological. It is stated that high emotional stress is involved in the etiology of telogen effluvium. Emotional stress is also the most important factor for tension-type headache.

Keywords: telogen effluvium, androgenetic alopecia, alopecia areata, cephalalgia, migraine, tension type headache

3rd INDERCOS

National Dermatology & Cosmetology Congress with International Participants

14-17 MARCH, 2018
HILTON ISTANBUL BOSPHORUS HOTEL
ISTANBUL, TURKEY



OP-35

[ATOPIC DERMATITIS/ECZEMA]

HIGH FREQUENCY OF IRRITABLE BOWEL SYNDROME IN PATIENTS WITH ATOPIC DERMATITIS

Mehmet Unal

Department of Dermatology and Venerology, Selçuk University, Konya, Turkey

INTRODUCTION & OBJECTIVES: The association between allergy and IBS has remained controversial for many years. For example, patients with food allergy were reported to exhibit a high prevalence of IBS and allergic disease. In addition, mast cells have a crucial role in atopy and also, mast cells may play a unique role in patients with irritable bowel syndrome (IBS). This common features between atopy and IBS suggest a link between atopic dermatitis and IBS.

MATERIALS & METHODS: Fifteen patients clinically diagnosed with atopic dermatitis and 15 controls without any atopy findings were included in this study. The diagnosis of IBS was made according to the Rome III criteria. Also, symptoms which are not essential for the diagnosis, but their presence increases the confidence of diagnosis such as; abnormal stool frequency, abnormal stool form, abnormal stool passage, passage of mucus, bloating or feeling of abdominal distension were asked to participants.

RESULTS: Of the patients participating in the study, 10 (66.6%) were female and 5 (33.4%) were male. There were 10 (66.6%) females and 5 (33.4%) males in the control group. IBS was detected in 11 patients (73.3 %) in atopic dermatitis group and 4 individuals (26.6 %) in control group. IBS was more common in atopic dermatitis group and this difference was statistically significant ($p < 0.05$).

CONCLUSIONS: Patients with atopic dermatitis have a high frequency of IBS, suggesting a link between atopic dermatitis and IBS. High frequency of IBS in atopic dermatitis patients deserves more researches. I think that understanding the links between atopic dermatitis and IBS may help in identifying the underlying pathophysiologic mechanisms and therapeutic options.

Keywords: atopic dermatitis, atopy, irritable bowel syndrome



3rd INDERCOS

National Dermatology & Cosmetology Congress with International Participants

14-17 MARCH, 2018
HILTON ISTANBUL BOSPHORUS HOTEL
ISTANBUL, TURKEY

OP-36

[AUTOIMMUNE BULLOUS DISEASES]

A RARE PEMPHIGUS VARIANT: PEMPHIGUS HERPETIFORMIS

Handan Bilen

Department of Dermatology, Ataturk University, Erzurum, Turkey

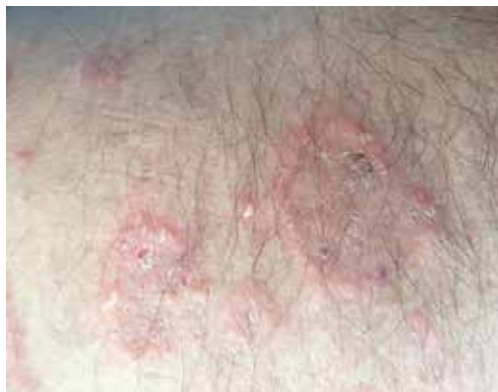INTRODUCTION: Pemphigus herpetiformis (PH) is a rare variant of pemphigus. PH is characterized by clinical features that resemble dermatitis herpetiformis (DH), bullous pemphigoid and linear IgA bullous dermatosis and immunological and histological findings consistent with pemphigus. The diagnosis of PH is rarely suspected in the first evaluation of the patient because clinical presentation is usually atypical. PH has a relatively benign course and good response to treatment with dapsone. A case of PH is reported here because of its rarity and in order to emphasize the importance of suspicion for its diagnose.

CASE: A 58-year-old male patient presented with history of a generalized, highly pruritic, erythematous-edematous annular plaques, with overlying vesicles and crusts localised mainly on his scalp, trunk and limbs (Figure 1) for 3 months. Intense pruritus tends to be especially at night. The mucous membranes were unaffected. Histological examination of a skin biopsy taken from a vesicle revealed intraepidermal neutrophilic pustules with neutrophilic and eosinophilic exocytosis (Figure 2). Direct immunofluorescence (DIF) revealed intra-epithelial and intercellular deposition of IgG (Figure 3) and C3, in a pemphigus pattern, but not stained with IgA. Peripheral eosinophilia was noted. Serum antidesmoglein 1 and 3 levels were in normal range. Additional biochemical and other laboratory findings were normal. Based on clinical, histopathological and immunological findings, PH was diagnosed. After the detection of normal levels of glucose-6-phosphate dehydrogenase, treatment with oral dapsone (100 mg/day) was planned.

CONCLUSION: This case is found worth to be presented for being a rare form of pemphigus that called PH. Diagnosis of PH requires a high index of suspicion and is made on clinical findings (urticated erythema, grouped vesicles) in the context of compatible histology and immunofluorescence findings. A physician have to keep in mind PH that has better prognosis than pemphigus vulgaris but presents challenges in diagnosis.

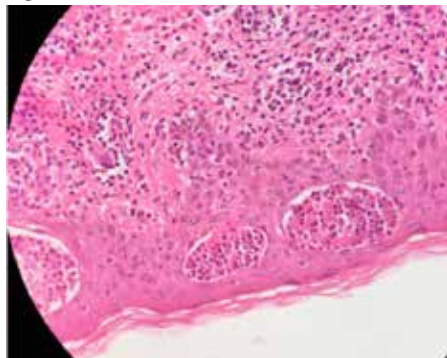
Keywords: pemphigus herpetiformis, histopathology, differential diagnosis

Figure 1



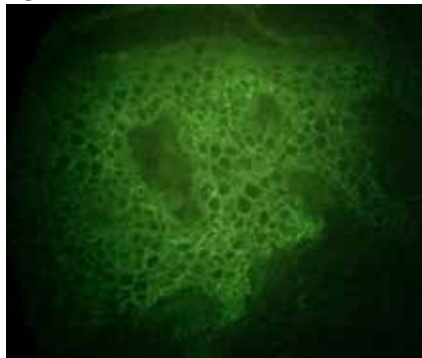
Erythematous annular plaques, with overlying herpetiform vesicles and crusts localised on trunk

Figure 2



Intraepidermal neutrophilic pustules with neutrophilic and eosinophilic exocytosis

Figure 3



Intercellular deposition of IgG in a pemphigus pattern



3rd INDERCOS

National Dermatology & Cosmetology Congress with International Participants

14-17 MARCH, 2018
HILTON ISTANBUL BOSPHORUS HOTEL
ISTANBUL, TURKEY

OP-37

[ACNE AND RELATED DISORDERS, HIDRADENITIS SUPPURATIVA]

EVALUATION OF THE RELATIONSHIP BETWEEN SEVERITY OF DISEASE IN ACNE VULGARIS AND DIETARY FACTORS WITH BODY MASS INDEX

Ömer Kutlu, İlknur Balta, Hatice Meral Ekşioğlu

Department of Dermatology and Venereology,

Health Sciences University Ankara Health Training and Research Centre, Ankara, Turkey

OBJECTIVE: It is aimed to investigate the effect of body mass index (BMI) and dietary factors in patients with acne and also the relationship between dietary factors and acne severity. Methods Two hundred two consecutive patients with acne and 172 patients with insect bite, verruca vulgaris, callus as a control group were recruited from the dermatology outpatient clinic. The mean BMI values and dietary habits were statistically compared between two groups. The relationship between acne severity and dietary habits was also statistically evaluated for acne group. Global Acne Grading System and Global Acne Severity Scale were used for acne severity.

RESULTS: The mean body mass index of the acne group was $21,99 \pm 3,36$ (minimum 16,30-maximum 38,76) and control group was $21,84 \pm 3,53$ (minimum 14,65-maximum 33,20). Significant differences in the body mass index were not observed between two groups ($p > 0,05$). The risk for acne was detected increased in those consuming more than 3 servings per week for cola (Odds ratio (OR) 1,57; 1,00-2,46), milk powdered nescafe (OR 1,67; 1,03-2,72), white cheese (OR 1,63; 1,00-2,65) and 1 serving per week for peanut (OR 1,62; 1,02-2,58). On the other hand, the risk for acne was found decreased in those consuming more than 3 servings per week for chicken meat (OR 0,65; 0,43-0,99), macaroni (OR 0,59; 0,37-0,95), and 1 serving per week for sausage (OR 0,60; 0,38-0,94) ($p < 0,05$). Acne severity was found to be significantly higher in those who consumed high-glycemic index foods.

CONCLUSION: In this study, significant difference in the body mass index were not observed between acne and control groups. Consumption of low-medium glycemic index foods such as cola, milk powdered nescafe, white cheese and peanut increased in acne group. Acne severity was found higher in those who consumed high-glycemic index foods.

Keywords: acne, body mass index, dietary factors

3rd INDERCOS

National Dermatology & Cosmetology Congress with International Participants

14-17 MARCH, 2018
HILTON ISTANBUL BOSPHORUS HOTEL
ISTANBUL, TURKEY



OP-38

[RESEARCH IN D/V, EXPERIMENTAL D/V]

INTRALESIONAL VITAMIN D3 INJECTION IN THE TREATMENT OF COMMON WARTS: SINGLE-BLINDED PLACEBO -CONTROLLED STUDY

Ibrahim Mohammed Abdel Kareem

Department of Dermatology and Venereology - Al-Azhar university - Cairo - Egypt

INTRODUCTION: Warts are common viral infection of the skin, usually treated with destructive methods like electrocautery, cryocautery or laser ablation. Topical vitamin D have been used to treat warts with variable success

AIM OF THE WORK: is to evaluate the efficacy of intralesional vitamin D3 injection in the treatment of common warts.

PATIENTS AND METHOD: Fifty patients were divided into two groups: thirty patient as cases group who received intralesional injection of 0.2 ml of vitamin D3 (300.000 IU) into the base of mother wart for two sessions and another twenty patients as a control group who were injected with normal saline solution. Standardized photographs were taken before, one month and three months after the procedure. The degree of the response was classified into complete, partial and no response.

RESULT: Complete clearance of target warts occurred in 40% of patients in cases group and only in 5% of patients in control group ($P \leq 0.001$) that was statistically significant.

CONCLUSION: intralesional injection of vitamin D3 may be considered a good and safe modality to treat common warts.

Keywords: warts, vitamin D, verruca.



3rd INDERCOS

National Dermatology & Cosmetology Congress with International Participants

14-17 MARCH, 2018
HILTON ISTANBUL BOSPHORUS HOTEL
ISTANBUL, TURKEY

OP-39

[PSORIASIS]

EVALUATION OF SERUM NETRIN-1 AND ISCHAEMIA-MODIFIED ALBUMIN LEVELS IN PSORIASIS PATIENTS

Suzan Demir Pektas

Mugla Sıtkı Kocman University, Faculty of Medicine, Department of Dermatology, Mugla/TURKEY

INTRODUCTION: Psoriasis is a common, chronic, recurrent, inflammatory disease of the skin with unknown etiology. According to physical/psychological examinations, the quality of life is affected from psoriasis as much as other chronic diseases like cancer or diabetes. Netrins, a family of laminin-related molecules, have been proposed to act as guidance cues the establishment of the vascular system. Netrin-1 was proposed to play a role in developmental/pathological angiogenesis. Ischaemia-modified albumin (IMA) constitutes via the modification in albumin and it has a important role in progress inflammation and atherogenesis.

OBJECTIVE: The purpose of this study is to investigate the netrin-1 and IMA levels in patients with psoriasis and its relation with demographic data, clinical features of psoriasis patients, anthropometric measures, laboratory findings, and blood pressure levels in patients with psoriasis.

METHODS: Forty-four patients (20 males and 24 females) and forty-one age and sex matched healthy individuals (23 females and 18 males) were included in the study. Demographic data, clinical features of patients, anthropometric measures, laboratory findings, and blood pressure levels were recorded. Serum netrin-1 and IMA levels were evaluated using commercial ELISA kit.

RESULTS: Psoriasis patients and healthy controls were statistically similar with respect to age and sex. Psoriasis patients had higher values for BMI (27.7 ± 5.2 kg/m² vs. 23.3 ± 1.4 kg/m², $p < 0.001$), FPG (89 ± 14.5 mg/dL vs. 83.8 ± 8.2 mg/dL, $p < 0.001$), triglyceride (126.6 ± 60.2 mg/dL vs. 104.2 ± 55.5 mg/dL, $p < 0.05$) and CRP (9.9 ± 3.4 mg/dL vs. 3.4 ± 0.8 mg/dL, $p < 0.001$) compared to the control group. IMA levels were increased ($p < 0.05$), while netrin-1 levels were decreased in the serum of psoriasis patients ($p < 0.001$). When compared to healthy controls, psoriasis patients with PASI ≤ 10 and PASI > 10 had significantly lower netrin-1, ($p < 0.05$). The netrin-1 levels of patients with PASI > 10 and PASI ≤ 10 were statistically similar. Netrin-1 was negatively correlated with BMI, duration of disease, PASI and CRP in patient group, while IMA was positively correlated with duration of disease, PASI and CRP in patient group.

CONCLUSION: We founded that decreased netrin-1 and increased IMA levels in psoriasis patients. Decreased netrin-1 and IMA levels may have a role in the inflammation of psoriasis.

Keywords: Psoriasis, netrin-1, ischaemia modified albumin, inflammation

3rd INDERCOS

National Dermatology & Cosmetology Congress with International Participants

14-17 MARCH, 2018
HILTON ISTANBUL BOSPHORUS HOTEL
ISTANBUL, TURKEY



OP-40

[ACNE AND RELATED DISORDERS, HIDRADENITIS SUPPURATIVA] EFFECTS OF ISOTRETINOIN ON THE HAIR CYCLE

Zeynep Gizem Kaya İslamoğlu¹,

Hilmi Cevdet Altınyazar² ¹Zeynep Gizem Kaya İslamoğlu, Department of Dermatology, Faculty of Medicine, Selcuk University, Konya, Turkey

²Hilmi Cevdet Altınyazar, Yüzüncü Yıl Hospital, Department of Dermatology, Ankara, Turkey

BACKGROUND / OBJECTIVES: Isotretinoin is a synthetic vitamin A agent that affects all of the pathogenic factors that suppress sebum production and play a role in the formation of acne. It is frequently used in the treatment of moderate-severe acne vulgaris. However, there are some mucocutaneous and systemic side effects that limit the use of isotretinoin. In this study, we aimed to determine the effect of isotretinoin on hair growth parameters.

MATERIAL-METHODS: Isotretinoin treatment at 0.5 mg / kg / day dose was started to patients with moderate- severe acne vulgaris and hair growth parameters were evaluated before treatment and after 3 months of treatment. Parameters were measured by Fotofinder dermatoscopy device using the TrichoScan Professional program.

RESULTS: In the TrichoScan analysis, the total hair count, hair density, percentage of anagen and telogen hair, density, count and ratio of vellus and terminal hairs in the 0.73 area were calculated. As a result, there were differences in some values between the first analysis and the second analysis. However, these differences were not statistically significant.

CONCLUSION: Our study was based on the mucocutaneous side effects of isotretinoin which are telogen effluvium and thinning hair. Our results support that the drug does not alter hair growth parameters in the short term and when very high doses are not used.

Keywords: Acne Vulgaris, Isotretinoin, Hair, TrichoScan.



3rd INDERCOS National Dermatology & Cosmetology Congress with International Participants

14-17 MARCH, 2018
HILTON ISTANBUL BOSPHORUS HOTEL
ISTANBUL, TURKEY

OP-41

[ALLERGOLOGY AND IMMUNOLOGY]

EVALUATION OF THE SKIN PRICK TEST AND SERUM TOTAL IGE RESULTS IN CHRONIC SPONTANEOUS URTICARIA AND ATOPIC DERMATITIS

Abdurrahman Arslan¹, İşıl Bulur²,

Zeynep Nurhan Saraçoğlu³

¹Department of Dermatology,
Medical Park Hospital, Bursa, Turkey

²Department of Dermatology, Memorial Ataşehir Hospital, İstanbul, Turkey

³Department of Dermatology, Eskisehir Osmangazi University, Faculty of Medicine, Eskişehir, Turkey

BACKGROUND: Chronic spontaneous urticaria and atopic dermatitis are common chronic skin disorders in the population with an unclear etiology and complex ethiopathogenesis. The skin prick test is a skin test containing standardized allergen extracts and demonstrating the presence of specific IgE in tissue.

OBJECTIVE: The aim of our study was to demonstrate the prevalence of allergy to food allergens and aeroallergens with the skin prick test in urticaria patients and to compare the results with atopic dermatitis patients.

MATERIAL-METHOD: We included a total of 59 chronic spontaneous urticaria and 41 atopic dermatitis patients who had presented to Eskişehir Osmangazi University Faculty of Medicine's Skin and Venereal Disease outpatients clinic in the study. A skin prick test series including food allergens (16) and aeroallergens (12) was administered to both groups and the serum total IgE level was determined in the serum samples obtained.

RESULTS: The most commonly positive allergens in the chronic spontaneous urticaria group in order of frequency were house dust mites, grass pollen mixture, oranges, carrots, cocoa and cow's milk. We found sensitization to at least one allergen in 31 (52.5%) and the serum total IgE level was elevated in 29 (49.1%) of the 59 chronic urticaria patients. The most commonly positive allergens in the atopic dermatitis group were house dust mites, grass pollen mixture, wheat flour, cat hair, carrots, nuts and peanuts. Sensitization to at least one allergen was found in 33 (80.5%) and the serum total IgE was elevated in 19 (46.3%) of the 41 atopic dermatitis patients. No difference was found between the two groups for mean serum total IgE level ($p>0.005$).

CONCLUSION: Allergen sensitivity was found in both groups, although it was more prominent in the atopic dermatitis patients. We believe that it is important to evaluate the skin prick test results and serum total IgE levels in also chronic spontaneous urticaria patients for the purpose of treating the disorder and preventing exacerbations.

Keywords: Chronic spontaneous urticaria, atopic dermatitis, skin prick test, IgE

3rd INDERCOS

National Dermatology & Cosmetology Congress with International Participants

14-17 MARCH, 2018
HILTON ISTANBUL BOSPHORUS HOTEL
ISTANBUL, TURKEY



OP-42

[DERMATOLOGICAL PRACTICE MANAGEMENT]

EPSTEIN-BARR VIRUS INFECTION AND BACTERIAL INFECTION WITH URTICARIAN VASCULITIS SHOWS SAME CUTANEOUS CLINICAL MANIFESTATIONS IN TWO DIFFERENT CHILDREN PATIENTS

Mehmet Melikoğlu,

Hatice Gencer Başol, Şevki Özdemir

Atatürk University School of Medicine Department of Dermatology and Venerology, Erzurum Turkey

Epstein-Barr virus (EBV) is a disseminated herpesvirus that is spread by intimate contact. EBV is the primary agent of infectious mononucleosis (IM), persists asymptomatically for life in nearly all adults, and is associated with the development lymphomas, nasopharyngeal carcinomas in some patients. Acute infectious mononucleosis is the best known acute clinical manifestation of EBV and its often begins with malaise, headache, and mild fever before the more specific signs of tonsillitis and pharyngitis, cervical lymph node enlargement and tenderness, and moderate to high fever. Affected patients usually have peripheral blood lymphocytosis, composed in large measure of atypical lymphocytes. Clinical manifestations of urticaria and histopathological evidence of cutaneous leukocytoclastic vasculitis of the small vessels together known the entity of the Urticarial vasculitis. Urticarial vasculitis is mostly idiopathic, on the other hand it can occur in related with autoimmune diseases, drug reactions, infections, or malignancy. We across the problems in diagnosis most of the times because of the lack of accepted criteria for distinguishing Urticarial vasculitis from other cutaneous vasculitides and similiar conditions. We treated two children in our clinic with similiar cutaneous conditions. but one of them is diagnosed Epstein-Barr virus infection and other one the bacterial infection and urticarian vasculitis. It is so important that bacterial etiology with urticarian vasculitis treated with mainly antibiotics and corticosteroids but corticosteroids contraendicated in patients with Epstein-Barr virus infections. This is so important issue that we have to careful to for right diagnoses. And we always check the viral markers especially at risk groups and children.

Keywords: Epstein-Barr virus infection, Urticarial vasculitis, cutaneous rash

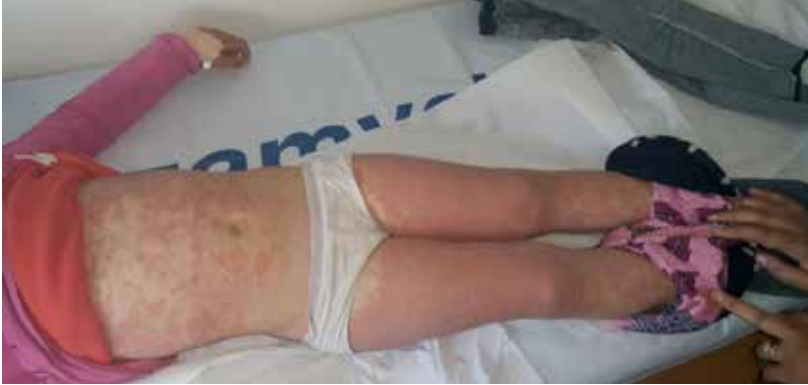

3rd INDERCOS

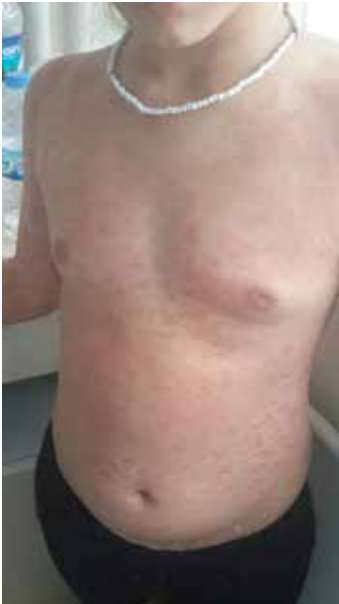National Dermatology & Cosmetology Congress with International Participants

14-17 MARCH, 2018
HILTON ISTANBUL BOSPHORUS HOTEL
ISTANBUL, TURKEY

EBV infection



Urticarian Vasculitis



3rd INDERCOS

National Dermatology & Cosmetology Congress with International Participants

14-17 MARCH, 2018
HILTON ISTANBUL BOSPHORUS HOTEL
ISTANBUL, TURKEY



OP-43

[PIGMENTARY DISEASES]

COULD LOW IRON AND VITAMIN LEVELS BE A CAUSE OF FAILURE IN MELASMA TREATMENT

Zeynep Topkarcı¹, Mehmet Melikoğlu², Abdulmuttalip Aslan³

¹Ministry of Health of Turkey Bakırköy Sadi Konuk Training and Research Hospital, Department of Dermatology and Venerology, Istanbul Turkey

²Atatürk University School of Medicine Department of Dermatology and Venerology, Erzurum Turkey

³Ministry of Health of Turkey Erzurum Training and Research Hospital, Department of Internal Medicine, Erzurum Turkey

Melasma is an acquired hyperpigmentation of the skin that typically affects the face due to sun exposure. There are many kinds of topical, oral, and procedural therapies have been used to treat melasma but not enough successful, today available treatments for melasma are unsatisfactory. We can find many different treatment methods in the literature but we would like to evaluate that why we have not succeed and relaps after these treatments.

In our study we were collected recurrent and relapses 47 female melasma patients in our outpatient clinic. All patients had received various treatment before applying to us. Nearly half of them 24 patients recieved treatment before more than two different kinds. Included laser treatment or chemical peeling or Kligman's trio and topical monotherapy. Patients according to evaluated thyroid disease, oral contraceptives use, hormonal therapy, phototoxic or anticonvulsant drugs use, iron deficiency anemia, B12 deficiency, vitamin D deficiency. A detailed history regarding the demographic profile, medical history and medical examination were performed in cases. We found out all patients ferritin level lower or low limit range. Serum ferritin levels were found to be lower in patients of melasma ranging between 2.1-50.6 (10.06) than normal. Recently many study show us that for the hair and skin health similiar the Dr Kantor and friends study that mean ferritin levels should not lower than 60 ng/ml. In our study hemoglobin levels were not found to significantly lower in patients of melasma (11.8). Except one of them in all patients serum iron level were lower than normal. We were found in 8 (nearly%6) patients B12 deficiency, and all patients were vitamin d deficiency and 5 of them were thyroid disease. And three patients had hormonal drug history. We replaced the iron, vitamin d in nearly all. We have replaced B12 in 8 patients. On the other hand we ordered tretinoin cream and glycolic asid peeling one month after the iron and others replace therapy. We have recommended our patients fresh fruit juice everyday.(mix= orange, pomegrant or grape and apple). Our study was ongoing. 7 patients completed 6 months therapy and we follow them last two months. Melasma lesions were cleared. No any relapse were seen until today.

Recently similiar to our study there are some studies call our attention to iron, mineral and vitamin deficiency in patients with melasma. Therefore we should consider not only topical treatment but also oral treatment and prevention. Because all human body connect and work together. In recent studies mention about vitamin, iron and mineral deficiency. And today this could be main response why we have not succeed in patients with melasma. (Both recurrens and treatment). However further studies with a larger sample size are required.

Keywords: Melasma, Vitamin, Ferritin, Iron



3rd INDERCOS

National Dermatology & Cosmetology Congress with International Participants

14-17 MARCH, 2018
HILTON ISTANBUL BOSPHORUS HOTEL
ISTANBUL, TURKEY

OP-44

[URTICARIA, ANGIOEDEMA]

THE CLINICAL STUDY OF THE RELATION BETWEEN CHRONIC IDIOPATHIC URTICARIA (CIU) AND HP INFECTION

Marwa Mohamed

*Department of dermatology & Venereology of Union hospital, Hubei province, PR of China
-Huazhong University of Science and Technology.*

BACKGROUND: Chronic Urticaria has prominently negative effect on the daily activities & quality of life. Probably because the reasons in the majority of cases still unknown. Previous studies have showed significant relationship between CIU & various infections which can exacerbate the condition however the role of Infectious agents is considerably more controversial. H.pylori infection has been recently reported to play a role in the pathogenesis of CU

OBJECTIVE OF THIS STUDY: The aim of conduct our study is for further investigate the link between h.pylori infection & patients with CIU. Identify the characteristic of age & sex in CIU patient associated with H.pylori infection & if there is a link between the GI symptoms and prevalence of the infection in CIU patients. To find out the effect of eradication of h pylori therapy would have on the CIU symptoms.

METHOD: 331 patients (137 M & 195 F, mean age 38.06), ♀ to ♂ ratio (13:19) who diagnosed with CIU presented to outpatient clinic of dermatology department at Union hospital between January, 2013 and January, 2016 were included in this prospective, randomized study. 100 other participants randomly selected from Center of health examination of Union hospital as control group. All patients were assessed & tested for h pylori infection by using ¹³C, ¹⁴C uUBT & current infection marker for h pylori diagnosis. Also associated symptoms such as bad breath & GI complaints (epigastric, abdominal bloating, constipation & diarrhea) were documented and analyzed by using chi-square test & SPSS software.

RESULT: H. pylori was positive in 51.5% in CIU group, while it was 56% in control group. The prevalence of h.pylori infection was not significantly ↑ among CIU patients compared with the healthy group ($P > 0.05$). Incidence of H pylori infection was varying among different age groups. Patients between (20-30) had a ↑ rate of h pylori infection comparing with other age groups. In relation to GI symptoms & CIU, 125 patients complained from epigastric pain and only 48 were positive for h pylori (38.4%). 206 patients have no epigastric pain and 126 were positive for h pylori ($P < 0.05$). Among h pylori positive group the responsiveness to eradication therapy was evident in 40 patients in whom H.pylori was eradicated, while 27 patients showed no response. On other hand between patients who received antihistamine treatment only two patients showed improvement while the other 98 patients had fail ($p < 0.05$). However, what make this correlation worthy for further investigations are the chronic and asymptomatic nature of H pylori infection and its ↑ endemic nature. Conclusion H pylori may play a role as a risk factor or exacerbate symptoms of chronic urticaria. Patients in the 3rd decade of life with CIU more susceptible to be infected with h pylori. GI symptoms & halitosis could be an indicators for h pylori

3rd INDERCOS

National Dermatology & Cosmetology Congress with International Participants

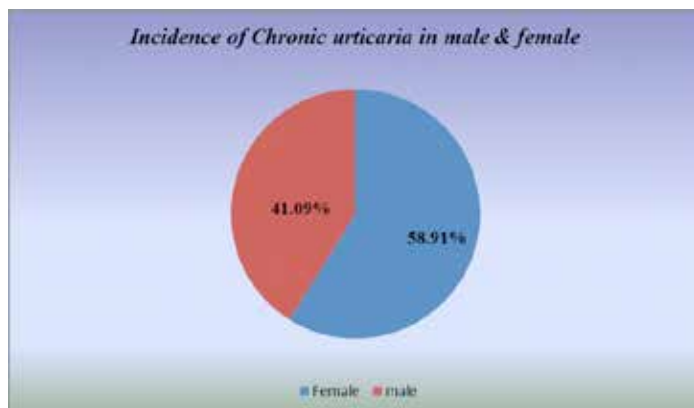
14-17 MARCH, 2018
HILTON ISTANBUL BOSPHORUS HOTEL
ISTANBUL, TURKEY



infection, all patients with CU for unknown etiology should be screened. H. pylori eradication therapy was successful on remission of symptoms

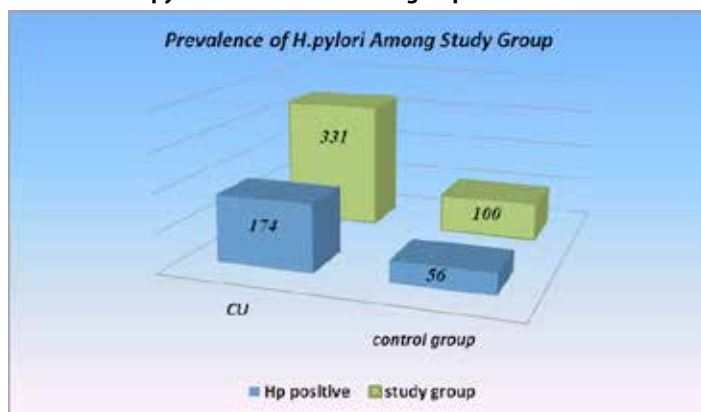
Keywords: Chronic idiopathic urticaria (CIU), helicobacter pylori (h pylori), Gastrointestinal symptoms (GI)

Distribution of CIU in male & female.



Distribution of CIU in male & female.

Incidence of H.pylori infection in studied group



Incidence of H.pylori infection in studied group



14-17 MARCH, 2018
HILTON ISTANBUL BOSPHORUS HOTEL
ISTANBUL, TURKEY

The graph illustrates the relationship between the number of people and the number of people per person. The x-axis represents the number of people (1 to 10), and the y-axis represents the number of people per person (0 to 10). Two lines are plotted: a blue line with diamond markers and a red line with square markers. Both lines show a peak at 5 people. The blue line starts at (1, 1), peaks at (5, 5), and ends at (10, 1). The red line starts at (1, 0.5), peaks at (5, 2), and ends at (10, 0.5).

Number of People	Blue Line (People per Person)	Red Line (People per Person)
1	1	0.5
2	2	1
3	3	1.5
4	4	2
5	5	2.5
6	4	2
7	3	1.5
8	2	1
9	1	0.5
10	1	0.5

Comparison of h.pylori prevalence in chronic urticaria group and healthy group

Chronic urticaria group				

3rd INDERCOS

National Dermatology & Cosmetology Congress with International Participants

14-17 MARCH, 2018
HILTON ISTANBUL BOSPHORUS HOTEL
ISTANBUL, TURKEY



OP-45

[ALLERGOLOGY AND IMMUNOLOGY]

IMMUNE THERAPY OF WARTS

Eman Moustafa Sanad, Fatma Mohamed El Esawy

Department of dermatology and andrology, Benha university, Egypt

The common incidence of warts in addition to their clinical significance highlights the need for immune protection against HPV infection. This is particularly true in view of the absence of specific antiviral therapy against HPV, the variable efficacy of the available therapeutic modalities, the high incidence of adverse effects, particularly with the use of destructive approaches, and the relatively high recurrence rates associated with most of the current remedies. There is increasing evidence that cell-mediated immunity (CMI) plays an important role in the resolution of human warts.

Keywords: warts, immune therapy, PPD

OP-46

[ACNE AND RELATED DISORDERS, HIDRADENITIS SUPPURATIVA]

CHRONIC SYSTEMIC DISEASES AND ROSACEA: RESULTS OF A CASE-CONTROL STUDY AT KING FAHD HOSPITAL OF THE UNIVERSITY IN ALKHOBAR, SAUDI ARABIA

Iqbal Bukhari¹, Nora Alomair¹, Yazeed Alhussan¹, Muhannad Alzahrani³, Nawaf Alsallouth⁵, Afnan Elahi⁴, Manal Hasan², Mazen Alyahia¹

¹Dermatology Department, Imam Abdulrahman Bin Faisal University (IAU) and King Fahd Hospital of the University, Alkhobar, KSA

²Internal Medicine Department, Imam Abdulrahman Bin Faisal University (IAU) and King Fahd Hospital of the University, Alkhobar, KSA

³Plastic Surgery Department, Imam Abdulrahman Bin Faisal University (IAU) and King Fahd Hospital of the University, Alkhobar, KSA

⁴College of medicine, Imam Abdulrahman Bin Faisal University (IAU) and King Fahd Hospital of the University, Alkhobar, KSA ⁵King Fahd Medical city, Riyadh, KSA

BACKGROUND: Rosacea is a common chronic inflammatory disease affecting the facial skin whose etiology and pathophysiology are still under investigation. Recent studies have shown a significant number of rosacea comorbidities including cardiovascular, gastrointestinal, neurological, autoimmune and metabolic diseases.

OBJECTIVE: to evaluate the association between rosacea and systemic comorbidities.

METHODS: This is a case control study conducted at the dermatology clinics at King Fahd Hospital of the University in Alkhobar, Saudi Arabia during during the year 2016. After acquiring the Institutional Review Board approval (IRB-2016-01-036) the study was initiated. Participants were clinically evaluated and related blood investigations were undertaken. The raw data was processed and entered for data analysis using SPSS program version 16. Relative risk estimates were calculated using logistic regression as odds ratios with 95% confidence intervals.



3rd INDERCOS

National Dermatology & Cosmetology Congress with International Participants

14-17 MARCH, 2018
HILTON ISTANBUL BOSPHORUS HOTEL
ISTANBUL, TURKEY

RESULTS: Among 59 participants (38 patients/21 control subjects), we observed a significant association between rosacea and hypertension, photosensitivity, food allergies, other dermatologic diseases and family history.

CONCLUSION: rosacea is shown to have high predictive value for the development of serious hidden systemic disorders. Its presence might provide a valuable early warning for physicians to provide comprehensive screening management for those patients.

Keywords: rosacea, hypertension, photosensitivity

OP-47

[ADVERSE DRUG REACTIONS, TEN]

AN EPIDEMIOLOGICAL AND CLINICAL ANALYSIS OF CUTANEOUS ADVERSE DRUG REACTIONS SEEN IN A TERTIARY CARE OUTPATIENTS CLINIC IN CAIRO, EGYPT

Eman A. El Nabrawy¹, Maha Fathy Elmasry¹, Mona Ibrahim El Lawindi², Yasmine Ahmed Tarek¹

¹Dermatology Department, Faculty of Medicine, Cairo University, Egypt

²Public Health and Community Medicine Department, Faculty of Medicine, Cairo University, Egypt

INTRODUCTION: A cutaneous adverse drug reaction (CADR) is any undesirable change in the structure or function of the skin, its appendages or mucous membranes caused by a drug. Frequency of CADRs is variable with only few studies discussing it. Our objective was to identify clinical and pathological spectrum of CADRs and document the epidemiological data of different types of drug eruptions among patients attending our tertiary care centre.

Material/METHODS: An observational hospital based analytical study was planned for a period of six months (January - June 2015). All patients attending the outpatient Dermatology Clinic were examined to detect patients with CADRs, who were subjected to a detailed questionnaire with a detailed drug history. A skin biopsy was taken to confirm the diagnosis and to detect the type of CADRs.

RESULTS: The primary incidence of CADRs reported in our study is 0.28% (78 patients) from a total number of 27,093 patients. The most common CADRs are SJS/TEN in 12 patients (15.3%) and lichenoid drug eruptions in 12 patients (15.3%) followed by exanthematous drug eruptions in 11 patients (14.1%) and vasculitic drug eruptions in 9 patients (11.5%). The most common drug incriminated is ibuprofen in 6 patients (7.6%) followed by penicillin in 4 patients (5.1%) and aspirin in 3 patients (3.8%).

CONCLUSIONS: Incidence of CADRs in our study is nearly similar to incidence reported in different countries; however incidence of life-threatening reactions like SJS/TEN was higher compared to studies conducted abroad.

Keywords: Cutaneous adverse drug reactions, epidemiology, incidence, outpatients

3rd INDERCOS

National Dermatology & Cosmetology Congress with International Participants

14-17 MARCH, 2018
HILTON ISTANBUL BOSPHORUS HOTEL
ISTANBUL, TURKEY



OP-48

[CONTACT AND OCCUPATIONAL DERMATITIS] ERYTHEMA AB IGNE WITH ATYPICAL LOCATION

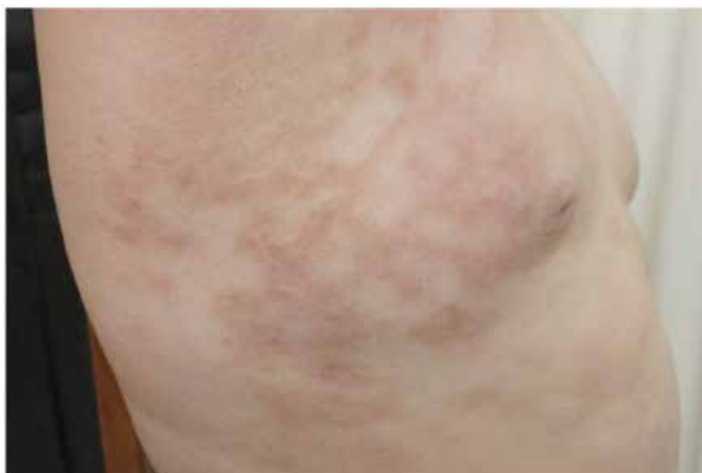Göknur Özeydin Yavuz, Ibrahim Halil Yavuz

Department of Dermatology, Yuzuncu Yil University Faculty of Medicine, Van, Turkey.

Erythema ab igne is caused by long-term and repeated exposure to low levels of infrared radiation that is usually in the form of heat within the range of 43°C to 47°C, which is below the threshold needed to induce thermal burns. The pathophysiology is unknown, but this level of infrared radiation induces changes in dermal elastic fibers that are similar to those observed in actinically-damaged skin. Erythema ab igne has a characteristic appearance and is a clinical diagnosis. It initially presents as a transient, reticulated, macular erythema that is blanchable. Over time and with repeated exposures, the lesions become hyperpigmented and fixed, with overlying atrophy and occasional telangiectases or hyperkeratosis in later stages. The eruption is typically asymptomatic although patients occasionally describe a mild burning sensation. The distribution and contour of lesions is related to the location of the heat source and arrangement of intervening layers of clothing. we want to present, erythema ab igne with atypical location

Keywords: Erythema ab igne, child, atypical

Case





3rd INDERCOS

National Dermatology & Cosmetology Congress with International Participants

14-17 MARCH, 2018
HILTON ISTANBUL BOSPHORUS HOTEL
ISTANBUL, TURKEY

OP-49

[QUALITY OF LIFE]

DOES SYSTEMIC ISOTRETINOIN TREATMENT EFFECTS FEMALE SEXUAL FUNCTIONS?

Emre Sinan Güngör¹, Şule Güngör²

¹Department of Obstetrics and Gynaecology, Suleymaniye Training and Research Hospital, Istanbul, Turkey.

²Department of Dermatology, Okmeydanı Training and Research Hospital, Istanbul, Turkey

BACKGROUND: Oral isotretinoin treatment has a broad adverse effect potential on the mucosal systems. Genital mucosal changes can effect female sexual function.

OBJECTIVE: The aim of the present study was to assess the effect of isotretinoin on female sexual function.

MATERIALS-METHODS: 20 sexually-active women with nodulocystic acne who used oral isotretinoin were included in the study. The women were proved two negative pregnancy test results before treatment and recommended to use two contraception methods during and two months after the cessation of the therapy. The patients using any systemic drugs (except oral contraception pills) were excluded. Female sexual functional scores were obtained before and on the second month of the treatment from each participant by using female sexual function index (FSFI) questionnaires. Wilcoxon and Mann-whitney U tests were used to compare data.

RESULTS: The FSFI total scores ($p=0.004$), as well as the scores in the lubrication ($p=0.001$), orgasm ($p=0.011$), satisfaction ($p=0.010$) and pain ($p=0.002$) domains, were significantly lower in posttreatment assessments. There were not any significant differences in the desire and arousal scores compared with pretreatment and posttreatment assessments.

CONCLUSION: Systemic isotretinoin treatment seems to effect sexual functions on women. Because desire and arousal subgroups of FSFI were not effected after treatment, it may be concluded that isotretinoin really effects mucous membranes. Further studies considering clinical examination of genital mucosa and histological evaluations with smears would explain the exact mechanism of isotretinoin impaired sexual functions.

Keywords: isotretinoin, female sexual function index, FSFI, mucosa

3rd INDERCOS

National Dermatology & Cosmetology Congress with International Participants

14-17 MARCH, 2018
HILTON ISTANBUL BOSPHORUS HOTEL
ISTANBUL, TURKEY



OP-50

[AUTOIMMUNE CONNECTIVE TISSUE DISORDERS]

A RARE PRESENTATION OF DISCOID LUPUS ERYTHEMATOSUS: COMEDOGENIC DLE

*Yavuz Tezcan, Şenay Ağırçöl, Zafer Türkoğlu, Ayşegül Ak
Haseki Training and Research Hospital, Istanbul, Turkey*

OBJECTIVE: Discoid lupus erythematosus (DLE) is a scarring, photosensitive disease. DLE has several clinical manifestations and acneiform presentation is very rare. In this case a rare form, comedogenic DLE, will be discussed.

MATERIAL / METHODS: A 68 year-old female patient apply to our clinic with 15 years old hair loss and pigmentation on face that started last year. Patient has no symptoms, only concern on cosmetic appearance. The whole face has covered with red-brown hyperpigmentation and multiple milimetric comedones. Patient has total alopecia and loss of eyebrows. Two biopsy specimens were taken for histopathological and direct immunofluorescence examination.

RESULTS: Histopathological findings showed compact hyperkeratosis, interface dermatitis, lichenoid and vacuolar infiltration with basal membrane zone thickening. Direct immunofluorescence showed nonspecific features. With these clinical and histopathological findings a comedogenic DLE diagnosis was performed. Hydroxychloroquine 400 mg/day and sun protective cream started as treatment.

CONCLUSIONS: Discoid lupus erythematosus, generally seen with characteristic clinical appearance, rarely atypical presentations of DLE such as comedones can be observed.

Keywords: Discoid lupus erythematosus, DLE, comedon, acneiform,

OP-51

[WOUNDS, CHRONIC WOUNDS, WOUND HEALING, ULCER]

WOUND HEALING & COSMETIC PROCEDURES; BACK TO BASICS

Eman Moustafa Sanad

Department of dermatology and andrology, Benha university, Egypt

The approach to most of the cosmetic procedures in dermatology especially chemical peeling and laser skin resurfacing necessitates a thorough knowledge of skin anatomy and normal wound healing. Wound healing is a complex and dynamic process of restoring cellular structures and tissue layers. Cytokines, which are central to inflammation and repair, have become targets for therapeutic intervention to modulate the wound healing process. Continuing progress in explaining the complex role of cytokines in wound healing provides opportunities to control or modulate the healing deficiencies that occur with aging. This movement nowadays is at the core of anti-aging medicine.

Keywords: wound healing, cytokines, antiaging



3rd Indercos National Dermatology & Cosmetology Congress with International Participants

14-17 MARCH, 2018
HILTON ISTANBUL BOSPHORUS HOTEL
ISTANBUL, TURKEY

OP-52

[MISCELLANEOUS]

NEVOID HYPERKERATOSIS OF THE NIPPLE AND AREOLA

Aslı Tatlıparmak¹, Merve Işık², Ladan Rastgar², Berna Aksoy³, Ahmet Kaur⁴

¹Bahçeşehir University, Faculty of Medicine, Department of Dermatology, Istanbul, Turkey; Fatih Medicalpark Hospital, Dermatology Clinic, Istanbul, Turkey

²Bahçeşehir University, Faculty of Medicine, Istanbul, Turkey

³Bahçeşehir University, Faculty of Medicine, Department of Dermatology, Istanbul, Turkey; VM Medicalpark Hospital, Dermatology Clinic, Kocaeli, Turkey

⁴E-cytopathology Laboratory, Istanbul, Turkey

OBJECTIVE: Nevoid hyperkeratosis of the nipple and areola (NHNA) is excessive keratinization of nipple and areolar region.

AIM: In this report our aim is to present a case with NHNA and treatment with cryotherapy. **CASE:** A 30 years old woman admitted to our outpatient clinic with crusting on nipple present for two years. She was evaluated several times by general surgery specialists. Her breast ultrasonography and prolactin levels were normal. A biopsy taken from the lesional area was reported as chronic inflammatory process in 2016. She used topical antibiotic pomades with no improvement. A new biopsy was taken and reported as Nevoid Hyperkeratosis. For treatment she received three sessions of cryotherapy (every other 3 weeks) and topical cream containing triticum vulgare extract.

CONCLUSION: NHNA is rare disease and represents benign hyperkeratinization of the nipple and areola. Cryotherapy is a good alternative for the treatment of this benign condition.

Keywords: cryotherapy, hyperkeratosis, nevoid, nipple

OP-53

[DERMATOLOGICAL PRACTICE MANAGEMENT]

IN THIS STUDY, PATIENTS AGED 15-35 YEARS WITH VITILIGO AND 30 SEX- AND AGE-MATCHED APPARENTLY HEALTHY CONTROLS WERE INCLUDED. THE VITILIGO SIZE REPRESENTATIVE AREA WAS ESTIMATED. THE RESULTS SHOWED THAT BY APPLYING SINAX OINTMENT ON VITILIGO FOR 60 D

Sina Sadreddini¹, Masoud Ehtesham²

¹Young Researchers and Elites Club, Science and Research Branch, Islamic Azad University, Tehran, Iran

²Young Researchers and Elites Club, Shahid Sadoughi Hospital, Yazd, Iran.

In this study, patients aged 15-35 years with vitiligo and 30 sex- and age-matched apparently healthy controls were included. The vitiligo size representative area was estimated. The results showed that by applying sinax ointment on Vitiligo for 60 days and exposure to sunlight for 40 minutes a day, a main part of it will be faded by activating the skin pigments and great results are visible on face, arm, thigh, leg, pelvis, chest and back.

Keywords: Vitiligo, Sinax ointment, Vitamin D, Pigmentation.

3rd INDERCOS

National Dermatology & Cosmetology Congress with International Participants

14-17 MARCH, 2018
HILTON ISTANBUL BOSPHORUS HOTEL
ISTANBUL, TURKEY



OP-54

[ANGIOLOGY, HAEMANGIOMAS, VASCULAR MALFORMATIONS, VASCULITIS] UNILATERAL NEVOID TELANGIECTASIA

Berna Aksoy¹, Ladan Rastgar², Merve Işık², Aslı Tatlıpırmak³, Nimet Karadayı⁴

¹Bahçeşehir University, Faculty of Medicine, Department of Dermatology, Istanbul, Turkey; VM Medicalpark Hospital, Dermatology Clinic, Kocaeli, Turkey

²Bahçeşehir University, Faculty of Medicine, Istanbul, Turkey

³Bahçeşehir University, Faculty of Medicine, Department of Dermatology, Istanbul, Turkey; Fatih Medicalpark Hospital, Dermatology Clinic, Istanbul, Turkey

⁴Kartal Education and Research Hospital, Pathology Clinic, Istanbul, Turkey

OBJECTIVE: Unilateral nevoid telangiectasia (UNT), is a rare vascular skin lesion which occur in unilateral dermatomal distribution in cervical, trigeminal and upper thoracic regions. UNT may be congenital or acquired.

AIM: In this report our aim is to present a case with UNT that is first developed during pregnancy.

CASE: A 32-year-old woman who is 24 weeks pregnant presented with a complaint of reddish blotch located on her left upper arm, shoulder and chest. She reported that the reddish blotch was present for 2 weeks. There is no itching and history of exposure to sunlight. She received progesterone 250mg intramuscular injection only once at 9th week of pregnancy. She was using oral multivitamins and iron. Her personal and family history was unremarkable. Dermatological examination and dermoscopy revealed widespread telangiectasia located in her left shoulder region. She was diagnosed as UNT developed during pregnancy.

CONCLUSION: UNT is an uncommon vascular skin lesion that has two forms: congenital and acquired. Whereas congenital forms are mostly seen in men, acquired forms are mostly seen in female. Even so etiopathogenesis is still not clear, UNT may relate to grade of estrogen in body. Even progesterone is important at the beginning of pregnancy, estrogen levels increase thereafter. At 22th week of pregnancy estrogen level is constantly high as our patient developed UNT lesions in her left upper arm, shoulder and chest at 22th week of gestation.

Keywords: acquired, nevoid, nevus, telangiectasia, vascular



3rd INDERCOS

National Dermatology & Cosmetology Congress with International Participants

14-17 MARCH, 2018
HILTON ISTANBUL BOSPHORUS HOTEL
ISTANBUL, TURKEY

OP-55

[ACNE AND RELATED DISORDERS, HIDRADENITIS SUPPURATIVA] OPTIMIZING THE RESULTS OF MANAGEMENT OF POST ACNE SCARS

Eman Moustafa Sanad

Department of dermatology and andrology, Benha university, Egypt

Acne scars present a highly challenging and frustrating clinical problem. A variety of effective treatments for atrophic acne scars have been developed, including excisional procedures, punch elevation, dermabrasion, chemical peels of varying concentrations and application techniques, subcision, and laser procedures including non-ablative, ablative, and fractional. Fractional photothermolysis offers a convenient treatment modality for the management of post acne scars. Sufficient knowledge of efficacy, safety, and limitation of different lasers available is essential for physicians treating scars. In order to optimally treat a patient's scars, a tailored treatment plan must be created in which the patient's specific types of scars are treated with the procedures that are most likely to improve those types of scars.

Keywords: acne, scars, management

3rd INDERCOS

National Dermatology & Cosmetology Congress with International Participants

14-17 MARCH, 2018
HILTON ISTANBUL BOSPHORUS HOTEL
ISTANBUL, TURKEY



OP-56

[PSORIASIS]

SERUM LIPOPROTEIN(A) AND LIPID LEVELS IN PATIENTS WITH CHRONIC PLAQUE TYPE PSORIASIS.

Melek Aslan Kayıran¹, Emine Derviş²

¹Istanbul Medeniyet University, Göztepe Education and Research Hospital, Department of Dermatology, Istanbul, Turkey

²Yeni Yüzyıl University, Gaziosmanpaşa Hospital, Department of Dermatology, Istanbul, Turkey

INTRODUCTION: Psoriasis vulgaris (PV) is a chronic, recurrent and inflammatory skin disease. The disorders like myocardial infarction, pulmonary embolism and cerebrovascular ischemia are common in psoriasis patients. While this may be attributed to impaired lipid metabolism, some have blamed the oxidative stress in chronic disorders. Some studies emphasize the close monitoring of PV patients in terms of atherosclerosis. Lipoprotein(a) [Lp(a)] is composed of phospholipids, cholesterol and apolipoprotein B-100. Its levels are dependent on genetic factors and aren't affected by dietary lipid content and life style. There is a high risk of atherosclerotic vascular disorders when the levels are more than 15 mg/dl. The aim of our study is to compare serum lipid and Lp(a) levels between PV and healthy group and to investigate whether PV forms a tendency to atherosclerosis.

MATERIAL-METHODS: 44 patients with PV and 48 healthy people were included in the study. There was no difference in age, height, weight, sex, and body mass index between the groups. Fasting serum total cholesterol (TC), triglyceride, HDL cholesterol, LDL cholesterol, VLDL cholesterol and Lp(a) levels were analyzed.

RESULTS: The PV group consisted of 28 females and 16 males with a mean age of 43,2±19,09. The control group consisted of 25 males and 23 females with a mean age of 45,25 ± 15,45. 12 of the PV group (27,2%) were recently diagnosed and 21 (65%) of the previously diagnosed patients were prescribed topical medications before. None of the patients used systemic drugs for psoriasis. 24 patients of PV group (54,5%) had high Lp(a) levels, 20 (45,4%) had high TC, 20 (45,4%) had high LDL, 10 (22,7%) had high VLDL, 3 (6,8%) had high triglyceride and 4 (9%) had low HDL levels. TC was found high in 11 (22,9%), LDL in 13 (27,08%), Lp(a) in 8 (16,6%) and triglyceride in 6, VLDL in 6 (12,5%) people and HDL was found low in 10 (20,8%) people in control group. (Table 1) TC, triglyceride, HDL, LDL, VLDL cholesterol levels didn't differ statistically between the groups ($p > 0,05$). Lp(a) levels in the psoriasis group were statistically significantly higher than the control group ($p < 0,001$).

CONCLUSION: The atherosclerotic cardiovascular disorders are more common in psoriatic patients than normal population. One of the major risk factors for atherosclerosis is hyperlipidemia which contains hypercholesterolemia, hypertriglyceridemia and the changes in the lipoprotein levels; one of which is high Lp(a) levels. According to the results of our study, the Lp(a) levels that contribute to the development of atherosclerosis are statistically higher in the psoriasis group than in the control group, which supports the studies that atherosclerosis is more frequent in psoriasis patients. In this case, Lp(a) levels may be an appropriate diagnostic tool in the evaluation of atherosclerotic and vasooclusive pathologies in psoriatic patients who are prone to cardiovascular diseases. More accurate results can be obtained in a wider series of cases.

Keywords: Psoriasis vulgaris, Lipoprotein (a), atherosclerosis



3rd INDERCOS

National Dermatology & Cosmetology Congress with International Participants

14-17 MARCH, 2018
HILTON ISTANBUL BOSPHORUS HOTEL
ISTANBUL, TURKEY

OP-57

[ACNE AND RELATED DISORDERS, HIDRADENITIS SUPPURATIVA] ACNE THERAPY FROM VEGETABLE OIL DERIVATIVES

Emad Al Mulla

Department of Pathological Analysis, College of Health and Medical Techniques, Al-Furat Al-Awsat Technical University, 54003 Al-Kufa, Iraq

The greatest severe form of acne vulgaris is cystic acne. It is deep and inflamed breakouts develop on the face and/or other trunk. Although the greatest patients are adolescents, this problem can be found in any age. Cystic acne is fluid-filled lumps subcutaneous and usually painful. The common treatments for cystic acne are by antibiotics, surgical suction, steroid injection, laser or using hormonal acne treatment. Many studies have been conducted regarding cystic acne treatment. However, there is no effective action and most of these treatments take time. This result is maybe due to limitation of these agents to do desired effect by penetration the skin barrier deeply. In this study, some vegetable oil derivatives were suggested as substrates to increase skin penetrability by creating the conditions for membrane transfer of the substrate. Increased permeability of the cell wall allows the transport of the active agent guest. The aims of treatment are to prevent scarring, limit the disease duration and reduce the impact of the psychological stress that may affect over half of sufferers. The major components of this treatment are vegetable oil derivatives which were synthesized from abundant raw materials using a simple and environmentally friendly process. Patients aged 10-40 years, lived under similar environmental conditions and were treated through the same medical care structure were evaluated. Patients were instructed to use the product 5 times daily. The certification was achieved by physical examination and by digital photography under identical conditions. The location of cystic acne was in cheek, forearm and the trunk. The results showed that all patients have been completely healed without scarring as a treatment for angiolipoma. The period of treatment was within 3-7 days without leaving a greasy feel.

Keywords: Cystic acne, therapy, vegetable oil derivatives

3rd INDERCOS

National Dermatology & Cosmetology Congress with International Participants

14-17 MARCH, 2018
HILTON ISTANBUL BOSPHORUS HOTEL
ISTANBUL, TURKEY



OP-58

[DERMATOLOGICAL PRACTICE MANAGEMENT]

LICHEN PLANUS AND ITS MANAGEMENT: AN EVALUATION

Mohammad Abdul Hye

Department of Dermatology, Jalalabad Ragib-Rabeya Medical College, Sylhet, Bangladesh.

INTRODUCTION: Lichen planus (LP) is an inflammatory muco-cutaneous disease characterised by shiny, flat –topped papules and plaques. It affects around 1% of the population. The disease is usually self-limiting and benign in nature. However, some varieties of LP may cause considerable discomfort and recalcitrant in nature. So, treatment depends on appreciating the type, severity and nature of the disease. This review outlines the treatment options that are available to patient with LP.

MATERIALS-METHODS: Published literature involving the treatment or management of LP was examined and summarized.

RESULTS: There is a good numbers of options for treating different types of LP. Few types are difficult to treat and needs aggressive treatment to prevent complications like hair or nail loss. Aggravating factors including certain drugs, trauma etc. and should be avoided. There are also many associated conditions which may co-exist or exacerbate LP and so these conditions also should be accurately searched and managed accurately searched and managed. Still now, there is no general consensus for treatment of LP. Following topical or systemic medications are reported in literature for treatment of different type of LP: 1) Topical agents such as steroids, tacrolimus, retinoid, cyclosporine, alovera gel. 2) Systemic medications include Steroids, retinoid, cyclosporin, methotrexate, metronidazole. Griseofulvin, Apremilast, antimalarial, mycophenolate mofetil, Rituximab. 3) Others are PUVA, photodynamic therapy, excimer laser, CO2 laser.

CONCLUSION: Whatever the treatment options, the large scale, evidence based trials are only few in number, so more clinical trials are urgently needed. At present, it is quite difficult to standardisation of treatment. However, it is needed to assimilation and summarization of the recent findings to treat the critical cases in a more effective way.

Keywords: lichen planus, recalcitrant type, treatment



3rd INDERCOS

National Dermatology & Cosmetology Congress with International Participants

14-17 MARCH, 2018
HILTON ISTANBUL BOSPHORUS HOTEL
ISTANBUL, TURKEY

OP-59

[ACNE AND RELATED DISORDERS, HIDRADENITIS SUPPURATIVA]

THE IMPACT OF DISEASE SEVERITY AND QUALITY OF LIFE ON PATIENTS WITH ACNE VULGARIS

*Melek Aslan Kayıran, Filiz Cebeci, Ayşe Serap Karadağ, Vefa Aslı Erdemir, Mehmet Salih Gürel
Istanbul Medeniyet University Göztepe Education and Research Hospital, Department of Dermatology,
Istanbul, Turkey*

INTRODUCTION: Acne vulgaris is a common disorder in society. Many psychosocial effects are seen due to frequent face involvement and different body perceptions in affected adolescents. In this study, it was aimed to investigate the psychosocial effects of acne and the effect of acne severity on the quality of life of the patients.

METHODS: Newly diagnosed patients with acne vulgaris were asked to fill in the Cardiff Acne Disability Index. The severity of acne vulgaris was evaluated by the physician using the Global Acne Scoring System.

RESULTS: Of 202 patients with acne vulgaris, 133 were female and 69 were male. While mean Cardiff Acne Disability Index score was significantly lower in men (6.1 vs 7.1, $p=0.033$), the Global Acne Scoring System score was significantly higher in men (21.9 vs 16.9), which was also statistically significant ($p<0.000$). There was no significant correlation between Cardiff Acne Disability Index and Global Acne Scoring System scores in all patients ($p=0.218$).

CONCLUSION: Although acne severity is higher in male patients, it is observed that females are more affected psychosocially than males. This indicates that gender plays an important role among the factors affecting the quality of life. Considering psychosocial effects as well as acne severity will affect the success of the treatment.

Keywords: Acne vulgaris, Quality of Life, Disease severity

3rd INDERCOS

National Dermatology & Cosmetology Congress with International Participants

14-17 MARCH, 2018
HILTON ISTANBUL BOSPHORUS HOTEL
ISTANBUL, TURKEY



OP-60

[ACNE AND RELATED DISORDERS, HIDRADENITIS SUPPURATIVA]

EVALUATION OF (SERUM) BRAIN-DERIVED NEUROTROPHIC FACTOR LEVELS AND THE IMPACT OF SYSTEMIC ISOTRETINOIN TREATMENT ON BRAIN-DERIVED NEUROTROPHIC FACTOR LEVELS IN PATIENTS WITH ACNE VULGARIS

Mehmet Şimşek¹, Necmettin Akdeniz¹, Burak Tekin¹, Ayşe Serap Karadağ¹, Hayriye Erman², Hasan Turan Karatepe³, Mehmet Salih Gürel¹

¹Department of Dermatology, Istanbul Medeniyet University, Istanbul, Turkey

²Department of Biochemistry, Istanbul Medeniyet University, Istanbul, Turkey

³Department of Psychiatry, Istanbul Medeniyet University, Istanbul, Turkey

OBJECTIVE: Acne vulgaris (AV), albeit not a life-threatening disease, is a chronic inflammatory disease that negatively influences the quality of life, especially due to its psychological effects. Psychiatric side effects of systemic isotretinoin therapy are controversial. Brain derived neurotrophic factor (BDNF), which plays a very important role in the pathogenesis of depression, has been investigated in many skin diseases. However there has been no study in AV patients. In this study, we aimed to evaluate the serum BDNF levels and the effect of systemic isotretinoin treatment on BDNF levels in patients with AV.

METHODS: Thirty-five acne patients (diseased group) receiving systemic isotretinoin therapy, 35 acne patients (diseased control group) receiving oral doxycycline and / or topical erythromycin 3% + benzoyl peroxide 5% treatment and 35 healthy volunteers, aged 18-65 were included in the study. At the first visit, all three groups completed Beck Depression Inventory (BDI), Beck Anxiety Inventory (BAI), Symptom Checklist-90-Revised (SCL-90-R) and serum BDNF levels were measured. In addition, Dermatology Life Quality Index (DLQI), Acne Quality of Life Instrument (AQLI) and Cardiff Acne Disability Index (CADi) were completed by the patients with AV. All these parameters and laboratory tests were repeated at the end of a 3-month-therapy in patients with AV. In acne patients, disease severity was assessed by the physician with the FDA's recommended system and Global Acne Grading System (GAGS) before and after treatment.

RESULTS: Anxiety and depression levels were significantly higher in patients AV compared to the healthy control group. Serum BDNF levels were significantly higher in the diseased group compared to the diseased control and healthy control groups ($p < 0.05$). The changes in serum BDNF levels after treatment were not statistically significant in the diseased group and in the diseased control group ($p > 0.05$); however serum BDNF levels after treatment were found to be lower than pretreatment serum BDNF levels in both groups.

CONCLUSION: Serum BDNF levels were found to be higher in patients with acne compared to the normal population and correlated with acne severity weakly. It was determined that systemic isotretinoin treatment did not significantly affect serum BDNF levels.

Keywords: acne vulgaris, BDNF, depression, isotretinoin



3rd INDERCOS

National Dermatology & Cosmetology Congress with International Participants

14-17 MARCH, 2018
HILTON ISTANBUL BOSPHORUS HOTEL
ISTANBUL, TURKEY

OP-61

[DERMATOLOGY AND INTERNAL MEDICINE, INCLUDING SKIN MANIFESTATIONS OF SYSTEMIC DISEASES]

ACANTHOSIS NIGRICANS COMBINED WITH SKIN TAGS AS CLINICAL MARKER FOR EVALUATION OF OBESITY IN TURKISH POPULATION

Ayşe Serap Karadağ¹, Tugba Kevser Uzuncakmak¹, Emin Ozlu², Mumtaz Takır³, Wenchieh Chen⁴

¹Istanbul Medeniyet University Medical Faculty Department of Dermatology

²Düzce University Medical Faculty Department of Dermatology

³Istanbul Medeniyet University Medical Faculty Department of Internal Medicine

⁴Technische Universität München, Department of Dermatology, Munich, Germany

BACKGROUND/OBJECTIVE: Inconsistent data exist regarding the use of acanthosis nigricans (AN) or skin tags as clinical marker for obesity or diabetes. There is no biological marker for assessment of severity of AN. We designed a comprehensive quantitative system integrating both AN and skin tags to evaluate their correlation, and association with obesity or type 2 diabetes in Turkish population.

SUBJECTS/METHODS: In a hospital-based prospective study of obese people recruited between December 2014 and August 2015 in Istanbul Turkey, scoring for AN severity (SCANS) was used to evaluate AN based on six anatomic localizations, skin surface areas, severity grades, including the number of skin tags. A total severity score ranged at 0-46. Obesity was defined by body mass index (BMI) > 35. Diagnosis of type 2 diabetes was made following the recommendations of the American Diabetes Association.

RESULTS: A total of 336 patients at age ≥ 18 years with AN and 243 age- and sex-matched patients without AN were recruited. A higher BMI was associated with AN ($r = 0.299$, $P < 0.001$), but not with diabetes ($P = 0.43$). Among non-diabetics, AN scores were significantly correlated with waist circumference ($r = 0.131$, $P = 0.024$) and total cholesterol levels ($r = 0.155$, $P = 0.04$). Skin tags alone in the absence of AN were not associated with obesity ($P = 0.333$) or diabetes ($P = 0.164$). The total AN scores were positively correlated with the presence of skin tags ($r = 0.132$, $P < 0.001$), and the involvement of anterior neck ($r = 0.668$, $P < 0.001$) and axilla ($r = 0.793$, $P < 0.001$). Knuckles and groins were unaffected in our series.

CONCLUSIONS: Our comprehensive study indicated that combination of AN with skin tags can be used as clinical marker for evaluation of obesity, but not for type 2 diabetes.

Keywords: Acanthosis nigricans, body mass index, diabetes mellitus, insulin resistance

3rd INDERCOS

National Dermatology & Cosmetology Congress with International Participants

14-17 MARCH, 2018
HILTON ISTANBUL BOSPHORUS HOTEL
ISTANBUL, TURKEY



Figure 1b

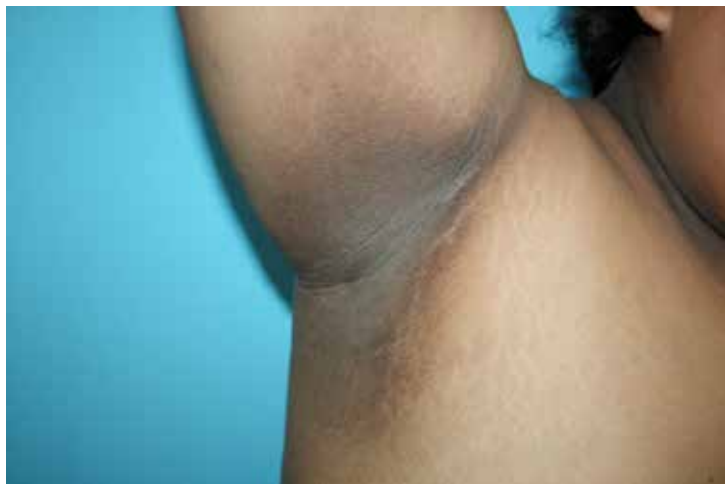
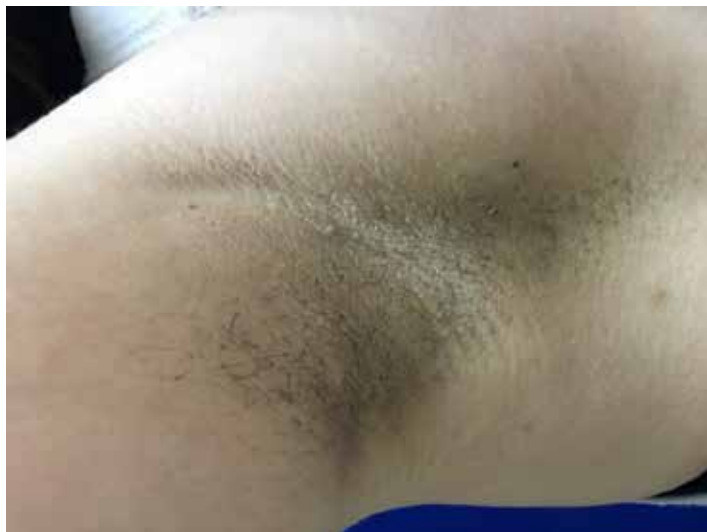
Figure 1a





3rd INDERCOS

National Dermatology & Cosmetology Congress with International Participants

14-17 MARCH, 2018
HILTON ISTANBUL BOSPHORUS HOTEL
ISTANBUL, TURKEY

Figure 1c

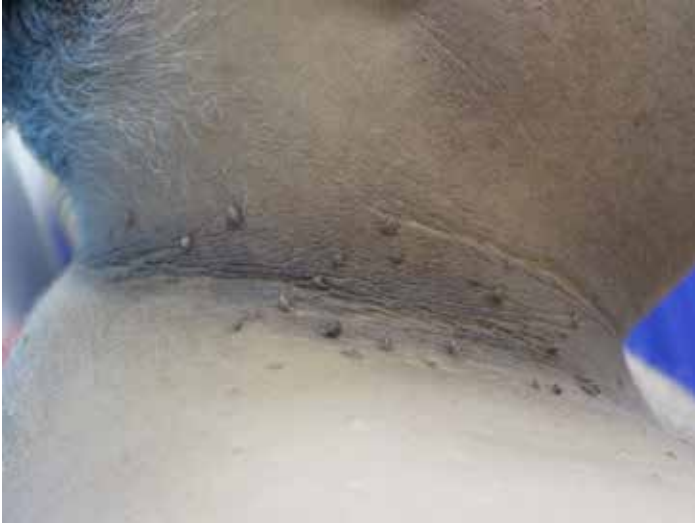
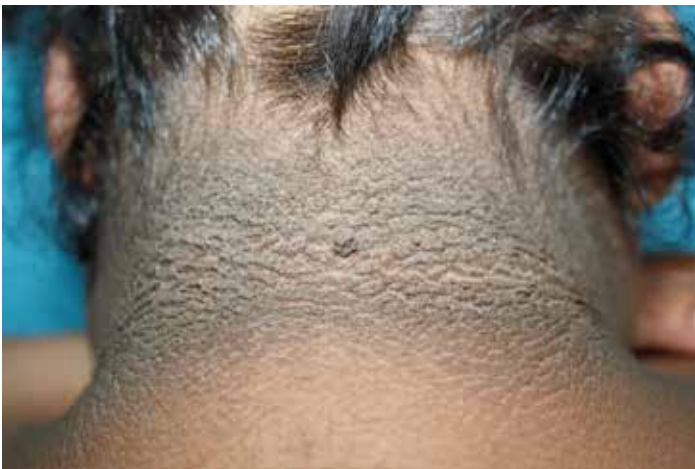

Figure 1d





Poster Presentations



PP-01

[MISCELLANEOUS]

AQUAGENIC SYRINGEAL ACROKERATODERMA: A CASE REPORT

Erdal Pala, Mehmet Melikoğlu, Handan Bilen, Şevki Özdemir

Department of Medical Faculty of Dermatological and Venereal Diseases, Atatürk University, Erzurum, Turkey

INTRODUCTION:

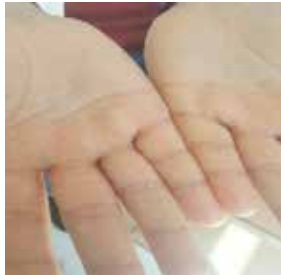Aquagenic syringeal acrokeratoderma (ASA) is a rare, acquired palmoplantar keratoderma of unknown etiology characterized by edematous white papules and plaques emerging after 2-4 min contact with water. We describe a 22-year-old patient diagnosed with ASA in the bilateral palmar region, and discuss the etiopathogenesis, diagnosis and treatment of the disease in the light of the existing literature.

CASE: A 22-year-old woman presented due to whitish, mildly pruritic swellings on both hands persisting for approximately the previous six months. These emerged a few minutes after contact with water and disappeared in 15-20 min. Dermatological examination revealed macerated whitish edematous papules, plaques and dilated spaces on the palmar surfaces of both hands (figure1). Histopathology. Hematoxylin-and-eosin stained sections show a thickened compact orthokeratotic cornified layer which includes dilated acrosyringia. The remaining epidermis and dermis are unremarkable (figure2).

CONCLUSION: ASA is a rare palmoplantar keratoderma characterized by transparent whitish papules, frequently bilateral and symmetrical, emerging after short-term contact with water. In conclusion, we think that this rare case, easily diagnosed with clinical findings and history, is worthy of being reported.

Keywords: Aquagenic syringeal acrokeratoderma, female, hand palmar surfaces

Figure 1



Macerated whitish edematous papules, plaques and dilated spaces on the palmar surfaces of both hands

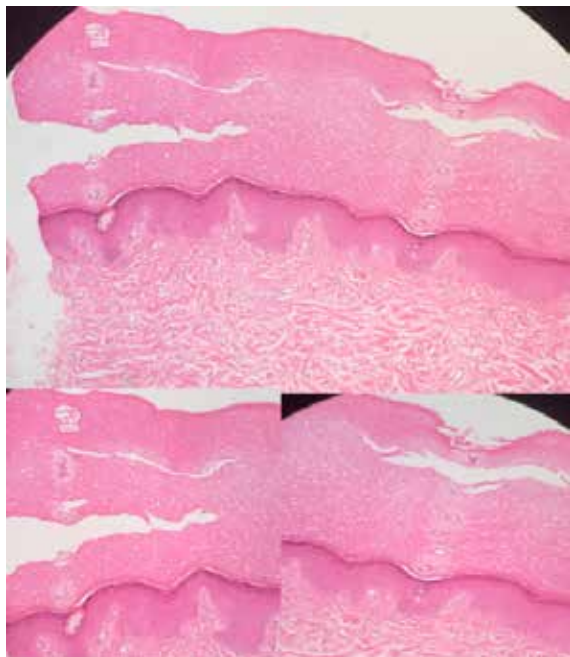
3rd INDERCOS

National Dermatology & Cosmetology Congress with International Participants

14-17 MARCH, 2018
HILTON ISTANBUL BOSPHORUS HOTEL
ISTANBUL, TURKEY



Figure 2



Hematoxylin-and-eosin stained sections show a thickened compact orthokeratotic cornified layer which includes dilated acrosyringia. The remaining epidermis and dermis are unremarkable



3rd INDERCOS

National Dermatology & Cosmetology Congress with International Participants

14-17 MARCH, 2018
HILTON ISTANBUL BOSPHORUS HOTEL
ISTANBUL, TURKEY

PP-002

[GENETICS]

FAMILIAL TUBEROUS SCLEROSIS: A CASE REPORT

Meghna Sharma¹, Rashmi Sharma², Rakesh Gautam³

¹Neoskin Laser Clinic, Punjab, India

²KD Hospital

³Neelam Hospital, Punjab, India

Tuberous Sclerosis is a rare neurocutaneous syndrome with an autosomal dominant inheritance. It is characterized by the development of benign tumours in multiple organ systems. With an incidence of approximately 1 in 5000 to 10000 live births; it is an important neurocutaneous syndrome to diagnose because of its phenotypic variability and the often life threatening manifestations it can present with. At present, it cannot be accurately defined as to who will remain mildly affected and who will be more severely affected by Tuberous Sclerosis. Often, members of the same family will present with different manifestations. Familial Tuberous Sclerosis occurs more often than it is documented; and many family members also show signs of being carriers of the disease when carefully examined.

We report an interesting scenario where the two siblings and father were found to have classical findings of Tuberous sclerosis.

The first case was a 9 year old girl who, on clinical examination, had findings of Adenoma sebaceum over the forehead nose and chin, confetti macules on the face arm and trunk, shagreen patch on the upper back, hypomelanotic macule on the buttock and back, enamel hypoplasia and dental pitting. Cortical tubers and subependymal nodules in the brain on MRI. USG and ophthalmological examination were WNL. She had growth delay and also had poor school performance.

The second case was a 13 year old boy presenting with papular lesions on the face diffuse as well as grouped in a butterfly pattern, confetti macules on the face and trunk, shagreen patch over the lower back, ash leaf macule on the upper arm extensor and shin of right leg and dental pits. On MRI cortical tubers and multiple subependymal nodules were seen and right kidney had a tiny angiomyolipoma on ultrasonography. He also had a low IQ.

The father had adenoma sebaceum in a butterfly pattern on the face.

The mother also had low IQ with no skin or systemic findings.

Keywords: tuberous sclerosis, adenoma sebaceum, familial

3rd INDERCOS

National Dermatology & Cosmetology Congress with International Participants

14-17 MARCH, 2018
HILTON ISTANBUL BOSPHORUS HOTEL
ISTANBUL, TURKEY



PP-003

[PAEDIATRIC DERMATOLOGY]

PERIANAL MOLLUSCUM CONTAGIOSUM IN A GIRL CHILD

Meghna Sharma

Neoskin Laser Clinic, India

24-month-old girl presented with a perianal papules and erosions of two months' duration. Clinical findings confirmed the diagnosis of perianal molluscum contagiosum. We applied imiquimod 5% cream three times per week for a period of 16 weeks, which resulted in complete clearance of all the lesions.. No recurrences were reported during 6 months of follow-up. This case show the effective use of topical imiquimod in the treatment of perianal MC in children.

It is safe, effective, satisfactory, less traumatic and painful compared to other options for treatment of perianal MC in children.

Infection with MCV is worldwide. Three groups are primarily affected: young children, sexually active adults and immunosuppressed persons, especially those with HIV infection. Treatment is usually done by expression, cryotherapy, curettage or TCA application. These modalities, however, can be uncomfortable for a two year old in the perianal region. We used imiquimod to treat the lesions with fair response.

Keywords: Molluscum contagiosum, perianal, imiquimod

PP-004

[ANGIOLOGY, HAEMANGIOMAS, VASCULAR MALFORMATIONS, VASCULITIS]

RARE VASCULAR TUMOR: GLOMANGIOMA

Göknur Özeydin Yavuz¹, Serap Güneş Bilgili¹, İbrahim Halil Yavuz¹, Rojda Aktar¹, Mustafa Aksoy²

¹Department of Dermatology, Yuzuncu Yil University Faculty of Medicine, Van, Turkey.

²Department of Dermatology, Harran University Faculty of Medicine, Şanlıurfa, Turkey.

Glomus tumors are structure originating from glomus bodies located in the extremities. The cutaneous glomangiomas are examined under the title of glomus tumors. It is usually asymptomatic and more frequent in extremities. The association with internal tumors is rare and multiple cases are less common. Histopathological evaluation should be performed for definite diagnosis. 32 year old male patient with asymptomatic blue nodules lesions on both upper and lower extremities were diagnosed as having glomangiomas in the presence of histopathological findings. This multiple glomangioma patient, also being hemangiomas in the liver, is presented because of its rare occurrence.

Keywords: glomangioma, hemangioma, vascular tumor



3rd INDERCOS

National Dermatology & Cosmetology Congress with International Participants

14-17 MARCH, 2018
HILTON ISTANBUL BOSPHORUS HOTEL
ISTANBUL, TURKEY

PP-005

[ALLERGOLOGY AND IMMUNOLOGY]

URTICARIA PIGMENTOSA IN MONOZYGOTIC TWINS

Ibrahim Halil Yavuz, Goknur Ozaydin Yavuz, Serap Gunes Bilgili

Department of Dermatology, Yuzuncu Yil University Faculty of Medicine, Van, Turkey.

Mastocytosis is a heterogeneous disorder characterized by clonal proliferation and accumulation of mast cells in one of more organs which may lead to different clinical pictures. Pathological increase and activation of mast cells in various tissues can cause different clinical pictures. Mast cell mediator-related symptoms such as pruritus, urticaria and flushing may occur in patients. Cutaneous mastocytosis limited to the skin is the most typical clinical picture observed in children and systemic mastocytosis is very rare in the pediatric age group. In children, the most frequent clinical presentation form is urticaria pigmentosa. Urticaria pigmentosa is a generally benign disease. It often occurs in the first 2 years of life and in most patients remission is observed in puberty. The diagnosis is based on clinical and histopathological findings. Herein, since it is an uncommon disease we report monozygotic twins with urticaria pigmentosa.

Keywords: Mastocytosis, urticaria pigmentosa, monozygotic twins

PP-006

[INHERITED SKIN DISEASES]

EPIDERMOLYTIC KERATOLYSIS WITH CLINICAL FEATURES RESEMBLING ICHTHYOSIS HYSTRIX LAMBERT TYPE

Özgür Gündüz¹, Gülşah Koçak¹, Atasoy Pınar²

¹Department of Dermatology, Kırıkkale University, Kırıkkale, Turkey

²Department of Pathology, Kırıkkale University, Kırıkkale, Turkey

INTRODUCTION: "Ichthyosis hystrix" (IH) is not a clear descriptive term and generally used to describe a group of congenital skin diseases that manifest massive spiky, verrucous hyperkeratosis. These clinical features are usually preceded by the epidermolytic hyperkeratosis or other disturbances of cornification. In addition to generalized lesions, a more limited, linear nevoid lesions have also been reported as IH (1,2). We describe a 5-year-old girl with the clinical features suggestive of IH Lambert type with the emphasis on histological findings.

CASE: A 5-year-old female child presented with progressive, dark brown colored, spiky, hyperkeratotic, verrucous papules and plaques all over her body with the exception of her face and palmoplantar regions. Her past medical history revealed generalized bullae over her body at a premature birth (34 weeks) and atrial septal defect. Family history revealed a consanguinity due to a cousin marriage. She

3rd INDERCOS

National Dermatology & Cosmetology Congress with International Participants

14-17 MARCH, 2018
HILTON ISTANBUL BOSPHORUS HOTEL
ISTANBUL, TURKEY



was diagnosed with "ichthyosis" and treated with topical emollients and peeling agents. She had also history of treatment with acitretin, but due to lack of her previous medical reports, total treatment period, cumulative acitretin dosage were unknown. The skin biopsy revealed prominent hyperkeratosis, ortokeratosis in stratum corneum, subcorneal cleft formation and acanthosis. Hypergranulation was also observed in the keratinocytes in stratum granulosum and basal keratinocytes with perinuclear vacuolisation (Fig 2). In addition to topical emollients, humectants, acitretin 10 mg/kg was started.

DISCUSSION: Ichthyoses are a heterogeneous group of keratinization disorders that present with varying degrees of skin scaling. Abnormalities of other skin appendages, internal organs or skeletal deformities may be observed in several forms. Most of the ichthyoses are inherited but acquired forms can be seen with other systemic diseases (3). The term "ichthyosis hystrix" (IH) is used to describe ichthyoses, which manifest themselves through massive hyperkeratotic, spiky, verrucous plaques. IH has been divided into five groups. Several mutations in keratin genes (i.e. KRT1, KRT10) have been reported. This case has been reported on account of its rarity.

REFERENCES: 1. Fleckman P, DiGiovanna JJ. The Ichthyoses. In: Wolff K, Goldsmith LA, Katz SI, Gilcrest BA, Paller AS, Leffell DJ, eds. Fitzpatrick's Dermatology In General Medicine. 8th ed. New York: McGraw-Hill; 2012. pp 507-38.

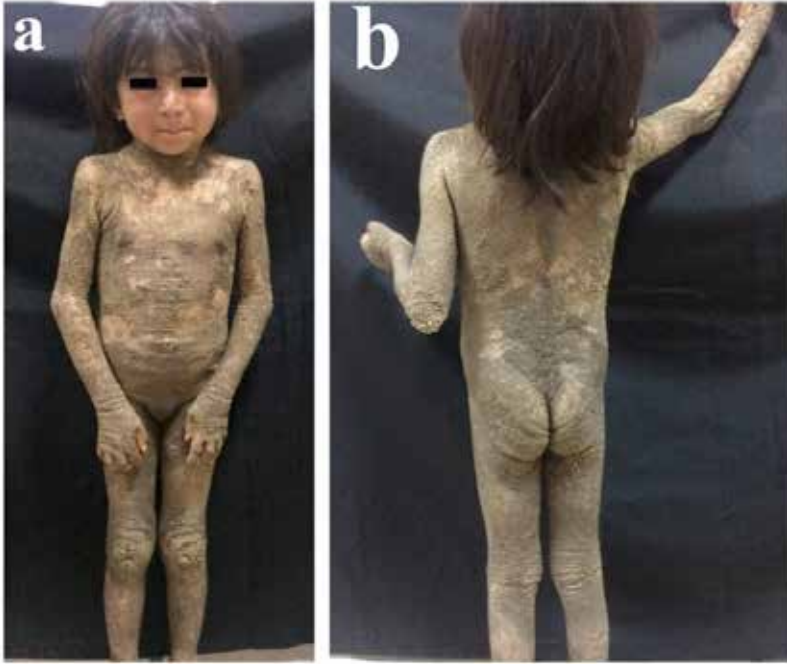2. Nayak S, Achariya B, Mohanty P. Ichthyosis hystrix. Indian Dermatol Online J. 2013;4:47-9.

3. Choate, K. (2016). Overview and classification of the inherited ichthyoses. In R. Corona (Ed.), UpToDate. Retrieved February 1, 2018, from <https://www.uptodate.com/contents/overview-and-classification-of-the-inherited-ichthyoses>

4. Wang WH, Li LF, Zhang Q, Yang SM, Jiang W, Wang YY, Lei PC, Chen XR. Ultrastructural features of ichthyosis hystrix strongly resembling Lambert type. Br J Dermatol. 2007 May;156(5):1027-31.

Keywords: ichthyosis hystrix, acitretin, epidermolytic hyperkeratosis

Figure 1



(a) Lack of facial lesions and prominent massive hyperkeratotic plaques all over the body (b) Generalized verrucous plaques on patient's back, particularly pronounced on the sacral area

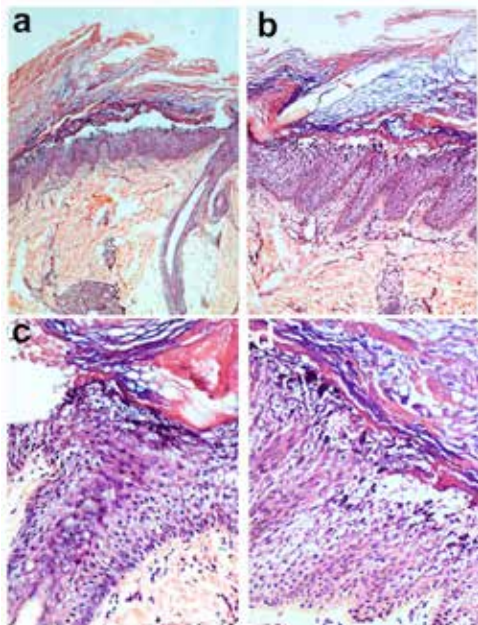
3rd INDERCOS

National Dermatology & Cosmetology Congress with International Participants

14-17 MARCH, 2018
HILTON ISTANBUL BOSPHORUS HOTEL
ISTANBUL, TURKEY



Figure 2



(a) Prominent hyper- and ortokeratosis in the stratum corneum, subcorneal epidermal cleft and acanthosis (H&E, x100) (b) Epidermal clefting (H&E, x200) (c) Hypergranulation in stratum granulosum and perinuclear vacuolisation in the basal keratinocytes (H&E, x400) (d) Hypergranulation in stratum granulosum with dense-core granules and another look at the perinuclear vacuolisation of basal keratinocytes (H&E, x400)



3rd INDERCOS

National Dermatology & Cosmetology Congress with International Participants

14-17 MARCH, 2018
HILTON ISTANBUL BOSPHORUS HOTEL
ISTANBUL, TURKEY

PP-007

[ADVERSE DRUG REACTIONS, TEN]

A RARE SIDE EFFECT OF COMBINATION OF VEMURAFENIB AND COBIMETINIB: ERITEMA NODOSUM LIKE LESIONS IN A PATIENT WITH METASTATIC MELANOMA

Acer Ersoy¹, Kaya Erdogan Hilal¹, Saracoglu Zeynep Nurhan¹, Arık Deniz²

¹Department of Dermatology, Ekisehir Osmangazi University, Eskisehir, Turkey

²Department of Pathology, Ekisehir Osmangazi University, Eskisehir, Turkey

INTRODUCTION: The combination of BRAF inhibitor (vemurafenib, dabrafenib) and MEK inhibitor (cobimetinib, trametinib) is often used in patients with BRAF V600-mutated metastatic melanoma. BRAF inhibitors cause various cutaneous adverse effects including photosensitivity, hand-foot skin reaction, rash, dry skin, alopecia, skin papillomas and squamous cell carcinomas; but eritema nodosum like lesion is a rare cutaneous adverse effect. The combination with MEK inhibitors reduces cutaneous adverse effects induced by BRAF inhibitors alone.

CASE: A 48-years-old woman with metastatic melanoma was presented to our clinic with painful rash on her lower limbs and arthralgia. This complaints had started before one month ago. She had been diagnosed with BRAF V600E- mutated metastatic melanoma and has been treated with vemurafenib 1440 mg/day and cobimetinib 60 mg/day for three months. Her complaints had been started at the second month of this treatment. Dermatologic examination revealed numerous erythematous, painful erythema nodosum like nodules and plaques on lower limbs (Figure 1,2). A biopsy from nodules was performed. Histopathological findings showed a septal panniculitis with vasculitis. Lesions resolved completely with oral ibuprofen without dose reduction or discontinuation of the BRAF and MEK inhibitors. Herein we report a 48-years-old malignant melanoma patient with eritema nodosum like lesion associated with combination of BRAF inhibitor (vemurafenib) and MEK inhibitor (cobimetinib).

Keywords: cobimetinib, eritema nodosum, panniculitis, vasculitis, vemurafenib

3rd INDERCOS

National Dermatology & Cosmetology Congress with International Participants

14-17 MARCH, 2018
HILTON ISTANBUL BOSPHORUS HOTEL
ISTANBUL, TURKEY

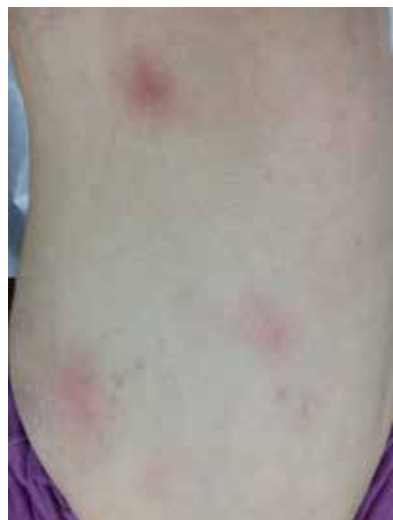

Figure 1



Erythematous, painful erythema nodosum like nodules and plaques on lower limbs

Figure 2



Erythematous, painful erythema nodosum like nodules and plaques on lower limbs



3rd INDERCOS

National Dermatology & Cosmetology Congress with International Participants

14-17 MARCH, 2018
HILTON ISTANBUL BOSPHORUS HOTEL
ISTANBUL, TURKEY

PP-008

[CUTANEOUS ONCOLOGY]

ULCERATED EXTRAMEDULLARY PLASMACYTOMA OF ORAL CAVITY

Irem Mantar¹, Serpil Şener¹, Gülbahar Saraç¹, Hülya Cenk², Didem Kısacık¹, Yelda Kapıcıoğlu¹

¹Department of Dermatology, Inonu University, Malatya, Turkey

²Department of Dermatology, Sorgun State hospital, Yozgat, Turkey

INTRODUCTION: Extramedullary plasmacytoma (EMP) is a malignant plasma cell neoplasm often located in the head and neck region. It's generally seen between fifth and seventh decades of life, with a mean age of 64. While there are EMP cases associated with plasma cell leukemia, as far as we know, there isn't any publication reporting an EMP case accompanied by acute myeloid leukemia (AML). Herein, a young male patient followed up because of his AML and graft versus host disease (GVHD) will be presented for his extensively erosive and ulcerated EMP of the buccal mucosa and tongue. This case is found valuable to share not only for having a rare clinical presentation of EMP but also for being the youngest case in the literature.

CASE: A 21 years old male patient applied to our outpatient polyclinic with a complaint of oral wounds persistent for two years. His dermatologic examination revealed extensive erosions and ulcers of the tongue and buccal mucosa and there were yellowish crusts on the lips along with a white plaque on the right commissural mucosa (figure 1-2). His face and trunk had both hyperpigmented and hypopigmented macules and patches. After histopathological examination showing monoclonal proliferation of plasma cells together with the laboratory and radiological tests, the patient was diagnosed with EMP. The patient was consulted to the Department of Radiation Oncology to be able to evaluated in terms of radiotherapy.

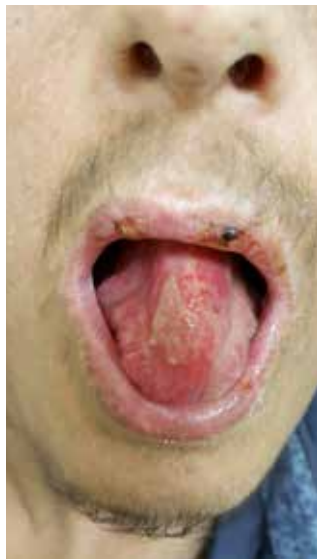DISCUSSION: Generally, EMPs are located in the aerodigestive tract and they are seen as well-demarcated, submucosal solid masses in varying sizes. There are few case reports of ulcerated EMP. The reported cases include an ulcerated mass on labia majora, an ulcerated nodule mimicking a gastric ulcer, an ulcerated lesion on the lateral border of the tongue and an ulcerated mass on the hard palate. Herein, we present an EMP case who has clinically pemphigus-like features with the erosion and ulcers throughout his oral cavity. This case was a young man under immunosuppressive treatment for AML and GVHD. In the literature, there are also EMP cases with concomitant HIV infection and it's considered that these cases have EMP at a younger age with atypic clinical features and faster progression. 20-30 % of EMP cases progress to multiple myeloma (MM) and multiple myeloma development is the most important prognostic factor in the clinical course of the disease. For this reason, complete blood count and the level of serum M protein should be checked at 6-weeks intervals after the diagnosis.

CONCLUSION: Here in this case report, we present a 21 years old EMP patient who has had extensive

erosion and ulcers in his oral cavity. It should be kept in mind that EMP can have atypical clinical characteristics in an immunosuppressive patient, regardless of the age and the patient must be followed up due to the risk of developing multiple myeloma.

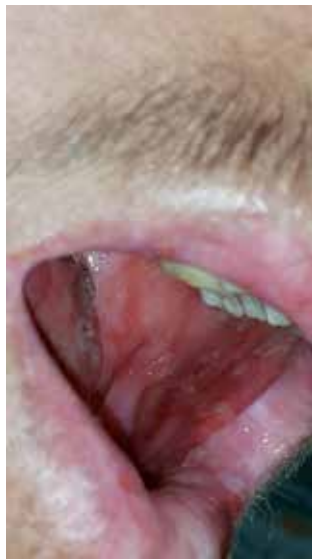Keywords: Extramedullary plasmacytoma, oral cavity, ulcerated

Figure 1



ulcerated lesion on tongue

Figure 2



erosions on buccal mucosa



3rd INDERCOS

National Dermatology & Cosmetology Congress with International Participants

14-17 MARCH, 2018
HILTON ISTANBUL BOSPHORUS HOTEL
ISTANBUL, TURKEY

PP-009

[DERMATOLOGICAL SURGERY] FACIAL ANTI-AGING SURGERY

Martina Vidová Uğurbaş

MD. Martina Vidová Uğurbaş, PhD., Department of Plastic, Reconstruction and Aesthetic Surgery, P.J.Šafarik University, Faculty of Medicine, Košice, Slovakia

Facial Anti Aging Surgery

INTRODUCTION: The skin facial aging is a complex that is the cumulative effect of changes of the many components like ptosis, transform and reduce of fat tissue of the face, loss of elasticity and the interaction of all these components with each other. An understanding of the changes and processes associated with aging is the basis of facial rejuvenation surgery.

Materials & METHODS: The development of facial wrinkles, surface lines or deeper creases and folds, are the early signs of accumulated skin damage. Surgeons have been guided by the empirical finding that people look younger when soft tissue of the lower cheek is shifted into the middle and upper cheek. The repositioning of ptotic tissue is the principle objective which has interested surgeons since facelift surgery began. Facial rejuvenation surgery include facelift, brow lift *coronal brow lift, lateral brow lift, skin excision brow lift*, forehead lift, chin lift, blepharoplasty. Many methods have been described.

RESULTS: On our Department of Plastic, Reconstructive and Aesthetic Surgery of University Hospital L. Pasteura Košice and University P.J.Šafarik facial anti aging surgeries performed with elevated tendency. In our work we point out preoperative care in patients, planning of surgical performance, intraoperative techniques and postoperative results. The operating techniques that have been implemented on our department are with low risk and with very good results.

CONCLUSIONS: Facial anti-aging surgery is very popular treatment all over the world. The poster is complemented by pictures of attachment, "before and after" facial rejuvenation and the most preferred operating techniques on the our department.

Keywords: anti-aging, face aesthetic surgery, facelift

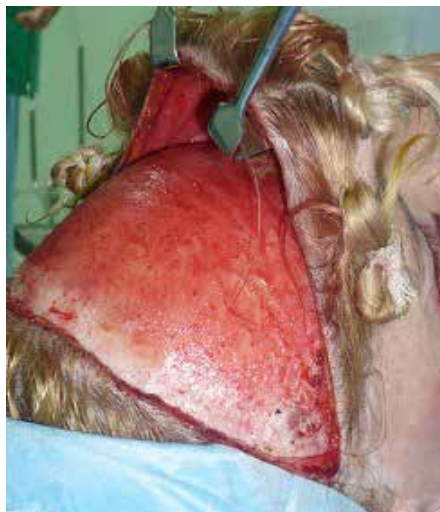3rd INDERCOS

National Dermatology & Cosmetology Congress with International Participants

14-17 MARCH, 2018
HILTON ISTANBUL BOSPHORUS HOTEL
ISTANBUL, TURKEY

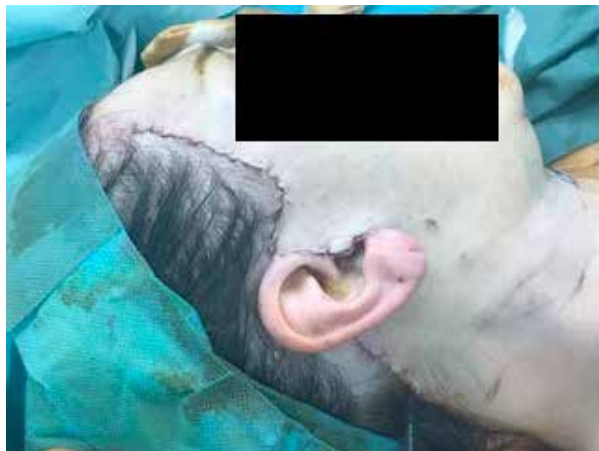

Coronal brow lift



Coronal brow lift - skin flap during surgery.

Face lift



Picture after MACS-face lift.

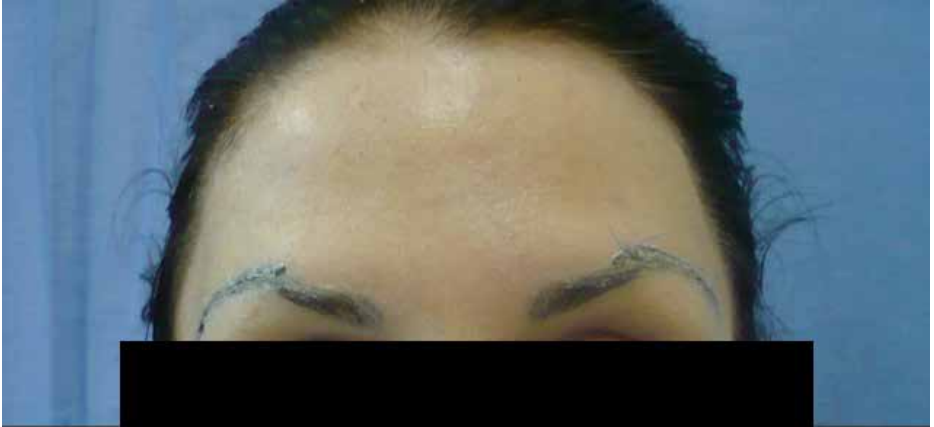

3rd INDERCOS

National Dermatology & Cosmetology Congress with International Participants

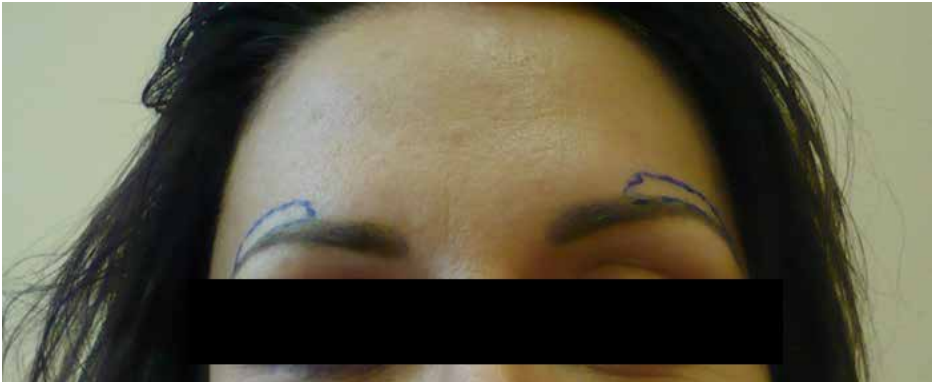14-17 MARCH, 2018
HILTON ISTANBUL BOSPHORUS HOTEL
ISTANBUL, TURKEY

Local brow lift



Picture after operation, result of local brow lift.

Local brow lift



Picture before local - skin excision brow lift.

3rd INDERCOS

National Dermatology & Cosmetology Congress with International Participants

14-17 MARCH, 2018
HILTON ISTANBUL BOSPHORUS HOTEL
ISTANBUL, TURKEY



PP-010

[INFLAMMATORY SKIN DISEASES]

FOX FORDYCE DISEASE IN A PREPUBESCENT PATIENT

Hind Benhiba¹, Mouna Rimani²

¹Dermatologist, Private Practice, Rabat, Morocco

²Anatomopathologist, Hassan Anatomo-pathology Center, Rabat, Morocco

INTRODUCTION: The FoxF ordyce disease (FFD) is a rare inflammatory dermatosis that affects mainly young women between 13 and 35 years. It is characterized by multiple itchy follicular papules, localized in areas rich in apocrine glands. There are few reports in prepubescent patients. Here we describe the case of an 11 year old girl.

CASE: A female patient sought care for itchy cutaneous lesions on the armpits and pubic area which appeared at 9 years of age (2 years before menarche). At examination we observed small normochromic papules measuring up to 2 mm, predominantly follicular, on the armpits and pubic area, the patient had accentuated reduction of hairs on the armpits and reported worsening of the itch with warm weather. Besides, she did not have any clinical sign of hormonal dysfunction, like menstrual irregularity, obesity, hirsutism or acne. Incision biopsy of the right armpit showed hypekeratosis, parakeratosis and irregular acanthosis over the area of the apocrine gland exit, as well as spongiosis along the epidermis also involving the hair follicle, which still showed neutrophils exocytosis. The dermis had a mild, superficial, perivascular and interstitial lymphocytic infiltrate. The histopathological exam was compatible with FFD. We chose the topical treatment with 0.1% adapalene gel. After 2 months there was remarkable decrease of the papules and the itch.

DISCUSSION: FFD is a chronic disorder of the apocrine glands which affects mostly young women. The etiology remains unknown. It is postulated that a hormonal disturbance is involved. So far no genetic factor has been blamed either, despite the existence of familial cases. The physiopathology consists on the obstruction of the apocrine gland duct by a keratin plug in its insertion on the hair follicle wall, which causes secretion retention with consequent rupture of the glandular structure and secondary inflammation of the dermis. The extravasation of the glandular content can be the cause of the itch. Clinically, the disease is characterized by multiple follicular papules, skin color or brownish, located in areas rich in apocrine glands, like arm pits, periareolar areas, and pubic area, accompanied by itch. The histopathological findings are variable and include infundibular plug, hyperkeratosis, acanthosis, spongiosis and unspecified inflammatory infiltrate. The main differential diagnoses are keratosis pilaris, lichen planopilaris, amyloidosis lichenoides, lichen nitidus and eruptive syringoma. Various treatments were suggested: oral contraceptives, topical, intralesional or systemic corticosteroids, topical and oral retinoid, topical clindamicin, tacrolimus, phototherapy and surgical treatments.

CONCLUSION: We report a case of Fox Fordyce disease revealed at pubertal period by clinical and histopathologic examination and discussed therapeutic effects in the light of literature.

Keywords: Fox Fordyce Disease, Apocrine glands, Treatment Outcome



3rd INDERCOS

National Dermatology & Cosmetology Congress with International Participants

14-17 MARCH, 2018
HILTON ISTANBUL BOSPHORUS HOTEL
ISTANBUL, TURKEY

PP-011

[MISCELLANEOUS]

CUTANEOUS MUCINOSIS WITH CHARACTERISTIC LION FACE APPEARANCE

Selami Aykut Temiz¹, Recep Dursun¹, Arzu Ataseven¹, Ilkay Özer¹, Siddika Findik²

¹Department of Dermatology, Necmettin Erbakan University Meram Faculty of Medicine, Konya, Turkey

²Department of Pathology, Necmettin Erbakan University Meram Faculty of Medicine, Konya, Turkey

Cutaneous mucinosis includes a heterogeneous group of skin diseases characterized by the deposition of mucin in the interval of the dermis. Mucin is a protein ordinarily found as part of the dermal connective tissues. Mucin is a mucopolysaccharide produced by mast cells and fibroblasts and includes hyaluronic acid and sulfated glycosaminoglycans. As hyaluronic acid holds water, in disease states where mucin manufacture is increased, the dermal connective tissue happens swollen and is defined as myxedematous.

Scleromyxedema differs from other skin mucinosis by four diagnostic findings; generalized papular and sclerodermoid eruption, dermal mucin accumulation with fibroblast proliferation and fibrosis, and monoclonal gammopathy without thyroid disease. Systemic mucin deposition may consist systemic involvement, monoclonal gammopathy or paraproteinemia were detected in the large majority (83.2%) of scleromyxedema cases.

A 50-year-old woman presented with pruritic, flesh-colored papules disseminated whole body (Figure 1). There was a characteristic lion face appearance (Figure 2). These lesions first appeared eighteen months ago in the neck. In the patient's medical history, she had migraine. The patient's protein electrophoresis and bone marrow biopsy were normal. Histopathological examination revealed widespread mucin accumulation with alcian blue and colloidal iron stains in papillary and reticular dermis (Figure 3,4). Granuloma structure was not seen in CD68 staining, no amyloid accumulation with amyloid staining. The final diagnosis was cutaneous mucinosis. The patient was treated with oral hydroxychloroquine 200 mg twice daily and topical pimecrolimus cream.

Here, we present a case of generalized primary cutaneous mucinosis patient without any systemic disease.

Keywords: Cutaneous mucinosis, lion face, scleromyxedema, hydroxychloroquine, pimecrolimus

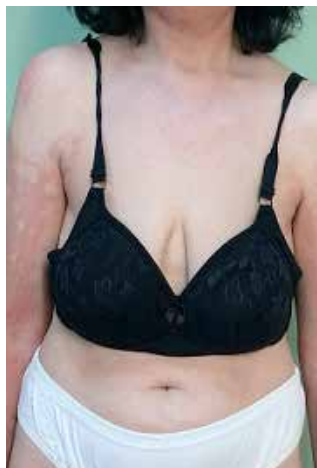3rd INDERCOS

National Dermatology & Cosmetology Congress with International Participants

14-17 MARCH, 2018
HILTON ISTANBUL BOSPHORUS HOTEL
ISTANBUL, TURKEY

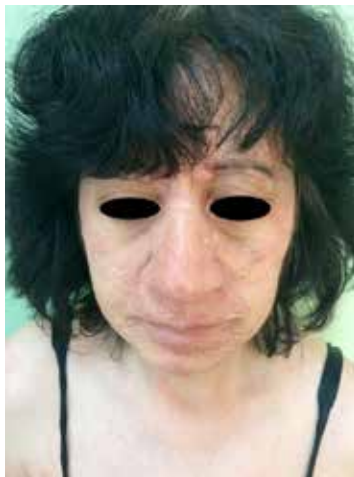

Figure 1



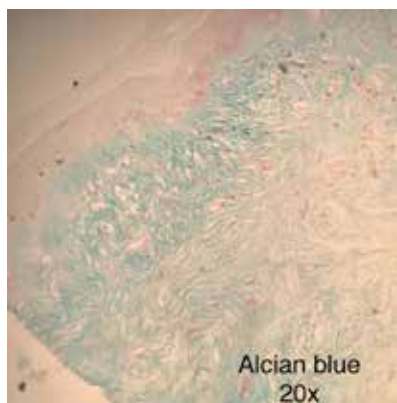
Flesh-colored papules disseminated on whole body

Figure 2



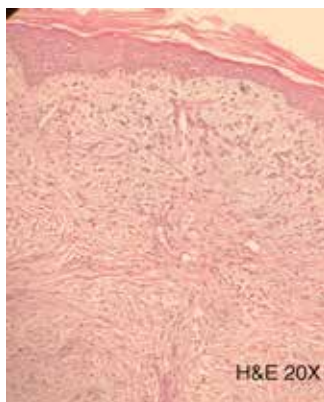
Characteristic lion face appearance

Figure 3



Histopathological examination revealed widespread mucin accumulation with alcian blue stain in papillary and reticular dermis

Figure 4



Widespread mucin accumulation with hematoxylin and eosin stain in papillary and reticular dermis



3rd INDERCOS

National Dermatology & Cosmetology Congress with International Participants

14-17 MARCH, 2018
HILTON ISTANBUL BOSPHORUS HOTEL
ISTANBUL, TURKEY

PP-012

[CONTACT AND OCCUPATIONAL DERMATITIS]

ACUTE DERMATITIS DUE TO TEGADERM USAGE WITH RADIATION DERMATITIS IN THE LAST WEEK OF TREATMENT IN BREAST CARCINOMA: A CASE REPORT

Elif Emine Ozkan¹, Selma Korkmaz², Ijlal Erturan², Mehmet Yıldırım²

¹Suleyman Demirel University, Department of Radiation Oncology, Isparta, Turkey

²Suleyman Demirel University, Department of Dermatology, Isparta, Turkey

INTRODUCTION: Acute radiation dermatitis can be seen during treatment or soon after breast radiation. Tegaderm is a transparent gelform film which is used to locate treatment areas. Allergic reactions caused by Tegaderm is also occasionally observed despite its known antimicrobial and anti-allergic feature. Herein a case of breast carcinoma under radiotherapy with contact dermatitis due to tegaderm overlapping radiodermatitis is presented.

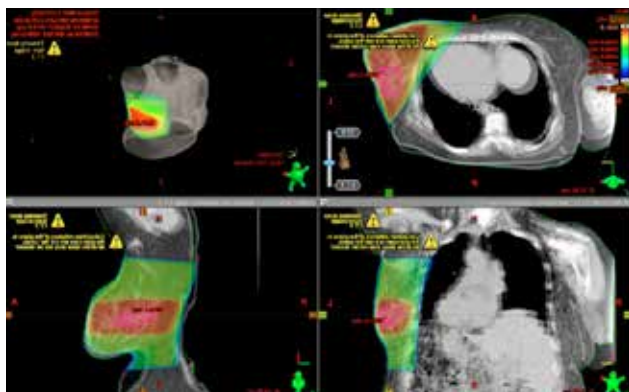
CASE: A 62-year-old woman underwent quadraneectomy and sentinel lymph node sampling with a diagnose of invasive breast carcinoma of the left breast. The tumor measured 18 mm in greatest dimension and 3 sampled lymph nodes were negative for tumor. The right breast was treated with radiotherapy, 5,000 cGy in 25 fractions to whole breast and an additional 1000 cGy in 5 fractions to tumor bed. Outlook of dosimetric results is shown in Figure 1. In weekly exams during treatment only erythema was reported till 5th week. She was treated with silver sulfadiazine, topical dexpanthenol for this reaction. On the last weekly exam edema, a localized wet desquamation and an explicit erythema in accordance with treatment portal has arised (Figures 2 A and B). The localized wet desquamation was in the area of tegaderm which was used to indicate the boost portal localization. White blood cell count and inflammatory markers (sedimentation and c-reactive protein levels) was in normal ranges. As a result she was diagnosed as contact dermatitis overlapping radiodermatitis and treatment with fucidic acid and betamethazone valerate, a topical agent including Hamamelis virginiana extract and another topical agent including Centella asiatica extract was started. In the first week follow up all the signs were recovered with only a mild hypo and hyperpigmented areas.

DISCUSSION: Ionizing radiation can cause acute or late cutaneous injury depending on field size, radiation dose and duration. Acute radiodermatitis is characterized by erythematous, edematous and patchy erosions arising 3-6 days after radiotherapy. Mostly the clinic is apparent after 15 – 25 Gy treatment. In our patient despite no significant skin reactions were seen in the first 5 weeks; after 50 Gy in 6th week with the start of boost treatment symptoms progressed and became apparent. Tegaderm which we used to locate the boost field can cause contact dermatitis. For this case, both usage of tegaderm and radiotherapy resulted in overlapping contact dermatitis with radiodermatitis. After the topical medical treatment the lesions decreased and the patient is on follow up.

CONCLUSION: It must be taken into consideration that transparent film products such as Tegaderm which are used to locate treatment fields in patients undergoing radiotherapy due to breast cancer may enhance skin reactions.

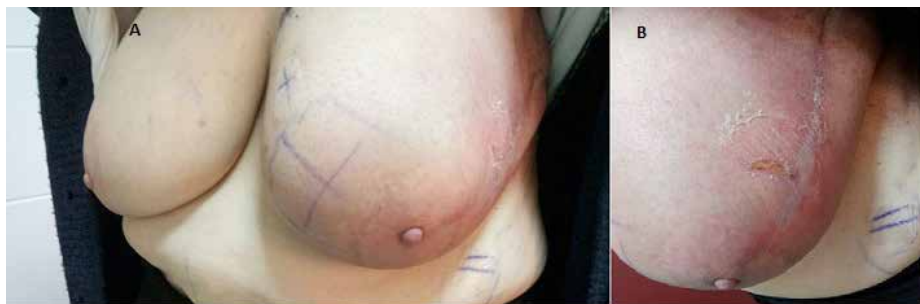Keywords: contact dermatitis, radiodermatitis, tegaderm

Figure 1



Transverse, sagittal and coronal views and 3D perspective of dose distribution

Figure 2 A and B



Patchy squam on the erythematous ground in lateral of left breast and an erosion of 2 x 1 cm with a yellow crust on it



3rd INDERCOS

National Dermatology & Cosmetology Congress with International Participants

14-17 MARCH, 2018
HILTON ISTANBUL BOSPHORUS HOTEL
ISTANBUL, TURKEY

PP-013

[INFECTIOUS DISEASES, PARASITIC DISEASES, INFESTATIONS]

"TREATMENT OF RECURRENT RECALCITRANT FACIAL CUTANEOUS LEISHMANIASIS IN A 9 - YEAR - OLD SYRIAN REFUGEE"

Ebru Celik¹, Gulnaz Culha², Ahmet Ozbilgin³

¹Department of Dermatology, Faculty of Medicine, Mustafa Kemal University, Hatay, Turkey

²Department of Parasitology, Faculty of Medicine, Mustafa Kemal University, Hatay, Turkey

³Department of Parasitology, Faculty of Medicine, Celal Bayar University, Manisa, Turkey

BACKGROUND: Cutaneous leishmaniasis (CL) is a protozoan infection of skin caused by different species of *Leishmania* genus. The parasite is transmitted by the bite of sand flies to skin and replicated in the phagocytes. Localized inflammatory response to parasite constitute the skin lesions. *L. Braziliensis* and *L. Mexicanaspecies* in the New World and *L. Tropica*, *L. Major* and *L. aethiopica* species in the Old World are responsible for the disease. Cutaneous leishmaniasis is endemic in Syrian. One of the clinical forms of this disease is leishmaniasis recidivans (LR). Most patients with LR are resistant to the usual treatments.

CASE: A 9-year-old Syrian refugee male patient presented at our clinic with multiple papular and plaque lesions located in the left cheek, lips and chin (Figure 1). In addition, he had large atrophic scar on the cheek. He had had these lesion for three years, and they had gradually enlarged. He was immune competent and denied any trauma. The duration of disease in the patient was more than 3 years and he had previously been treated for their cutaneous leishmaniasis by different methods. He had been treated with a combination of intralesional and intramuscular meglumine antimoniate (MA) (20 mg/kg/day for 15 days), cryotherapy in the first treatment two years ago. Than he received oral fluconazole treatment for three mounts, after six months later he comes recurrent lesions in all localizations and he was again treated with intramuscular meglumine antimoniate (MA) (20 mg/kg/day for 20 days). After being discharged from the hospital he received oral azithromycin for two months and oral terbinafine treatment for six months. Unfortunately all lesions relapse a few months later. And we wanted to choose other effective and safe antileishmanial agents, combination of intralesional and intravenous sodium stibogluconate (Pentostam) (20 mg/kg/day for 30 days). The drugs were well tolerated by the patients producing no side effects nor any significant changes in laboratory values. The diagnosis of recurrent cutaneous leishmaniasis was made following parasitological smear revealed *Leishmania* parasites in their amastigote form (Figure 2). In addition, the detection of parasite DNA by the polymerase chain reaction (PCR) was performed in this recalcitrant case. For DNA isolation and the PCR assay, genomic DNA was extracted from isolates and non-stained smears using a 'High Pure PCR Template Preparation Kit' according to manufacturer's instructions. The patient sample was typed as *L.tropica*.

3rd INDERCOS

National Dermatology & Cosmetology Congress with International Participants

14-17 MARCH, 2018
HILTON ISTANBUL BOSPHORUS HOTEL
ISTANBUL, TURKEY



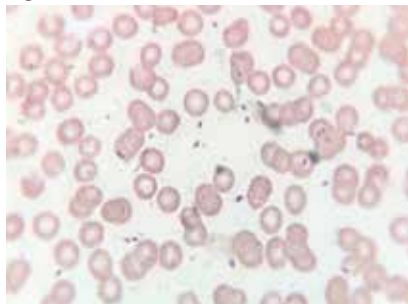
CONCLUSIONS: While pentavalent antimonials have been the mainstay of antileishmanial treatment for decades, newer therapeutic options have become available for all forms of infection, including liposomal amphotericin B, miltefosine, fluconazole, and ketoconazole. We recommend treating recurrent forms of leishmaniasis with a full 20 mg/kg/day of pentavalent antimony before the other systemic treatments.

Keywords: Cutaneous Leishmaniasis, recurrent, recalcitrant, treatment

Figure 1

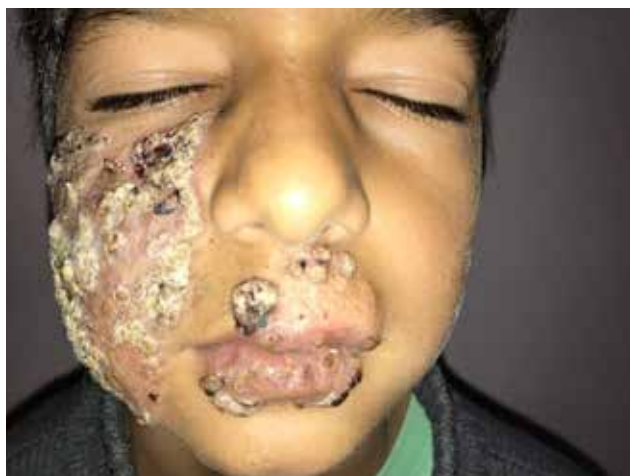

Figure 2



Leishmania sp. amastigotes in a Giemsa-stained tissue scraping



3rd INDERCOS

National Dermatology & Cosmetology Congress with International Participants

14-17 MARCH, 2018
HILTON ISTANBUL BOSPHORUS HOTEL
ISTANBUL, TURKEY

PP-014

[ATOPIC DERMATITIS/ECZEMA] DUKHAN DERMATITIS

Ilkin Zindancı¹, Melike Kibar Öztürk¹, Ebru Zemheri²

¹Department of Dermatology, Umraniye Training and Research Hospital, Istanbul, Turkey

²Department of Pathology, Umraniye Training and Research Hospital, Istanbul, Turkey

Despite the widespread use of scented smoke baths (Dukhan) in Africa and America, any skin diseases caused by *Acacia seyal* and *Terminalia brownii* have yet to be reported in the literature. On the other hand, *Terminalia brownii* is known with its antibacterial and antioxidant properties and the use of smoke from *Acacia seyal* is associated with an increased risk of visceral leishmaniasis. Eleven women with Fitzpatrick skin type 5 and 6 presented to the dermatological department for intense pruritus and dryness of the skin. The mean age of patients were 32 \pm 4 and all of them were housewives. Physical examination showed brown-erythematous excoriated papules and plaques and lichenification confined to the sites of scented smoke baths; legs and thighs. (pic 1-2) The patients admitted using scented smoke baths weekly on the specific sites as legs, thighs, hips and vagina. Examination of the entire skin including mucous membranes, scalp, hair, nails and anogenital region revealed normal findings. They explained the reasons of this body incensing as curing aches, cleanliness, health, for restoration after childbirth, sensuality and eroticism. It was believed to boost sexual gratification according to all eleven women. They told that they put a blend of scented 'shaff' and 'talih' placed inside a hole, then they produced scented smoke with charcoal. They placed a birish rug woven from palm tree branches with a central opening over this hole, then women striped totally naked and sat over the hole, allowing the rising smoke to fumigate their body. The patients admitted that they all took the same two kind of woods: *Acacia seyal* and *Terminalia brownii* (pic 3). After the repeated use of these smoke baths once a week for 3 months, they felt intense pruritus and observed pruritic papules and vesicles after each bath. Within the following weeks, they felt dryness and thickening of their skin accompanied with pruritic lichenified papules. They had no history of allergic diseases or drug intake, and were all otherwise in good general health. A skin biopsy specimen (pic 4) from these lesions showed parakeratosis, acanthosis and increased granular layer on epidermis, lymphocytic infiltration around small vessels in papillary dermis. The result of histopathological examination was reported as subacute spongiotic dermatitis. The patients were then administered high potent corticosteroid therapy topically twice a day and prompted to stop these baths. The lesions in all patients were healed at 1 month with post-inflammatory hyperpigmentation. No recurrence was noted in 6 months follow-up.

Keywords: *Acacia seyal*, *Terminalia brownii*, dermatitis, Dukhan, contact dermatitis

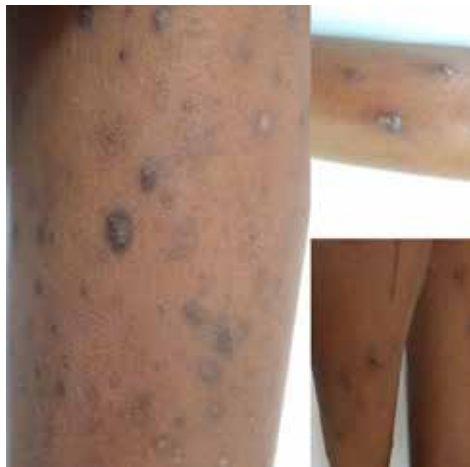3rd INDERCOS

National Dermatology & Cosmetology Congress with International Participants

14-17 MARCH, 2018
HILTON ISTANBUL BOSPHORUS HOTEL
ISTANBUL, TURKEY

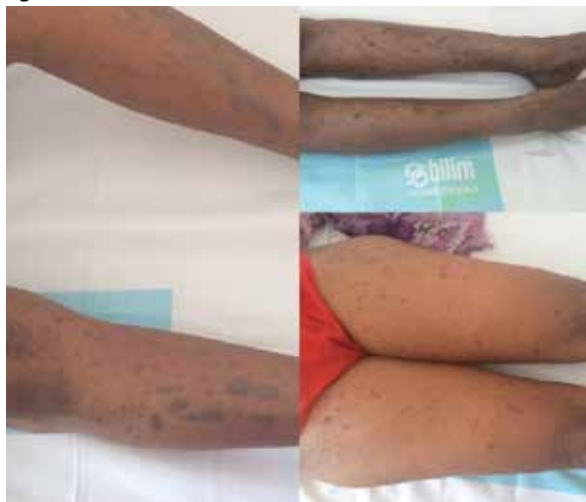

figure 1



Clinical pictures of Dukhan dermatitis

figure 2



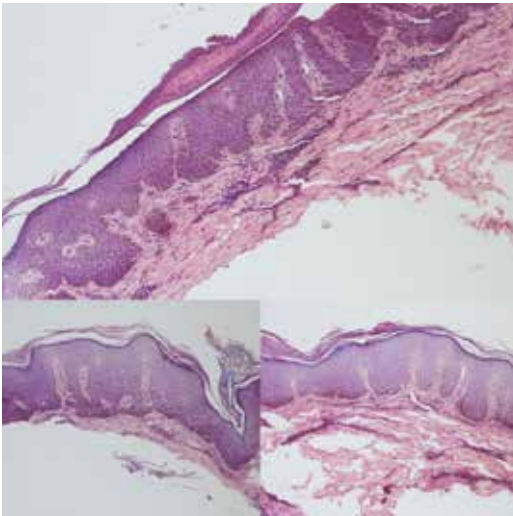
Clinical pictures of Dukhan dermatitis

Figure 3



Two kind of woods: Acacia seyal and Terminalia brownii

Figure 4



Histopathological pictures of Dukhan dermatitis

3rd INDERCOS

National Dermatology & Cosmetology Congress with International Participants

14-17 MARCH, 2018
HILTON ISTANBUL BOSPHORUS HOTEL
ISTANBUL, TURKEY



PP-015

[CUTANEOUS ONCOLOGY]

"BASAL CELL CARCINOMA MIMICKING ECZEMA OF THE HEEL"

Gamze Serarslan¹, Tumay Ozgur², Mehmet Yaldiz³, Ebru Celik¹

¹Mustafa Kemal University, Faculty of Medicine, Department of Dermatology, Hatay, Turkey

²Mustafa Kemal University, Faculty of Medicine, Department of Pathology, Hatay, Turkey

³Mersin University, Faculty of Medicine, Department of Pathology, Mersin, Turkey

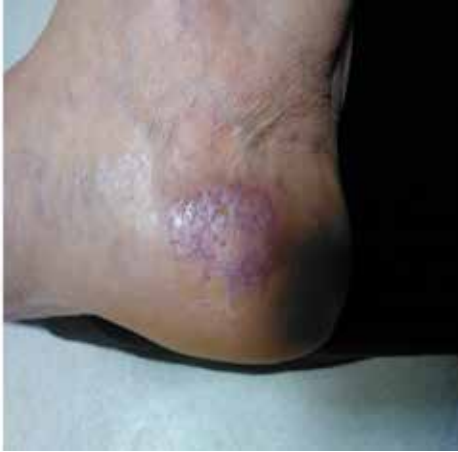INTRODUCTION: Basal cell carcinoma (BCC) on the foot is rare and there were limited case reports. We present a patient with BCC mimicking eczema localized to heel. To the best of our knowledge there has been no report of BCC localized to the heel.

CASE: A 64-year-old female, presented with an asymptomatic lesion on her right heel. The lesion had been present for approximately 18 months. She had used topical and systemic antifungal and topical corticosteroid medications without improvement. She had diabetes mellitus and hypertension. There was no history of trauma or arsenic exposure history. On examination there was a plaque located on the medial side of the heel of the right foot (Figure 1). The lesion was 5x3 cm in diameter and erythematous in colour. There were no palmar and plantar pits. Skin scraping taken from the lesion was examined with KOH and fungal elements were not detected. A punch biopsy was taken and pathologic examination revealed tumor island in the papillary dermis (Figure 2). BCC was diagnosed and was sent for complete excision by the plastic surgery department. Second pathologic examination was also confirmed the diagnosis of BCC.

DISCUSSION: Basal cell carcinoma is the most common cancer in white-skinned people and is frequently seen head and neck localization, followed by trunk and extremities. BCC localized on the foot was very rarely seen. There were fewer than 40 cases of BCC reported on the foot, accounting for less than 1% of all cases. Dorsum of the foot, sole, and toe were some reported localizations. To the best of our knowledge there was no reported case localized to the heel. Basal cell carcinoma is a complex disease because the likelihood of developing this tumour depends on the interplay between constitutional predisposition (genotypic and phenotypic characteristics) and subsequent exposure to environmental risk factors. Ultraviolet radiation, photosensitizing drugs, chemicals, smoking, and ionizing radiation are some environmental risk factors. There was no possible etiologic factor in our patient. Trauma has been also reported to be a possible risk factor. Although there was no history of trauma in our patient, especially heel was prone to trauma. As localization of the lesion was atypical, diagnosis was delayed in our patient. Therefore biopsy is required to prevent misdiagnosis and delay in treatment in such cases."

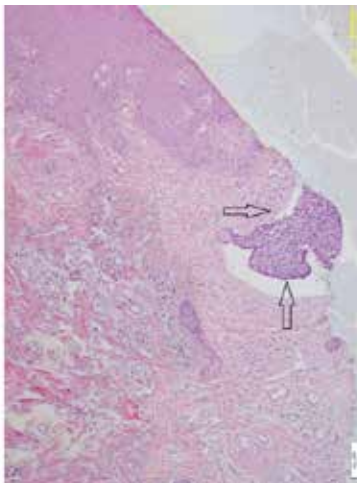
Keywords: Basal cell carcinoma, heel, mimicking eczema

Figure 1



An erythematous plaque on the heel of the right foot.

Figure 2



Tumor island in the papillary dermis with typical features of basal cell carcinoma (H&E X 100).



PP-016

[CONTACT AND OCCUPATIONAL DERMATITIS]

"REACTION TO RED PIGMENT TATTOO UNRESPONSIVE TO CORTICOSTEROIDS"

Gamze Serarslan¹, Mehmet Yaldız², Ebru Celik¹

¹Mustafa Kemal University, Faculty of Medicine, Department of Dermatology, Hatay Turkey

²Mersin University, Faculty of Medicine, Department of Pathology, Mersin, Turkey

INTRODUCTION: As popularity of tattooing has been increasing in the population, the prevalence of adverse reactions to tattoo has also been increased. The treatment of these reactions may be problematic. Red is the color most commonly associated with adverse tattoo reactions. Here we report a patient with reaction to red tattoo pigment and unresponsive to topical and intralesional corticosteroids.

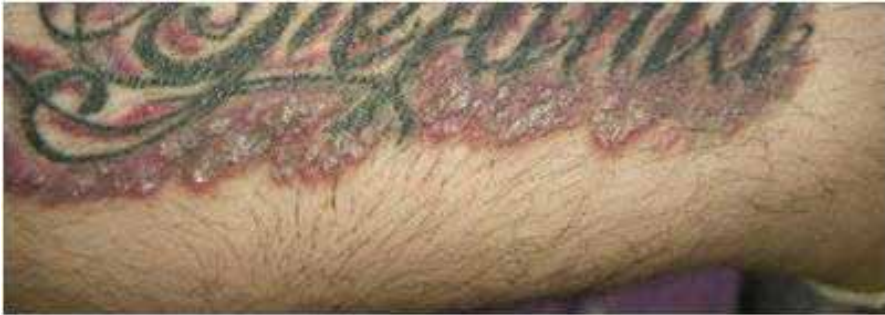CASE: A 23-year-old man presented with erythema on his tattoo on his right arm. The tattoo has been performed one month ago and erythema has been occurred one week later. There was not symptom including pruritus. Physical examination revealed a tattoo composed of green, black and red pigments on his medial side of right arm and there were erythematous papules restricted to the red pigment tattoo (Figure 1). Figure 2 shows the dermoscopic image of the lesion. It could be clearly seen that the reaction was restricted to the red pigment with dermoscopy. Punch biopsy was performed from the lesion. Histological examination revealed lichenoid inflammation of the dermoepidermal junction with multinuclear giant cells at the dermis (Figure 3). Clobetasol propionate cream (0.05%) was prescribed. There was no response at the end of three weeks. Intralesional triamcinolone acetonide was administered. Erythema was regressed partially in two weeks however lesions were restarted one week later. Intralesional corticosteroid therapy reused but there was no response. Therefore surgical excision was proposed.

DISCUSSION: Red is the color most commonly associated with adverse tattoo reactions. Red tattoo pigments were traditionally made from mercury derivatives, then from cadmium derivatives, which are currently prohibited because of toxicity. Although tattoos contain synthetic organic pigments, which carry a lower risk of adverse reactions, the majority of complications remain linked to the red-inked areas. Our patient did not know which kind of tattoo had been used. Reaction times have ranged from a few weeks to 3 years after tattooing. Adverse reaction to red pigment can be divide into inflammatory, infectious and neoplastic. The inflammatory reaction includes lichenoid, eczematoid, foreign body granulomatous, sarcoidal and pseudolymphomatous reactions, and sometimes vasculitic reactions. The most common histopathologic pattern is lichenoid pattern. In our case histopathology revealed lichenoid inflammation and there were also multinuclear giant cells. Topical and intralesional corticosteroids are treatment options. However it was unsuccessful in our patient. Electrosurgery, surgical excision, dermabrasion, chemical destruction, or ablation via a non-Q-

switched laser such as carbon dioxide device are other treatment modalities

CONCLUSION: Dermatologists should be aware of reactions to tattoo, and also population should be raised awareness of side effects of tattooing."

Keywords: Red, corticosteroid, reaction, tattoo



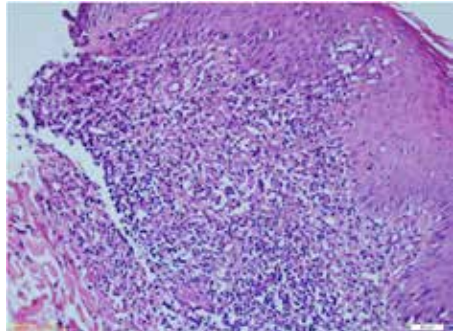
Erythematous papules on the red pigment tattoo.

Figure 2



Dermoscopic image shows the reaction is restricted to the red pigment

Figure 3



Lichenoid inflammation at dermoepithelial junction and multinuclear giant cells at the dermis (H&E x 40).

3rd INDERCOS

National Dermatology & Cosmetology Congress with International Participants

14-17 MARCH, 2018
HILTON ISTANBUL BOSPHORUS HOTEL
ISTANBUL, TURKEY



PP-017

[CUTANEOUS ONCOLOGY]

CUTANEOUS METASTASIS FROM COLORECTUM CANCER: A CASE REPORT

Aslı Özçentik¹, Betül Ünal², Erkan Alpsoy¹

¹Department of Dermatology and Venereology, Akdeniz University, Antalya, Turkey

²Department of Pathology, Akdeniz University, Antalya, Turkey

INTRODUCTION: Colorectum cancers metastasizes most frequently to the liver and the lung. Cutaneous metastases from Colorectum cancers are rare and the reported incidence is less than 4%. They are usually 1-2 cm in diameter, dermal or subcutaneous nodules presenting on the abdominal wall, perineal region or surgical incision sites. Sometimes it may be the first diagnostic finding, although it is usually associated with poor prognosis and signals advanced disease. Case presentation: A 37-year-old male patient presented to our department with a 2-months-history of crusted nodule on the abdomen. Dermatologic examination revealed a bright red, centrally crusted tumoral lesion about 4 cm in size, on the right upper quadrant of abdomen. The patient had a history of colorectal cancer diagnosis in 2014 (histopathologic subtype, mucinous adenocarcinoma). He was stage IIIC (T4N2M0) at the time of diagnosis and received adjuvant radiotherapy, one cure of 5-fluorouracil and calcium folinate chemotherapy after abdominoperineal resection. The patient was lost the follow-up for 1.5 years. The PET CT scan of the patient in 2015 revealed hypermetabolic focuses in the operation area, presacral region and lung; metastatic rectum cancer was diagnosed. He received multiple chemotherapy treatments irregularly. PET CT, taken in November 2017 showed metastatic foci on the retroperitoneum, on the mesentery, and on the medial line on the anterior wall of the abdomen. He admitted to our clinic in November 2017 and biopsy from the patient's lesion was consistent with mucinous adenocarcinoma skin metastasis.

CONCLUSION: Skin metastases from colorectal cancer have rarely been reported and sometimes they can be early signs of an internal organ malignancy or they can signify disseminated disease and poor prognosis as in our case. Cutaneous metastasis should be considered especially when atypical, rapidly growing and infiltrating nodule/tumours are seen. The diagnosis can be made with a good history to be taken from the patient, careful clinical and laboratory studies.

Keywords: rectal cancer, cutaneous metastasis, pathological biopsy



3rd INDERCOS

National Dermatology & Cosmetology Congress with International Participants

14-17 MARCH, 2018
HILTON ISTANBUL BOSPHORUS HOTEL
ISTANBUL, TURKEY

PP-018

[WOUNDS, CHRONIC WOUNDS, WOUND HEALING, ULCER] TRIGEMINAL TROPHIC SYNDROME

Ali Karakuzu, Kıymet Handan Keleşçi, Fatma Şule Afşar, Işıl Ezgi Urgancı Tatlı

Department of Dermatology, Katip Çelebi University Atatürk Research and Training Hospital, İzmir, Turkey

INTRODUCTION: Trigeminal trophic syndrome is an unusual complication of peripheral or central damage to the trigeminal nerve. The syndrome consists of a triad of anesthesia, paresthesia, and a secondary persistent or recurrent facial ulceration. We report a case of trigeminal trophic syndrome following brain surgery in a 48-year-old woman.

CASE: A 48-year-old woman complained of nonhealing ulcer over the right nostril of one year duration. Dermatological examination revealed sharply demarcated superficial ulcer and surrounding erythema over the right nostril. And also there was a scar formation right side of upper lips. (Fig.1,2) Three years previously, the patient had had a brain surgery for the benign tumoral lesion and there was a scar because of this surgery on the scalp. After two years, severe itching, tingling sensation and numbness over the right side of the face started. The patient reported regularly picking and scratching the area. Neurologic examination confirmed trigeminal anesthesia. Trigeminal trophic syndrome was diagnosed based on the nasal ulceration, trigeminal anesthesia and a history of surgery which can cause trigeminal damage. The ulcer was not thought to be of infectious origin or a vasculopathy or the other possible etiologic factors, so histopathological examination was not needed. Gabapentin 1200mg/day and topical antibiotic were prescribed, and the patient was educated about the self-induced nature of the ulceration. One month later, ulceration was healed and the sense of anesthesia was decreased.

DISCUSSION: Trigeminal trophic syndrome is a rare disease resulting from self-manipulation of the affected area after a peripheral or central damage to the trigeminal nerve. The syndrome consists of a triad of anesthesia, paresthesia and a recurrent ulceration. It is believed that paresthesia in the sensory distribution of the trigeminal nerve provoke itching, rubbing behavior and these behaviors cause non-healing ulceration. The diagnosis based on the clinical features, but for excluding other etiologic causes histopathological examination can be performed. Histopathology is non-diagnostic and it only shows chronic ulceration with inflammatory infiltrate and no giant cell, granulomas or vasculitic lesions. Treatment of Trigeminal Trophic Syndrome is challenging. Patient must be warned about self-mutilation behaviors like itching, rubbing, removing the crust, cause non-healing ulcers. Adding to behavioural modifications, covering the wound with topical antibiotics, or covering patient's hands can be useful. Control of paraesthesia by medical treatment amitriptyline, chlorpromazine, carbamazepine, intralesional triamcinolone acetonide, and for some patients transcutaneous electrical stimulation, iontophoresis and nerve blockage, surgery are successful treatments.

3rd INDERCOS

National Dermatology & Cosmetology Congress with International Participants

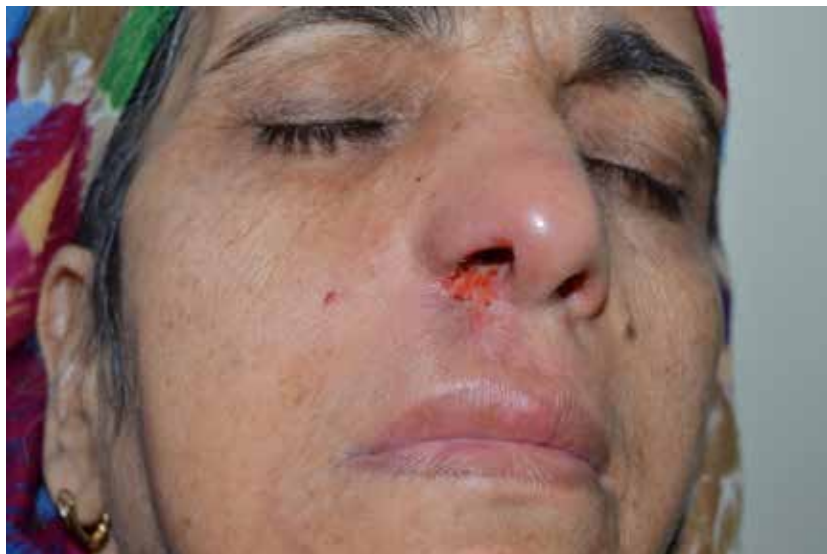14-17 MARCH, 2018
HILTON ISTANBUL BOSPHORUS HOTEL
ISTANBUL, TURKEY



CONCLUSION: In conclusion we present a case of Trigeminal Trophic Syndrome to increase the awareness of this rare condition.

Keywords: trigeminal nerve, facial ulceration, brain surgery

Figure 1



PP-019

[INFECTIOUS DISEASES, PARASITIC DISEASES, INFESTATIONS]

A CASE OF TULAREMIA MIMICKING VENEREAL DISEASES

Ali Haydar Parlak, Güliden Konur, Betül Şerefican

Department of Dermatology, Abant İzzet Baysal University, Bolu, Turkey

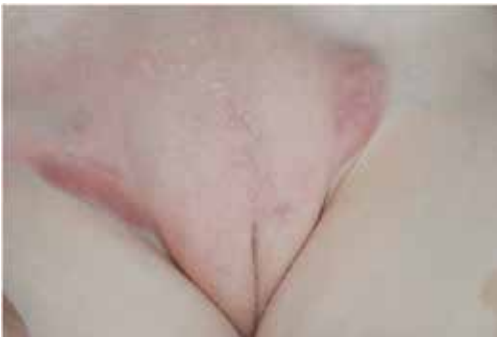INTRODUCTION: Tularemia is an infectious disease caused by a gram negative nonmotile coccobacillus called francisella tularensis. Depending on the mode of transmission, it can be encountered in several different clinical forms. Here, we presented a case of tularemia that accompanies with inguinal lymphadenopathy, which has rarely been reported in our country.

CASE: A sixty-year-old female patient applied with the complaints of tenderness, swelling and redness in the groin that had been started ten days before. Her dermatologic examination revealed erythema and edema on mons pubis and bilateral fluctuating lymphadenopathies in the inguinal region. Tularemia microagglutination test was 1/160 positive. The patient recovered with the appropriate treatment with the diagnosis of tularemia.

DISCUSSION: The clinical findings of the case that presented to our outpatient clinic with the complaints of bilateral inguinal lymphadenopathy and vulvar edema, first brings venereal diseases to mind which can cause inguinal lymphadenopathy such as lymphogranuloma venerum and syphilis. Since tularemia is endemic in our country, it can present with various clinical findings. Although the most common form is ulceroglandular tularemia, oropharyngeal tularemia is more common in our country. Glandular tularemia is one of the rare forms. We report this case to remind that tularemia should be thought in the differential diagnosis of the patients that present with inguinal lymphadenopathy.

Keywords: Tularemia, venereal disease, inguinal lymphadenopathy

Figure 1



Bilateral inguinal indurated nodulocystic lesions with fluctuation

3rd INDERCOS

National Dermatology & Cosmetology Congress with International Participants

14-17 MARCH, 2018
HILTON ISTANBUL BOSPHORUS HOTEL
ISTANBUL, TURKEY



PP-020

[CUTANEOUS ONCOLOGY]

A CASE OF CUTANEOUS MARGINAL ZONE LYMPHOMA MIMICKING A SUBCUTANEOUS VASCULAR LESION

Melike Kibar Ozturk¹, Ilkin Zindanci¹, Fatıma Gursoy², Ebru Zemheri²

¹Department of Dermatology, Sağlık Bilimleri University, Umraniye SUAM Training and Research Hospital, Istanbul, Turkey

²Department of Pathology, Sağlık Bilimleri University, Umraniye SUAM Training and Research Hospital, Istanbul, Turkey

Primary cutaneous marginal zone lymphoma (PCMZL) is an indolent B-cell lymphoma composed of small B-cells, lymphoplasmacytoid cells, and mature plasma cells. It is included in the group of extranodal marginal zone lymphoma of mucosa-associated lymphoid tissue (MALT) lymphoma. PCMZL presents as single or more often multifocal, asymptomatic, or lesions that tend to enlarge slowly. They appear papules or nodules with shiny surface and no desquamation, more frequently localized at the arms or trunk.

We present a 74 years-old woman who admitted our clinic with erythematous-purple subcutaneous nodules which are resembling deep vascular lesion on her abdomen skin. PCMZL diagnosis has been made histopathologically. We want to draw attention to the clinical appearance of lymphoma resembling vascular lesion.

Keywords: Primary cutaneous marginal zone lymphoma, cascular lesion, histopathology,



3rd INDERCOS

National Dermatology & Cosmetology Congress with International Participants

14-17 MARCH, 2018
HILTON ISTANBUL BOSPHORUS HOTEL
ISTANBUL, TURKEY

PP-021

[DERMATOLOGICAL SURGERY]

THE BIGGEST EPIDERMAL VULVAR CYST WITH VITILIGO LESIONS FOLLOWING FEMALE GENITAL MUTILATION

İlkin Zindancı¹, Melike Kibar Öztürk¹, Ebru Zemheri², Cumhuri Çakır³

¹Department of Dermatology, Umraniye Training and Research Hospital, Istanbul, Turkey

²Department of Pathology, Umraniye Training and Research Hospital, Istanbul, Turkey

³Department of General surgery, Gebze Hospital, Kocaeli, Turkey

BACKGROUND: Epidermoid vulvar cystic lesions are proliferations of epidermal cells that may occur as a complication of female genital mutilation (FGM) that is still a very common practice in many cultures, especially in Africa.

AIM: Our aim is presenting a long-term complication of FGM.

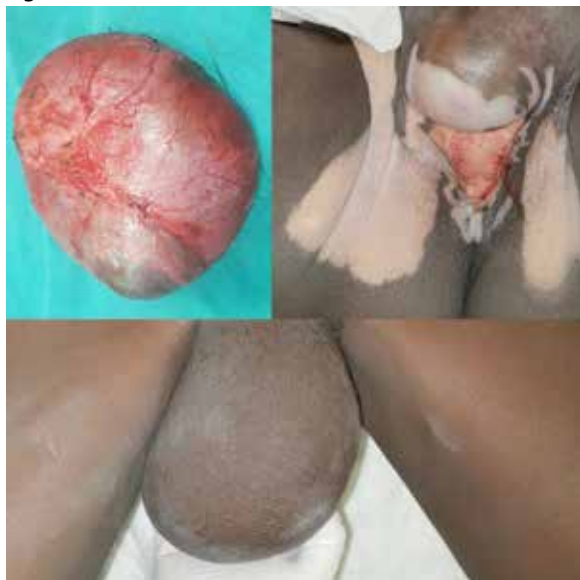METHODS: A 36-year-old Sudanese woman presented with an enlarged clitoral mass for 2 years. In her medical history, she had FGM at the age 3. Perineal examination revealed a mobile, nontender, rounded cystic swelling with vitiligo lesions.

RESULTS: We excised the cyst, the mass revealed a 13x11x11 cm sized unilocular round mass. On microscopy, epidermoid cyst was reported. Follow-up of the patient 6 months later revealed a good result, with no recurrence.

CONCLUSIONS: We reported a woman with a clitoral epidermal cyst accompanied with vitiligo lesions. To date, this is the largest and the first epidermoid cyst with vitiligo lesions following FGM reported in the literature.

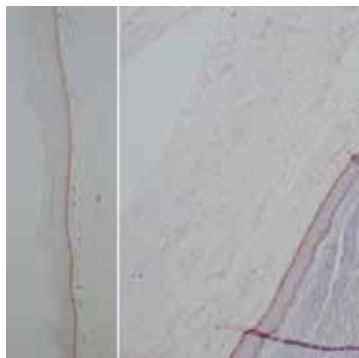
Keywords: epidermoid vulvar cyst, female genital mutilation, epidermal cyst

Figure 1



Clinical and postoperative picture of giant epidermoid cyst with vitiligo lesions.

Figure 2



Histopathological appearance of the epidermoid cyst lined by an epidermis-like epithelium including a granular cell layer and filled with laminated keratin.



3rd INDERCOS

National Dermatology & Cosmetology Congress with International Participants

14-17 MARCH, 2018
HILTON ISTANBUL BOSPHORUS HOTEL
ISTANBUL, TURKEY

PP-022

[PAEDIATRIC DERMATOLOGY]

A CASE OF PURPURIC PITYRIASIS ROSEA RESEMBLING HENOC SCHONLEIN PURPURA

Burçin Cansu Bozca¹, Cansu Büyükdeğirmenci², Betül Ünal³, Erkan Alpsoy¹

¹Department of Dermatology and Venerology, Akdeniz University, Antalya, Turkey

²Department of Pediatrics, Akdeniz University, Antalya, Turkey

³Department of Pathology, Akdeniz University, Antalya, Turkey

INTRODUCTION: Atypical pityriasis rosea is used to define cases presenting with atypical morphology or distribution of lesions. They can be challenging to diagnose. Purpuric PR (PPR) is a rare, atypical PR presenting with multiple, small, purpuric or hemorrhagic macules on the trunk and extremities. In addition to classic lesions, localized purpuric lesions may also be seen. So far, less than 20 cases have been reported in English literature. We present here a new case of PPR that began with localized purpuric lesions on the lower limbs and then spread to the trunk and upper limbs.

MATERIAL-METHODS: A 16-year-old male patient presented with an itchy rash that had started on the back of the foot and spread to the trunk and arms within 1 week. Before the onset of the rash there was no upper respiratory tract infection or drug use. At first admission to pediatrics, physical examination revealed symmetrically distributed purpuric macules and papules on the dorsum of the foot and anterior tibia. The patient was scheduled for skin biopsy with a preliminary diagnosis of Henoch-Schönlein Purpura. Hemogram, routine biochemical and coagulation tests were within normal limits. When the patient applied to our clinic, the petechial and purpuric lesions spread to the torso and purpuric lesions formed Christmas tree pattern on the back. Herald patch was seen under the right axillary region which was oval in shape with a dimension of 4 × 3 cm. Skin biopsy was taken from purpuric lesions located on his back and left ankle.

RESULTS: Histopathological examination revealed hyperkeratosis, mild acanthosis, epidermal spongiosis, perivascular lymphocytic infiltration, few eosinophils, lymphocytic exocytosis and erythrocyte extravasation. Direct immunofluorescence test was negative. Diagnosis was established as PPR with correlation of clinical and histological findings. Due to severe itching and widespread distribution of lesions, narrow band UVB was started, and the patient responded to treatment within 2 weeks.

CONCLUSION: Although etiology is unknown, upper respiratory tract infections, viral infections, drugs and autoimmunity are suggested causes. Association of PPR with acute myeloid leukemia has also been reported. Clinical course of PPR is that of typical PR. The typical lesions of PPR are in "Christmas tree" appearance and are mostly located on the trunk. In our case, interestingly, lesions started from the lower extremities and resembled Henoch-Schönlein Purpura at the beginning. Treatment of PPR is similar to the typical form. It is usually a self-limited disease and responds to treatment well. Narrow band UVB can be tried in chronic and resistant cases as in our case. In conclusion, we report this case because of its rarity in dermatological literature and its unusual presentation and severity.

Keywords: Pityriasis rosea, purpuric, narrow band UVB, Henoch Schonlein purpura

3rd INDERCOS

National Dermatology & Cosmetology Congress with International Participants

14-17 MARCH, 2018
HILTON ISTANBUL BOSPHORUS HOTEL
ISTANBUL, TURKEY



PP-023

[ALLERGOLOGY AND IMMUNOLOGY]

HEMORRHAGIC BULLAE DUE TO VIPERA BITE

Meltem Hüdaverdi, Şenay Ağırçöl, Ceyda Çaytemel, Zafer Türkoğlu
Dermatology Clinic, Haseki Training and Research Hospital, Istanbul, Turkey

INTRODUCTION & OBJECTIVES: Snake venom poisoning is a medical emergency that requires fast treatment. Toxic snake bite can cause partial tissue damage and systemic symptoms. Commonly, bite marks, pain, swelling, ecchymosis, and systemic respiratory-cardiac symptoms occur. Main complications are thrombophlebitis, local hemorrhagic bulla formation, bleeding from skin, rhabdomyolysis, reduced sensation, acute renal failure, necrosis with tissue loss, digit amputation, carpal tunnel syndrome, and compartment syndrome. Here we present a case of hemorrhagic bullae after being infested by a vipera.

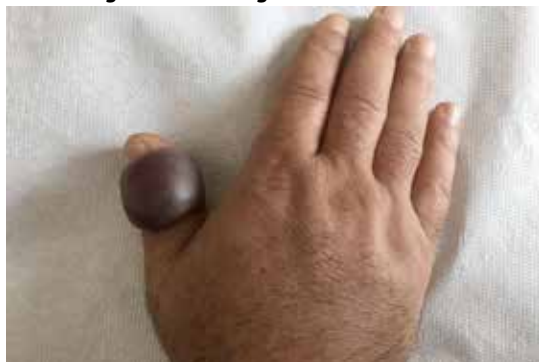MATERIALS & METHODS: A 53-year-old male patient presented to our emergency department with hemorrhagic bullae on his right thumb. He was bitten by the viper snake in the Aegean region 2 days ago and the antiserum was applied in the nearby hospital and was referred to our tertiary hospital for possible systemic findings. The hemorrhagic bullae drained away and cultured.

RESULTS: Blood tests revealed no anomaly except mild high level (CK: 335 (<171)). The patient had no cardiac, respiratory, or systemic findings. The culture revealed no organisms. Antibiotics and epithelial creams were given for wound care. The CK value of the patient was in decreasing trend. The lesion on the patient's finger improved without scar.

CONCLUSIONS: Vipera is a kind of poisonous snake. Locally, it can cause tissue necrosis and produce hemorrhagic bullae. Local and systemic side effects should be closely monitored.

Keywords: hemorrhagic bullae, vipera, snake bite

Hemorrhagic Bullae On Right Thumb





3rd INDERCOS

National Dermatology & Cosmetology Congress with International Participants

14-17 MARCH, 2018
HILTON ISTANBUL BOSPHORUS HOTEL
ISTANBUL, TURKEY

PP-024

[MISCELLANEOUS]

PSEUDOEPITHELIOMATOUS HYPERPLASIA - A RARE TATTOO REACTION RELATED WITH RED PIGMENT

Tugba Falay Gur¹, Sevim Baysak¹, Neslihan Kaya Terzi², Cüneyt Kara¹, Mustafa Akaryıldız¹, Bilal Doğan¹

¹Department of Dermatology, Health Science University, Sultan Abdulhamid Han Training and Research Hospital, Istanbul, Turkey

²Department of Pathology, Health Science University, Sultan Abdulhamid Han Training and Research Hospital, Istanbul, Turkey

Tattooing is become popular recently and the side effects of tattoo are frequently started to see. The widespreading cutaneous adverse effects against to red tattoo ink are reported on nowadays. The red color is the most common reason for delayed tattoo reaction. It is well-known that the mercury sulphate in red tattoo is caused to allergic reactions. Lichenoid reaction is the most common immune reaction against to tattoo; however granulomatous, sarcoidal reaction, pseudolymphoma, vasculitis and morphea are also seen. The pseudoepitheliomatous hyperplasia is also added to these reactions recently. A 33-year-old female patient applied with itchy puffiness on her tattoo which was done a year ago. These swellings have been begun to occur in 2nd month after tattoo done. The keratotic, verrucous, infiltrating papules and plaque lesion on the red pigmentary areas of left forearm were seen on the dermatological examination (Figure 1). Histopathological examination of two punch biopsies taken from the papule and plaque showed irregular prominent acanthosis with parakeratosis in epidermis; perivascular and perifollicular intense lymphocyte and plasmocyte infiltration in dermis. The lymphoid cells were positive for CD3 and CD20 and the Ki-67 index was 5-10 %. Periodic acid-Schiff staining and culture were negative. These findings were suggested pseudoepitheliomatous hyperplasia accompanied by lymphoid hyperplasia. The patient has been followed up with monthly intralesional steroid treatment. Pseudoepitheliomatous hyperplasia is a reactive skin reaction pattern that seen hyperkeratotic plaques. Its histopathology is characterised by acanthosis in epidermal and follicular infundibulum in the absence of atypia. It has been suggested that they may be hypertrophic lichen planus-like reactions due to pseudoepitheliomatous hyperplasia is accompanied by lichenoid reaction in defined cases. It could be clinically reminded of cutaneous neoplasms such as keratocanthomas, squamous cell carcinomas due to marked epidermal proliferation. Therefore, the histopathologic examination is the main diagnostic tool. The pseudoepitheliomatous hyperplasia is tattoo reaction whose treatment is really hard. The topical, intralesional steroid, surgery and carbondioxide laser treatment are among options. However, it is a new entity and the number of reported cases is low, the existing data is insufficient.

Keywords: pseudoepitheliomatous hyperplasia, tattoo, tattoo reaction

3rd INDERCOS

National Dermatology & Cosmetology Congress with International Participants

14-17 MARCH, 2018
HILTON ISTANBUL BOSPHORUS HOTEL
ISTANBUL, TURKEY



Figure 1





3rd INDERCOS

National Dermatology & Cosmetology Congress with International Participants

14-17 MARCH, 2018
HILTON ISTANBUL BOSPHORUS HOTEL
ISTANBUL, TURKEY

PP-025

[INFLAMMATORY SKIN DISEASES]

SERUM THIOL-DISULPHIDE HOMEOSTASIS IN PATIENTS WITH SEBORRHEIC DERMATITIS AND RELATIONSHIP WITH DISEASE SEVERITY

Selma Emre¹, Gökür Kalkan¹, Serpil Erdoğan², Akın Aktaş¹, Merve Ergin²

¹Department of Dermatology, Yıldırım Beyazıt University, Ankara, Turkey

²Department of Biochemistry, Yıldırım Beyazıt University, Ankara, Turkey

INTRODUCTION & OBJECTIVES: Seborrheic dermatitis is a chronic, inflammatory and multifactorial skin disease in which many endogenous and exogenous factors play a role. Recent studies have shown that oxidative stress increased in patients with SD. The dynamic thiol / disulfide balance is one of the most important components of oxidative stress. In this study, we aimed to investigate the relationship between dynamic thiol / disulfide balance and disease severity in SD patients.

MATERIALS & METHODS: Seventy seborrheic dermatitis patients and 67 healthy volunteers as control group were included in the study. Thiol / disulfide parameters were measured from venous blood samples taken from the patient and control group. Thiol / Disulphide Homeostasis tests were performed by automated spectrophotometric method. Severity of disease was calculated using seborrheic dermatitis area severity index. The thiol / disulfide balance was compared between the patient and control group. In addition, disease severity and other demographic characteristics of patients and thiol / disulfide balance parameters were compared.

RESULTS: Of the 70 patients included in the study, 47 were male and 23 were female. Thirty four of the healthy controls were male, 27 were female. Native thiol and total thiol were significantly higher in the patient group than the healthy volunteers. Disulfide levels were slightly lower in the patient group. However, the difference was not statistically significant. When the correlation between thiol / disulfide balance and patient characteristics was compared, there was a negative correlation between the age of the patients and the native thiol and total thiol.

CONCLUSION: In the active phase of seborrheic dermatitis, thiol groups are higher in patient sera than healthy individuals. Increased thiols in the serum may be responsible for increased proliferation of seborrheic dermatitis lesions.

Keywords: seborrheic dermatitis, thiol, disulphide

3rd INDERCOS

National Dermatology & Cosmetology Congress with International Participants

14-17 MARCH, 2018
HILTON ISTANBUL BOSPHORUS HOTEL
ISTANBUL, TURKEY



Table 2. Correlation of the thiol/disulfide homeostasis and basic features of the patients.

	Native thiol	Total thiol	Disulp-hide	Disulp-hide / Native thiol	Disulp-hide / Total thiol	ative thiol / Total thiol
Age	r: -0.440 p: <0.001	r: -0.464 p: <0.001	r: -0.094 p: 0.438	r: -0.019 p: 0.877	r: -0.019 p: 0.877	r: 0.023 p: 0.852
Duration	r: 0.012 p: 0.920	r: 0.008 p: 0.945	r: -0.044 p: 0.720	r: -0.045 p: 0.711	r: -0.045 p: 0.711	r: 0.052 p: 0.669
Starting age	r: -0.421 p: <0.001	r: -0.452 p: <0.001	r: -0.094 p: 0.441	r: -0.019 p: 0.876	r: -0.019 p: 0.876	r: 0.021 p: 0.860
SDASI	r: -0.061 p: 0.618	r: -0.119 p: 0.326	r: -0.130 p: 0.285	r: -0.128 p: 0.291	r: -0.128 p: 0.291	r: 0.129 p: 0.286

SDASI: Seborrheic dermatitis area severity index

Table 1. Comparison of the patients and control groups.

	Patients group (n=70)	Control group (n=61)	p
Gender			
Male	47 (%67.1)	34 (%55.7)	
Female	23 (%32.9)	27 (%44.3)	0.180
Age (Year) (Median, IQR)	29.5 (17)	32 (22)	0.083
Native thiol (mean±SD)	504.17±50.97	468.37±52.01	<0.001
Total thiol (mean±SD)	543.74±53.43	508.62±54.50	<0.001
Disulfid (mean±SD)	19.75±9.14	20.09±7.82	0.821
Disulfide/Native (mean±SD)	3.96±1.85	4.34±1.77	0.231
Disulfide/Total (mean±SD)	3.62±1.59	3.95±1.51	0.227
Native/Total (mean±SD)	92.76±3.18	92.10±3.07	0.230



3rd INDERCOS

National Dermatology & Cosmetology Congress with International Participants

14-17 MARCH, 2018
HILTON ISTANBUL BOSPHORUS HOTEL
ISTANBUL, TURKEY

PP-026

[INFLAMMATORY SKIN DISEASES]

CASE REPORT: FOLLICULITIS DECALVANS CAPILLITI WITH SCARRING ALOPECIA

Diana Muja¹, Migena Gega²

¹Polyclinic of specialties no 2, Tirana, Albania

²Skin tech clinic, Tirana, Albania

INTRODUCTION: Folliculitis Decalvans (FD) is a rare neutrophilic inflammation of the scalp characterized by painful, recurrent purulent follicular exudation resulting in primary cicatricial alopecia. Unclear etiology makes FD treatment a difficult task. A wide variety of topical and systemic agents including antimicrobials, antifungals, retinoids, corticosteroids, as well as laser depilation treatment have been tried previously, with varied results. We present here a case report of a patient with FD resulting in severe cicatricial alopecia under a long treatment with poor improvement.

MATERIALS AND METHODS: A 43-year-old female presented with multiple erythematous papules and pustules over her scalp for five years. There was subsequent scarring alopecia in the affected areas. On examination, there were multiple red papules and pustules over the parietal and occipital region of her scalp. Patchy hair loss with scar formation was seen. No anomaly was found over her axillae and groins. An incisional biopsy of the scalp was performed which showed neutrophilic infiltration in the follicular lumina, ruptured follicles and dermal fibrosis. The patient was treated with multiple topical antiseptics and systemic antibiotics such as tetracycline, doxycycline and erythromycin without satisfactory improvement. Finally, isotretinoin was prescribed at the initial dose of 20 mg per day, which was later increased to 30 mg per day. Her scalp improved with marked decrease in erythematous papules and pustules with remaining atrophic bald areas.

DISCUSSION: FD was defined as circumscribed coalescing inflammation of hair follicles with pustulation leading to crusting, atrophy and scarring alopecia. It affects both sexes equally from young adulthood to middle age. The exact aetiology of FD is unknown. FD does not have specific histological finding. In advanced lesions, scarring and fibrosis with destruction of hair follicles are left. FD usually presents as recurrent follicular pustules with subsequent irregular areas of patchy scarring alopecia on any part of the scalp although other hair bearing regions may be affected. Possible complications include scarring alopecia, abscess, and cellulitis. Treatment of FD is difficult. Multiple combination of topical and systemic antibiotics such as fusidic acid, rifampicin and clindamycin are reported. Our patient failed to respond to topical and systemic antibiotics plus topical antiseptics but responded poorly to isotretinoin therapy at the dose of 30 mg per day. However, it is a big challenge to treat Folliculitis Decalvans Capilliti.

Keywords: folliculitis, alopecia, isotretinoin therapy

3rd INDERCOS

National Dermatology & Cosmetology Congress with International Participants

14-17 MARCH, 2018
HILTON ISTANBUL BOSPHORUS HOTEL
ISTANBUL, TURKEY



PP-027

[ACNE AND RELATED DISORDERS, HIDRADENITIS SUPPURATIVA] ACNEIFORM DRUG ERUPTION DURING LUNG CANCER TREATMENT WITH ERLOTINIB

Ilkin Zindancı¹, Melike Kibar Öztürk¹, Ebru Zemheri²

¹Department of Dermatology, Umraniye Training and Research Hospital, Istanbul, Turkey

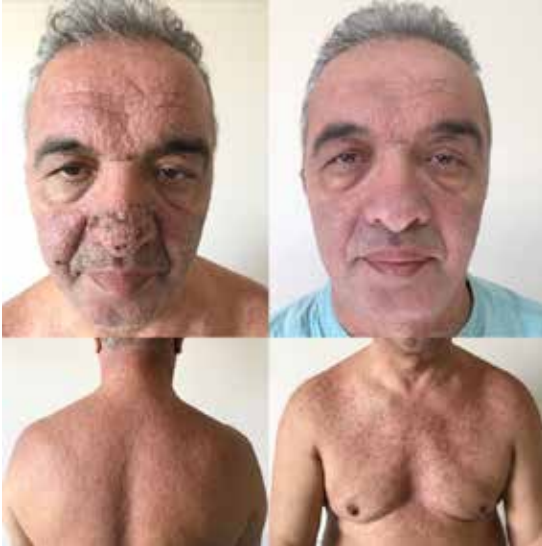²Department of Pathology, Umraniye Training and Research Hospital, Istanbul, Turkey

INTRODUCTION: Tyrosine kinase inhibitors (epidermal growth factor receptor inhibitors) are currently applied in the treatment of non-small cell lung cancer. Acneiform drug eruption is the most characteristic side effect of EGFR inhibitors. We report a case of a 52-year-old patient who developed acneiform rash after 2 weeks of treatment with erlotinib.

CASE : Patient aged 52 years was referred for dermatological consultation from the Oncology Chemotherapy Department in September 2017 because of the lesions in the form of follicular pustules, papules and crusts particularly extensive in the seborrhoeic areas, located on the skin of the face and trunk. No blackheads were found and the lesions were accompanied by itching (figure 1). Six months earlier the patient was diagnosed with non-small cell lung cancer and the patient had underwent therapy with erlotinib (Tarceva®) at 150 mg/day. After two weeks of that treatment, the lesions occurred. In the past the patient he had no history of acne. We assessed the patient according to Naranjo adverse drug reaction probability scale, total score was 9 with a definite result. Histopathological evaluation was convenient with acneiform drug eruption. We saw yellow dots and irregular shaped purple-black areas on the erythematous area with the dermatoscopy of the lesions (figure 2). Following the consultation, the general treatment with doxycycline 100 mg 2x1 capsules was applied and gel with clindamycin and benzoyl peroxide was recommended. Within 2 weeks a significant improvement and partial regression of skin lesions was recorded. The patient did not require the erlotinib dose reduction.

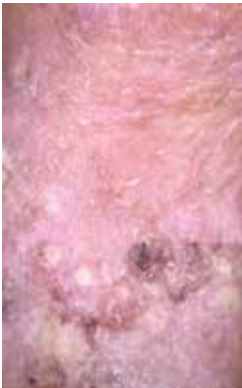Keywords: acneiform drug eruption, acneiform rash, erlotinib, tyrosine kinase inhibitors.

Figure 1



Clinical pictures of the lesions; follicular pustules, papules and crusts particularly extensive in the seborrhoeic areas, located on the skin of the face and trunk (before and after treatment)

Figure 2



Dermatoscopy of the lesions on face: Yellow dots and irregular shaped purple-black areas on the erythematous area

3rd INDERCOS

National Dermatology & Cosmetology Congress with International Participants

14-17 MARCH, 2018
HILTON ISTANBUL BOSPHORUS HOTEL
ISTANBUL, TURKEY



PP-028

[ADVERSE DRUG REACTIONS, TEN]

NICOLAU SYNDROME DUE TO DICLOFENAC INJECTION

Emin Ozlu, Yunus Ozcan

Duzce University School of Medicine, Department of Dermatology, Duzce, Turkey

INTRODUCTION: Nicolau syndrome is an ulcerated and necrotic skin disease usually occurring at the intramuscular injection site. It is a rare and iatrogenic disease with unclear pathogenesis. Current theories suggests that the development of vascular damage and contraction with perivascular inflammation after the injection. There is no standart treatment for the disease.

CASE REPORTS: An 42-year-old man was admitted to our clinic with a painful necrotic ulcer in the left gluteal region. His medical history, which was non-specific except for back pain, revealed an intramuscular diclofenac injection two months before. Dermatological examination revealed a painful ulcerous plaque with a black necrotic crest in the lateral part of the left gluteal region. This ulcerous plaque appeared indurated and erythematous in its surrounding. The patient was diagnosed with Nicolau syndrome based on his medical history and clinical symptoms. The patient was referred to the Department of Plastic Surgery for the debridement of the necrotic tissue. After surgical debridement by the plastic surgeon the ulcer lesion was completely regressed.

CONCLUSION: This case was reported due to being a rare diagnosis and it's important to remember that with simple measures, it is possible to prevent it. It should be kept in mind that Nicolau syndrome could develop following the use of intramuscular diclofenac.

Keywords: Nicolau syndrome, side effect, diclofenac.



3rd INDERCOS

National Dermatology & Cosmetology Congress with International Participants

14-17 MARCH, 2018
HILTON ISTANBUL BOSPHORUS HOTEL
ISTANBUL, TURKEY

PP-029

[DERMATOLOGY AND INTERNAL MEDICINE, INCLUDING SKIN MANIFESTATIONS OF SYSTEMIC DISEASES]

A CASE OF SUPERIOR VENA CAVA SYNDROME DIAGNOSED ANGIOEDEMA

Gülcan Saylam Kurtipek, Abdullah Demirbaş, Gözde Ulutaş Demirbaş, Fatma Tunçez Akyürek
Department of Dermatology Selcuk University, Konya, Turkey

Superior vena cava syndrome (SVCS) is obstruction of blood flow through the superior vena cava (SVC). It is a medical emergency and most often manifests in patients with a malignant disease process within the thorax. Lung cancer, particularly adenocarcinoma, is now the underlying process in approximately 70% of patients with SVCS. Obstruction of the SVC may be caused by neoplastic invasion of the venous wall associated with intravascular thrombosis or, more simply, by extrinsic pressure of a tumor mass against the relatively thin-walled SVC. A 30-year-old female patient was admitted to the otorhinolaryngology department with a complaint of sore throat about 15 days ago. Antibiotic treatment was given with tonsillitis diagnosis. Three days after the treatment; swelling of the right eyelid, face and neck region, the veins around the right eyelid, neck and anterior chest were became evident. Also, complaints of shortness of breath were showed up. With these complaints, systemic steroid treatment was given twice at the emergency policlinic with the diagnosis of angioneurotic edema caused from medicine. However, despite these treatments, the patient was applied to our polyclinic because of complaints continued. The patient's resume and family history did not have a distinct feature. Ultrasonography of the neck showed jugular venous thrombosis. Pulmonary CT angiography requested from the patient. CT angiography revealed an irregular mass lesion on the anterior mediastinum with right main pulmonary artery, vena cava superior and right lung parenchyma invasive appearance approximately 7x6 cm in size. A biopsy was taken by a thoracic surgery clinic considering lung cancer at the pre-diagnosis.

Keywords: Angioedema, venous thrombosis, Superior vena cava syndrome

3rd INDERCOS

National Dermatology & Cosmetology Congress with International Participants

14-17 MARCH, 2018
HILTON ISTANBUL BOSPHORUS HOTEL
ISTANBUL, TURKEY



PP-030

[CUTANEOUS ONCOLOGY]

DERMATOFIBROSARCOMA PROTUBERANS: A CASE REPORT

Nazlı Caf, Senay Ağirgöl, Nazan Aksoy, Zafer Turkoglu, Mehmet Yunus Meydan
Dermatology, Haseki Training and Research Hospital,

OBJECTIVE: Dermatofibrosarcoma Protuberans (DFSP) is rare among soft tissue neoplasms. It is fibroblast-derived low grade sarcoma; usually arises in 20-40 of ages but also reported in childhood and elderly ages. Metastasis is not common but it is locally aggressive. A patient with late onset DFSP will be presented in this case report.

MATERIAL-METHOD: 75 year old female with swelling and itch on her back was consulted. The complaints were present for 2 years. In mid-back, 3*2 cm sized, plaque was observed with smooth, mild atrophy in the center and nodular formation was present at the borders. Otherwise, the patient had no medical history.

RESULTS: Histopathologically deep dermis was infiltrated with spindle cells. In immunohistochemical stains CD 34 was positive while FXIIIa, S-100 and SMA were negative. Blood tests showed no abnormality except normochromic normocytic anemia. According to this results, the patient was diagnosed as DFSP.

CONCLUSION: Dermatofibrosarcoma Protuberans disease show intermediate-to low-grade malignancy. The clinicians should consider this diagnosis when the patients have keloid-like lesions and further investigations need to be performed.

Keywords: dermatofibroma protuberans, late-onset,



3rd INDERCOS

National Dermatology & Cosmetology Congress with International Participants

14-17 MARCH, 2018
HILTON ISTANBUL BOSPHORUS HOTEL
ISTANBUL, TURKEY

PP-031

[AUTOIMMUNE BULLOUS DISEASES] TREATMENT-RESISTANT CASE OF PEMPHIGUS NODULARIS

Ceren Buğlem Elgörmüş, Rafet Koca, Nilgün Tekin
Department of Dermatology, Bulent Ecevit University, Zonguldak, Turkey

Nodular pemphigoid is a rare variant of bullous pemphigoid showing clinical features mimicking prurigo nodularis, although blisters may also be seen. This disease is seen mostly in middle-aged women, and characterized by itchy, purple, vesicles, papules and plaques which are settled symmetrically on the distal extremities. Many treatments are being tried such as cyclophosphamide, fexofenadine, montelukast, and sulfamethoxypyridazine but it is known that patient have the most benefit from systemic steroids, dapson and azathioprine treatments.; A forty-nine years old woman presented to our clinic with itchy redness on her legs. She had taken various treatments with these complaints for 3 years. Physical examination showed widespread, erythematous, purple-pink, hypertrophic papules on the body that were located in the distal part of the extremities. Histologic examination (also immunofluorescence staining) of a biopsy specimen taken from the lesion was consistent with nodular pemphigoid. For treatment, we started systemic steroid and azathioprine combination therapy. This treatment provided a satisfactory clinical response, but recurrence was seen while cutting of systemic steroid therapy by reducing the dose. After the recurrence of the disease, we also added 100 mg/day dapson to the treatment. After addition of dapson therapy the lesion began to regression. Three months after initiation of the combination treatment, recurrences of the lesions were seen on legs. In this presentation, we wanted to share the difficulty of the diagnosis and treatment of nodular pemphigoid.

Keywords: Nodular pemphigoid, treatment, corticosteroid, azathioprine, dapson



PP-032

[INFLAMMATORY SKIN DISEASES]

PERIORIFICAL GRANULOMATOUS DERMATITIS COEXISTING COELIAC DISEASE

Gülcan Saylam Kurtipek, Fatma Tunçez Akyürek

Department of Dermatology, Selcuk University, Konya, Turkey

Granulomatous periorifical dermatitis (GPD) can resemble granulomatous rosacea and sarcoidosis. The characteristic features are flesh-colored, pink, and yellow papules around the mouth, nose, and eyes. The microscopic appearance of GPD can be same as granulomatous rosacea, showing a superficial and deep dermal, noncaseating granulomatous infiltrate with macrophages and lymphocytes around hair follicles.

A 34-year-old female patient presented with periorifical papules on the face, that erupted during a summer, where she was diagnosed with sarcoidosis after a biopsy of one of the papules (Figure 1). Detailed screening there was no finding in respect of sarcoidosis just as bilateral hilar lymphadenopathies, increased serum ACE levels. She was diagnosed as periorifical granulomatous dermatitis. The patient had been examined owing to diarrhea complaints, had been detected coeliac disease by department of gastroenterology. Gluten free diet has been suggested for complaints. The 15 mg/week methothrexate treatment had been started for skin lesions. After one month starting treatment, skin lesions completely disappeared. There was no recurrence in monthly controls (Figure 2).

Keywords: granulomatous, periorifical, coeliac disease

Figure 1

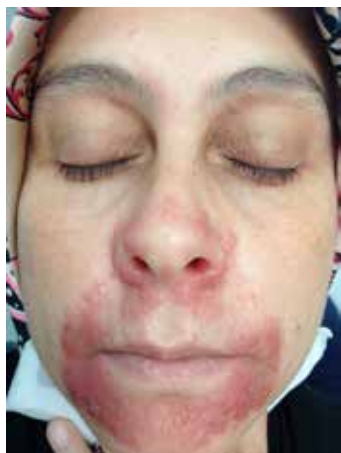
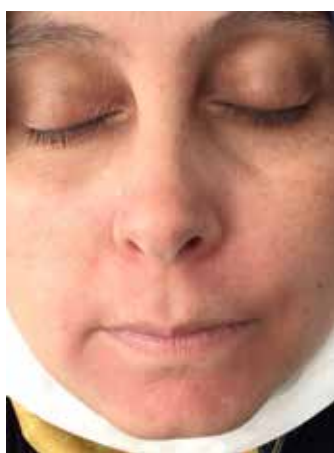
Figure 2





3rd INDERCOS

National Dermatology & Cosmetology Congress with International Participants

14-17 MARCH, 2018
HILTON ISTANBUL BOSPHORUS HOTEL
ISTANBUL, TURKEY

PP-033

[HAIR DISORDERS/DISEASES]

ALOPECIA UNIVERSALIS CONGENITA: A CASE REPORT

Zennure Takci¹, Sahin Takci², Havva Yıldız Seçkin¹, Atiye Oğrum¹

¹Department of Dermatology, Faculty of Medicine, Gaziosmanpasa University, Tokat, Turkey

²Department of Pediatrics, Faculty of Medicine, Gaziosmanpasa University, Tokat, Turkey

INTRODUCTION: Alopecia universalis congenita (AUC) is a rare disorder of skin characterized by generalized absence of hair at or shortly after birth. It has variable inheritance pattern and, the autosomal recessive form is the most common and severe phenotype. AUC occurs either in isolation or as a part of congenital syndromes. Here, we report the case of a 4-month-old male infant who presented with AUC in isolation with family history.

CASE: A-4 months old male baby, presented with a history of total absence of scalp and body hair since birth (Figure 1). He was born of nonconsanguineous marriage, by a normal vaginal delivery after normal pregnancy at full term to a primigravida without fetal anomalies, such as cleft palate, polydactyl, ear or eye abnormalities, skeletal malformations and ectodermal abnormalities like nail dystrophy. The patient had no exposure to medications in utero and was healthy. There was a family history of the disease that affected mother, maternal aunt and maternal grandmother. His mother reported that she had 8 siblings (2 females, 6 males, 7 of them do not have the history of disease) and she and her sister were born with a history of total absence of scalp and body hair and then their hair started to come in adolescence. Now they have sparse scalp hair and eyebrows and they never had eyelashes (Figure 2). All blood work revealed normal findings, including thyroid and adrenal function. His progress was monitored without any therapeutic intervention during the following nine months and still under follow-up. On the control examination at the age of one, 3 hair pieces were seen on the scalp and he was normal in well-child visit.

DISCUSSION: Alopecia which presents since birth may include several types of hereditary hair loss disorders in human beings. AUC has variable inheritance pattern and, the autosomal recessive form is the most common and severe phenotype. AUC occurs either in isolation or as a part of congenital syndromes. We report a rare case of AUC with alopecia universalis congenita with family history.

Keywords: Alopecia universalis, congenital, family history

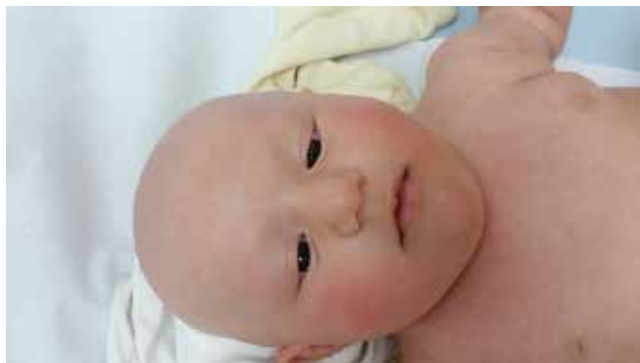3rd INDERCOS

National Dermatology & Cosmetology Congress with International Participants

14-17 MARCH, 2018
HILTON ISTANBUL BOSPHORUS HOTEL
ISTANBUL, TURKEY

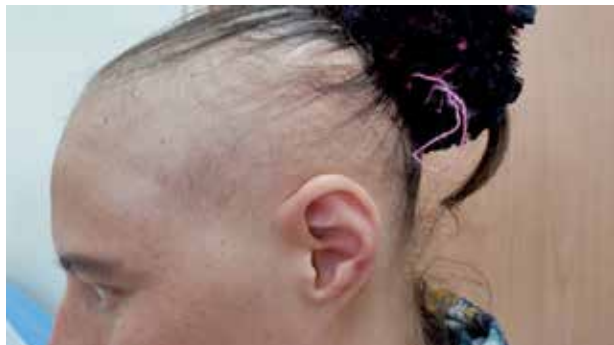

Figure 1



Alopecia universalis in a baby

Figure 2



The mother with ophiasic alopecia, sparse eyebrows and no eyelashes



PP-034

[URTICARIA, ANGIOEDEMA]

THE CLINICAL RESPONSE TO OMALIZUMAB IN CSU PATIENTS IS LINKED TO AND PREDICTED BY CHANGES OF IGE LEVELS IN RESPONSE TO TREATMENT

Ragıp Ertas¹, Kemal Özyurt¹, Mustafa Atasoy¹, Tomasz Hawro², Marcus Maurer²

¹Health Sciences University, Kayseri Education and Research Hospital Dermatology Clinic, Kayseri, Turkey

²Department of Dermatology and Allergy, Charité - Universitätsmedizin Berlin, Germany

BACKGROUND: Omalizumab is an effective and well-tolerated treatment option for patients with chronic spontaneous urticaria (CSU). Markers and predictors of the response are largely unknown, but needed to optimize omalizumab treatment. IgE is the target of omalizumab, and IgE levels may predict the effects of treatment.

OBJECTIVES: We aimed to evaluate if response rates to treatment with omalizumab in patients with CSU are linked to their baseline IgE levels, their IgE levels after omalizumab treatment, and the ratio of on treatment IgE and baseline IgE levels.

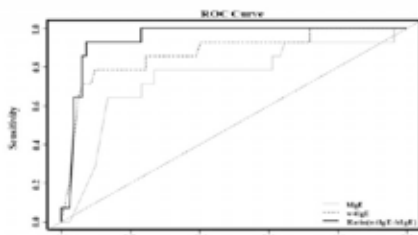
METHODS: One hundred and thirteen CSU patients were treated with omalizumab 300 mg/4weeks for 12 weeks, when their treatment responses, i.e. no response, partial response, complete response, were assessed by use of the urticaria activity score (UAS), physician and patients visual analog scale (VAS), treatment effectiveness score (TES) and investigator's global clinical impression (IGCI). Total IgE levels were measured before treatment (blgE) with omalizumab and 4 weeks thereafter (w4IgE).

RESULTS: Non-responders to omalizumab had significantly lower blgE levels (17.9 IU/ml, 17.0-55.0 IU/ml, $p=0.010$) than in the partial responders (82.0 IU/ml, 46.2-126.5 IU/ml, $p=0.008$) and the complete responders (73.7 IU/ml, 19.45-153.8 IU/ml, $p=0.032$). Non-responders also had lower total w4IgE levels and lower ratios of w4IgE/blgE levels than partial and complete responders ($p<0.001$). Non-response to omalizumab was best predicted by patients' w4IgE/blgE ratios, which had a significantly higher area under the curve than blgE ($p=0.016$) (Figure 1).

CONCLUSIONS: In CSU, total IgE levels predict the response to treatment with omalizumab. The assessment of pre-treatment, post-treatment and calculating ratio of post-treatment/pre-treatment total IgE levels may help to improve the management of CSU in patients who require omalizumab treatment.

Keywords: Chronic spontaneous urticaria, Baseline IgE, Post-treatment IgE, Omalizumab, Response

Figure 1



Analysis of ROC curves for prediction of response to omalizumab revealed that the w4IgE:blgE ratio shows the best predictive properties.

3rd INDERCOS

National Dermatology & Cosmetology Congress with International Participants

14-17 MARCH, 2018
HILTON ISTANBUL BOSPHORUS HOTEL
ISTANBUL, TURKEY



PP-035

[URTICARIA, ANGIOEDEMA]

REFRACTORY URTICARIAL VASCULITIS TO RESPONSIVE METHOTREXATE

Selami Aykut Temiz¹, Arzu Ataseven¹, Ilkay Özer¹, Recep Dursun¹, Siddika Findik²

¹Department of Dermatology, Necmettin Erbakan University Meram Faculty of Medicine, Konya, Turkey

²Department of Pathology, Necmettin Erbakan University Meram Faculty of Medicine, Konya, Turkey

Urticarial vasculitis is a chronic clinicopathologic entity characterized by clinically characterized urticarial rash, histopathologically characterized by leukocytoclastic vasculitis. About 5% to 10% of patients with urticarial lesions have urticarial vasculitis. Pathogenesis is thought to be developed by a type 3 hypersensitivity reaction similar to leukocytoclastic vasculitis.

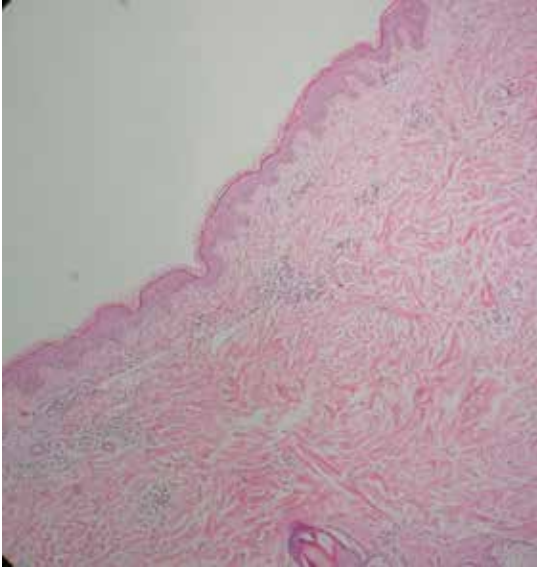
A 31-year-old woman presented with a complaint of urticaria for three months. Dermatologic examination revealed common urticarial plaques in the body, no angioedema. There was no medical illness other than hashimoto thyroiditis in her medical history.

Skin biopsy was taken from urticarial plaques of the patient for differential diagnosis. Preliminary diagnoses of biopsy were urticaria and urticarial vasculitis. Histopathological examination showed mononuclear inflammatory infiltration in the papillary dermis with a swollen anterior fibrinoid necrosis perivascular area eosinophils in endothelium, as a result it was compatible with vasculitis. Our case was resistant to the classic treatments (systemic antihistamine, systemic steroid, cyclosporine, omalizumab) that we tried. We decided to add methotrexate therapy to patients who did not remedy symptoms with systemic steroid therapy. Complaints of the patient retreated in the second week. Symptoms of the patient has not repeat for five months with methotrexate therapy.

In our case, we had a response to treatment with methotrexate, symptoms were not respond on antihistamine, steroid, cyclosporine and omalizumab previously. This case report recommends that methotrexate therapy may be a treatment option for resistant urticarial vasculitis.

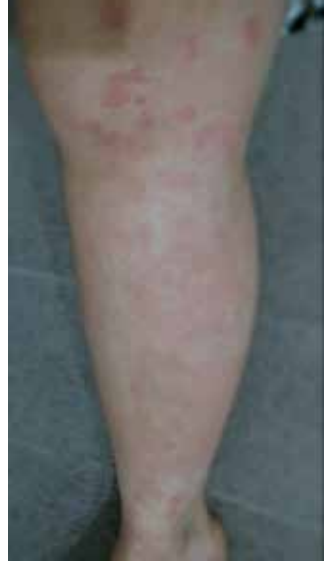Keywords: Urticarial vasculitis, omalizumab, methotrexate

Figure 1



Mononuclear inflammatory infiltration in the papillary dermis with a swollen anterior fibrinoid necrosis perivascular area eosinophils in endothelium. H&EX40

Figure 2



Common urticarial plaques

PP-036

[WOUNDS, CHRONIC WOUNDS, WOUND HEALING, ULCER]

BEHÇET'S DISEASE: NOT ALWAYS IN THE MOUTH OR GENITAL REGION

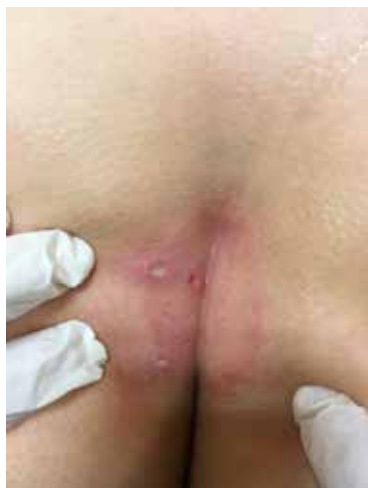Berna Solak, Büşra Aydın

Department of Dermatology, Sakarya University Training and Research Hospital, Sakarya, Turkey

A 24-year-old woman sought medical care for painful wounds on her buttocks. On dermatological examination, there were four punched out ulcers (ranging between 1-5 mm) on intergluteal area (Figure 1). She had been diagnosed with Behçet's disease 2 years ago. She had been using colchicine three times per day for 2 years. We thought that the lesions were extragenital ulcers of Behçet's disease. We initiated methylprednisolone 32 mg/day along with local wound care. When ulcer was recovered we started to taper methylprednisolone dose (Figure 2). Extragenital ulcers rarely occur in Behçet's disease. The ulcers resemble oral or genital aphthae and heal with cicatrice. It can occur as the first sign of the disease or can develop during the course of the disease. Here we report this patient to emphasize the importance of rare dermatologic manifestation of Behçet's disease.

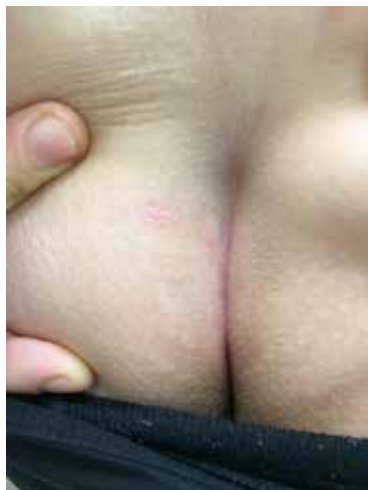Keywords: Extragenital ulcer, Behçet's Disease, Aphthae

Picture 1



Extragenital ulcerations

Picture 2



After Treatment



3rd INDERCOS

National Dermatology & Cosmetology Congress with International Participants

14-17 MARCH, 2018
HILTON ISTANBUL BOSPHORUS HOTEL
ISTANBUL, TURKEY

PP-037

[CUTANEOUS ONCOLOGY]

CD4/CD8 DOUBLE-NEGATIVE EPIDERMOTROPIC HYPOPIGMENTED T-CELL LYMPHOMA

Emin Ozlu¹, Mehmet Gamsizkan², Yunus Ozcan¹, Atike Bahcivan²

¹Department of Dermatology, Duzce University, Duzce, Turkey

²Department of Pathology, Duzce University, Duzce, Turkey

INTRODUCTION: The classification of cutaneous T-cell lymphoma (CTCL) is based on clinical, histological and immunohistochemical findings. However, in some cases, the classification is difficult. Mycosis fungoides (MF) is a CTCL with a wide array of clinical and pathological presentation. It can mimic other inflammatory and infectious dermatoses. CD4/CD8 double-negative MF is a rare variant of epidermotropic CTCL. Pagetoid reticulosis (PR) is a rare primary CTCL with distinct clinicopathologic features. We report here a case of CD4/CD8 double-negative CTCL that showed pathological findings quite similar to those of PR.

CASE: A 41-year-old woman had presented to our outpatient clinic for asymptomatic cutaneous lesions that had appeared on the upper extremities and trunk approximately 1 year previously. Dermatological examination revealed asymptomatic, erythematous, hypopigmented, scaly oval-round patches of up to 5 cm in diameter. Skin biopsy specimens showed an intraepidermal infiltration consisting of large atypical lymphocytes in a pagetoid pattern. Immunohistochemical stains showed CD3 positive T cells, double negative CD4 and CD8. Further studies did not reveal any internal organ, lymph node involvement and hematologic abnormalities. The patient was diagnosed with CD4/CD8 double-negative epidermotropic hypopigmented T-cell lymphoma based on the clinical, histopathological and immunohistochemical findings. The patient was effectively treated with topical corticosteroid and narrow-band ultraviolet B phototherapy and has yet not developed systemic involvement even after 9 months of regular follow up.

CONCLUSION: The present case was reported as CD4/CD8 double-negative epidermotropic hypopigmented T-cell lymphoma, which is a rarely encountered variant of CTCL. This immunophenotype does not seem to have prognostic significance.

Keywords: Mycosis fungoides, cutaneous T cell lymphoma, pagetoid reticulosis.

3rd INDERCOS

National Dermatology & Cosmetology Congress with International Participants

14-17 MARCH, 2018
HILTON ISTANBUL BOSPHORUS HOTEL
ISTANBUL, TURKEY



PP-038

[PAEDIATRIC DERMATOLOGY]

A CASE OF PRIMARY HYPEROXALURIA DEVELOPING NEPHROGENIC FIBROSING DERMOPATHY

Ezgi Özkur¹, İlknur Kıvanç Altunay¹, Yasemin Erdem¹, Gül Özçelik², Deniz Tuncel³

¹Health Science University, Şişli Hamidiye Etfal Training and Research Hospital, Dermatology Department

²Health Science University, Şişli Hamidiye Etfal Training and Research Hospital, Pediatric Nephrology Department

³Health Science University, Şişli Hamidiye Etfal Training and Research Hospital, Pathology Department

Primary hyperoxaluria is a rare, autosomal recessive inherited disease which is characterised by recurrent urolithiasis, nephrocalcinosis and oxalate deposition throughout the body. We present here 14 years old female infant with end stage renal disease due to primary hyperoxaluria and had been receiving periton dialysis since 10 years old. During the course of the disease, an aggressive arthropathy developed in the knees and ankles. Patient was immobile due to painful arthropathy. 2 years ago she underwent an MRI-joint scan using Gd-containing contrast material (gadodiamide-DTPA-BMA) and since than painful soft tissue swellings started and gradually became indurated on her legs. On physical examination, there were woody indurated papules with diffuse hyperpigmentation on her bilateral hands and shins. A punch biopsy from the shins demonstrated diffuse dermal fibroplasia with spindle cells extending into the subcutaneous tissues, mild interstitial mucin deposition, and minimal inflammation, features consistent with nephrogenic fibrosing dermopathy (NFD). Patient was suffering from concomitant pain in affected areas. The cutaneous findings associated with primary hyperoxaluria tend to result from vascular deposition and include livedo reticularis, acrocyanosis, ulceration and peripheral gangrene. We believe cutaneous Gd deposition may serve as a nidus for the development of NFD and it may lead contracted joints because of systemic fibrosing in this patient. There is no effective treatment for NFD. Plasmapheresis have shown some benefit in some patients.

Keywords: nephrogenic fibrosing dermopathy, primary hyperoxaluria, nephrocalcinosis



3rd INDERCOS

National Dermatology & Cosmetology Congress with International Participants

14-17 MARCH, 2018
HILTON ISTANBUL BOSPHORUS HOTEL
ISTANBUL, TURKEY

PP-039

[PIGMENTARY DISEASES]

EVALUATION OF THIOL/DISULFIDE HOMEOSTASIS PATIENTS WITH GENERALIZED VITILIGO

Suzan Demir Pektas¹, Aynure Oztekin², Coskun Oztekin³, Salim Neselioglu⁴, Ozcan Erel⁴

¹Department of Dermatology, Mugla Sitki Kocman University, Faculty of Medicine, Mugla, Turkey

²Department of Dermatology, Hitit University, Faculty of Medicine, Corum, Turkey

³Department of Family Medicine, Hitit University, Faculty of Medicine, Corum, Turkey

⁴Department of Biochemistry, Yildirim Beyazit University, Faculty of Medicine, Ankara, Turkey.

INTRODUCTION: Generalized vitiligo (GV) is an acquired depigmentation disorder, and oxidative stress is known to play a role in the pathophysiology of GV. Thiol disulphide homeostasis, a recently defined oxidative stress marker, has been shown to contribute to antioxidant protection, detoxification and apoptosis.

OBJECTIVE: We aimed to find out if there is a change in serum thiol / disulfide homeostasis in GV patients. We also determined to find out any possible association between serum thiol/ disulfide homeostasis and demographic data and clinical features of GV patients.

METHODS: 76 GV (30 males and 37 females) and 67 age and sex matched healthy individuals (29 females and 47 males) were included in the study. Demographic data, clinical features of GV patients, laboratory findings, were recorded. Thiol/disulfide homeostasis were evaluated by using automated spectrophotometric method.

RESULTS: GV patients had higher values for age. Native thiol, total thiol levels and native thiol/total thiol ratio was decreased, while disulfide/native thiol and disulfide/total thiol ratios were increased in the serum of GV, compared with control. Active GV patients had native thiol, total thiol levels and native thiol/total thiol ratio was decreased, while disulfide/native thiol and disulfide/total thiol ratios were increased in the serum of GV patients, compared with stable GV patients. Disease duration negatively correlated with native thiol and total thiol levels in GV patients.

CONCLUSION: A systemic oxidative stress exists in patients with GV. Thiol oxidation of active vitiligo patients had higher than stable GV patients. There is association between thiol oxidation and disease duration. Thiol oxidation may be responsible for loss of pigment in the pathogenesis of GV.

Keywords: Generalized vitiligo, thiol/disulfide homeostasis, oxidative stress

3rd INDERCOS

National Dermatology & Cosmetology Congress with International Participants

14-17 MARCH, 2018
HILTON ISTANBUL BOSPHORUS HOTEL
ISTANBUL, TURKEY



PP-040

[CUTANEOUS ONCOLOGY]

EARLY STAGE MYCOSIS FUNGOIDES WITH LARGE CELL TRANSFORMATION AND POSITIVE RESPONSE TO PERTUZUMAB CHEMOTHERAPY

İlkin Zindancı¹, Melike Kibar Öztürk¹, Meryem Doğan Altınpulluk², Ebru Zemheri²

¹Department of Dermatology, Umraniye Training and Research Hospital, Istanbul, Turkey

²Department of Pathology, Umraniye Training and Research Hospital, Istanbul, Turkey

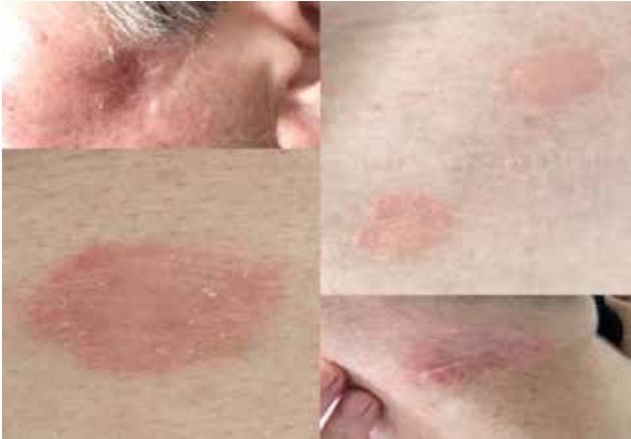INTRODUCTION: Mycosis fungoides (MF) comprises about 65% of cutaneous T-cell lymphomas. Large cell transformation (LCT) in MF has been defined by the presence of large cells (at least four times larger than a small lymphocyte) exceeding 25% of the total lymphoid infiltrate or forming microscopic nodules. LCT is more common in advanced-stage MF, but very rarely found in its early stage. LCT in MF is associated with an aggressive course and poor prognosis. Herein, we present a 70 year-old woman with stage IA MF whose lesions revealed large cell transformation with expression of CD30 immunostaining on histopathology.

CASE: This 70-year-old woman, with metastatic breast cancer, presented with multiple asymptomatic reddish rashes with minimal scales over the sternum, left preauricular region, left posterior lumbar region and left servikal area for 6 months. She had visited a local practitioner's clinic where she was diagnosed with psoriasis, but did not respond to treatment. Skin examination revealed multiple asymptomatic, scaly, wrinkling, mottled reddish patches over the sternum, left preauricular region, left posterior lumbar region and left servikal area (Figure 1). About 5% of the total body surface area was involved. There were no palpable lymph nodes or hepatomegaly. Peripheral blood did not show atypical lymphocytes. Chest x-ray revealed no significant findings. Four of the histopathology of biopsy specimens from reddish patches demonstrated mild infiltration of atypical cerebriform lymphocytes at the dermal-epidermal junction with focal epidermotropism and some areas with diffuse intradermal lymphocytic infiltration with large pleomorphic and hyperchromatic lymphocytes (Figure 2). Dermatoscopy of the lesions showed yellow-orange patches with dotted vessels (Figure 3). Based on the clinical manifestation with histopathological and dermatoscopic findings, the patient was diagnosed with MF with CD30-positive LCT. The staging of disease stage IB. The patient was having metastatic breast cancer and received pertuzumab chemotherapy at same same time with our diagnosis of MF. We administered topical steroid in addition to pertuzumab chemotherapy and her skin lesions regressed quickly and no new lesions were noted at the 3-month follow-up.

CONCLUSION: Herein, we reported a patient with Stage IA MF, who also showed focal CD30-positive LCT with positive response to pertuzumab chemotherapy. We wanted to report this rare case with CD30-positive LCT in an early stage of MF with dermatoscopic findings.

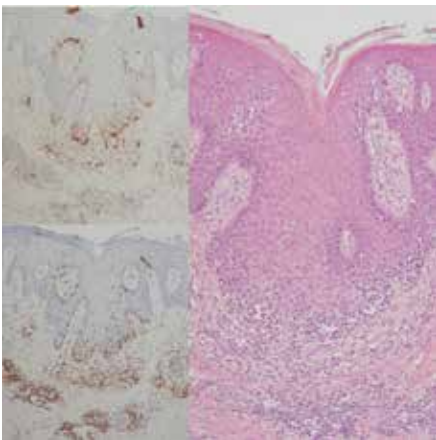
Keywords: mycosis fungoides, large cell transformation, pertuzumab, dermatoscopy

Figure 1



Clinical pictures of the patient before treatment: Multiple asymptomatic, scaly, wrinkling, mottled reddish patches over the sternum, left preauricular region, left posterior lumbar region and left servikal area

Figure 2



The histopathology of biopsy specimens: Mild infiltration of atypical cerebriform lymphocytes at the dermal-epidermal junction with focal epidermotropism and some areas with diffuse intradermal lymphocytic infiltration with large pleomorphic and hyperchromatic lymphocytes

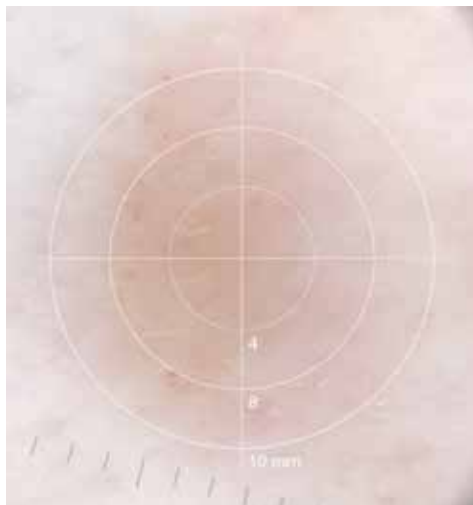3rd INDERCOS

National Dermatology & Cosmetology Congress with International Participants

14-17 MARCH, 2018
HILTON ISTANBUL BOSPHORUS HOTEL
ISTANBUL, TURKEY

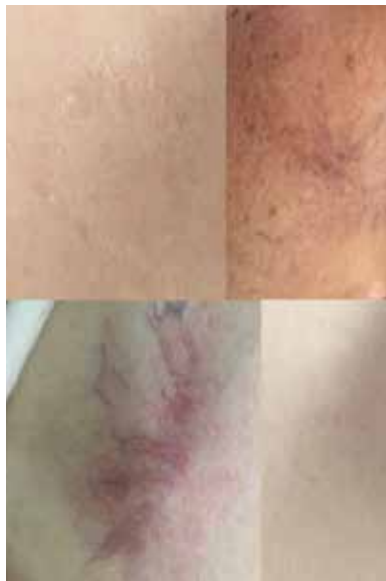

Figure 3



Dermatoscopy of the lesions: Yellow-orange patches with dotted vessels

Figure 4



*Clinical pictures of the patient after treatment
(same lesion sites as imported in figure 1)*



3rd INDERCOS

National Dermatology & Cosmetology Congress with International Participants

14-17 MARCH, 2018
HILTON ISTANBUL BOSPHORUS HOTEL
ISTANBUL, TURKEY

PP-041

[ADVERSE DRUG REACTIONS, TEN]

CAPECITABINE-INDUCED HAND-FOOT SYNDROME

Emin Ozlu¹, Yunus Ozcan¹, Onur Esbah²

¹Duzce University School of Medicine, Department of Dermatology, Duzce, Turkey

²Duzce University School of Medicine, Department of Oncology, Duzce, Turkey

INTRODUCTION: Hand-foot syndrome, also known as palmar-plantar erythrodysesthesia, is a cutaneous toxicity reaction caused by chemotherapeutics and biologic agents used in the treatment of malignant diseases. It is induced by the use of capecitabine, 5-fluorouracil, doxorubicin, interleukin-2, methotrexate, cisplatin. Capecitabine, an oral fluoropyrimidine drug, commonly causes cutaneous side effects. Clinically, erythema, edema, feeling of tension, numbness and burning sensation on palmoplantar region are observed in hand-foot syndrome. Treatment includes topical or oral corticosteroids, vitamin B6 (pyridoxine), celecoxib and topical antibiotics.

CASE: A 77-year-old male patient, who was diagnosed with hepatocellular carcinoma and received capecitabine, presented with painful, diffuse erythema, edema, erosions, and crusting on palmoplantar region. After the third course of capecitabine treatment, the patient complained of a progressive burning sensation in his hands and feet. The dermatological examination revealed painful, bilateral, erythematous, edematous plaque located in the palms and soles. In addition, widespread, necrotic, hemorrhagic crusts and erosions were revealed on the soles of his feet. He was diagnosed with hand-foot syndrome caused by the use of capecitabine. The responsible drug was stopped and the patient was successfully treated with topical 2% fusidic acid and wound dressing within two weeks.

DISCUSSION: Hand-foot syndrome is caused by the use of chemotherapeutics mostly in malignant diseases. All patients prescribed capecitabine should be advised for hand-foot syndrome.

Keywords: Capecitabine, side effect, hand-foot syndrome.

3rd INDERCOS

National Dermatology & Cosmetology Congress with International Participants

14-17 MARCH, 2018
HILTON ISTANBUL BOSPHORUS HOTEL
ISTANBUL, TURKEY



PP-042

[ANGIOLOGY, HAEMANGIOMAS, VASCULAR MALFORMATIONS, VASCULITIS] RHEUMATOID ARTHRITIS-ASSOCIATED CUTANEOUS VASCULITIS AND PLEURAL EFFUSION

Betül Şerefliçan¹, Gülden Konur¹, Çetin Boran², Ali Haydar Parlak¹

¹Department of Dermatology, Abant İzzet Baysal University, Bolu, Turkey

²Department of Pathology, Abant İzzet Baysal University, Bolu, Turkey

Vasculitis is a term describing inflammation and necrosis of the blood vessels. This condition may be idiopathic or secondary to infections, drugs, neoplasias or systemic inflammatory diseases. Rheumatoid arthritis is a systemic inflammatory disease that primarily affects synovial joints. Extra-articular manifestations include involvement of the skin, eyes, lungs and blood vessels. A seventy-five year old female patient presented to our clinic with complaint of wounds on the legs for one month. Her anamnesis revealed that she had the diagnosis of rheumatoid arthritis for 5 years and she had a history of diabetes mellitus. Physical examination revealed hemorrhagic bullae and ulcerated lesions on the anterior, lateral, and posterior aspects of both legs. Her skin biopsy result was compatible with leucocytoclastic vasculitis. Pleural effusion was detected during the follow-up period. Her thorax CT displayed bilateral subpleural soft tissue masses on the lung parenchyma, of which the one on the left was cavitary. Transthoracic biopsy was performed for the cavitary lesions of the lung. The biopsy result was identified as caseified granulomatous inflammatory event. Ehrlich-Ziehl-Neelsen staining didn't show tuberculosis bacillus. Based on the histopathological, laboratory and scanning findings, pulmonary involvement of the rheumatoid arthritis was thought. After treatment with methylprednisolone and methotrexate, clinical and laboratory findings rapidly improved. Rheumatoid vasculitis can show itself with a wide variety of involvements including neuropathy, rash, skin ulcers, gangrene and visceral organ abnormalities. This case is important since cutaneous vasculitis and pulmonary involvement of rheumatoid arthritis occurred simultaneously. We presented this case to draw attention to rheumatoid arthritis, a multisystemic disease that can also play a role in the etiology of vasculitis.

Keywords: Rheumatoid arthritis, cutaneous vasculitis, pleural effusion



3rd INDERCOS

National Dermatology & Cosmetology Congress with International Participants

14-17 MARCH, 2018
HILTON ISTANBUL BOSPHORUS HOTEL
ISTANBUL, TURKEY

PP-043

[ADVERSE DRUG REACTIONS, TEN]

EFFECTS OF DIFFERENT DOSES OF SYSTEMIC ISOTRETINOIN ON EYES: AN HISTOPATHOLOGICAL AND IMMUNOHISTOCHEMICAL STUDY

Remzi Karadag¹, Ayse Serap Karadag², Emin Ozlu³, Serpil Oguztuzun⁴, Gulcin Guler Simsek⁵, Oktay Esmer⁶, Sevda Gocer Onder⁷, Serap Gunes Bilgili⁸

¹Istanbul Medeniyet University, School of Medicine; Ophthalmology, Istanbul, Turkey

²Istanbul Medeniyet University, School of Medicine; Dermatology, Istanbul, Turkey

³Duzce University School of Medicine, Department of Dermatology, Duzce, Turkey

⁴Kirikkale University School of Medicine; Biology, Kirikkale, Turkey

⁵S.B.Kecioren Research and Training Hospital; Pathology, Ankara, Turkey

⁶Dogu Anadolu Hospital, Elazig, Turkey, Turkey

⁷Ordu University, Department of Dermatology, Ordu, Turkey, Turkey

⁸Yuzuncu Yil University, Faculty of Medicine, Department of Dermatology, Van, Turkey

INTRODUCTION: The systemic usage of retinoids may cause mucocutaneous, neuromuscular, gastrointestinal and ocular side effects. To evaluate ocular side effects associated with systemic isotretinoin histopathologically.

MATERIALS-METHODS: A total of 15 male and 15 female rats were randomly divided into three equal groups according to the dose of oral isotretinoin they were administered: 0 mg/kg/day (group A), 7.5 mg/kg/day (group B) and 15 mg/kg/day (group C). Biopsy specimens were taken from the conjunctiva, cornea and eyelid conjunctiva in order to make to histopathologic specimens. Expression levels of human beta defensin (HBD)-1, HBD-2, toll like receptor (TLR)-2 and TLR-4 were evaluated by immunohistochemical method.

RESULTS: The number of the goblet cells in eyelid conjunctiva were significantly lower in group B than those in group A and group C ($p<0.05$). The sizes of meibomian gland acini were significantly smaller in group B and group C than those in group A ($p<0.05$). While fibrosis of eyelid conjunctiva was not detected in group A, 4 focal and 10 focal, 4 severe fibrosis of eyelid conjunctiva were detected in group B and group C, respectively. The fibrosis of eyelid conjunctiva was significantly higher in group B and group C than those in group A ($p<0.05$). The expression levels of HBD-1, HBD-2, TLR-2 and TLR-4 in conjunctiva, cornea and eyelid conjunctiva had no significant difference between three groups ($p>0.05$).

CONCLUSION: Our study suggests that isotretinoin in the early period affects eyelid conjunctiva and meibomian glands without affecting the glob cornea and conjunctiva. In addition, the occurrence of initial symptoms of isotretinoin on the eyelids and especially on the meibomian glands suggests that the symptoms of the patients occur due to evaporative dry eye. We think our study will shed light on the ocular side effects of isotretinoin histopathologically.

Keywords: Isotretinoin, side effect, eye.

3rd INDERCOS

National Dermatology & Cosmetology Congress with International Participants

14-17 MARCH, 2018
HILTON ISTANBUL BOSPHORUS HOTEL
ISTANBUL, TURKEY



PP-044

[DERMATOPATHOLOGY]

KERATOACANTHOMA CENTRIFUGUM MARGINATUM ARISING OVER HYPERTROPHIC LICHEN PLANUS

Tarek Mohamed Arshah

Zliten Teaching Hospital, El-Mergib University, Libya

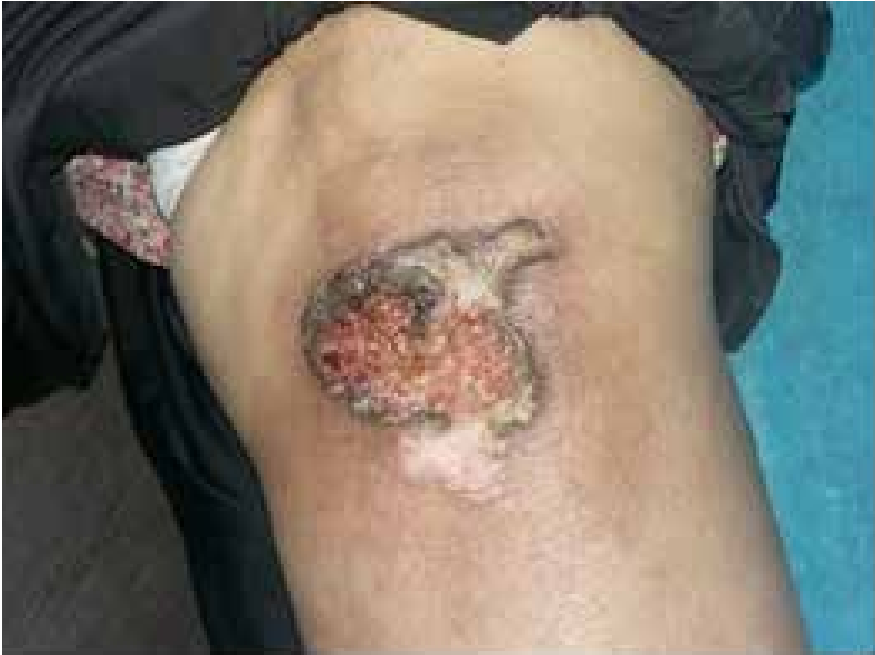Hypertrophic lichen planus (Lp) is one variety of Lp, and usually affects the shins. Keratoacanthoma (KA) and squamous cell carcinoma (SCC) overlying hypertrophic Lp were reported in literature.

CASE: 45 years old female presented to dermatology clinic with open (ulcerated) fungating mass at Lt. knee, which has been started before 5 years. The patient gave history of itchy skin lesions on both legs, which have started when she was 13 years old. On Examination, well defined 7x5 cm ulcerated plaque with elevated margin, at extensor surface of Lt. knee, lying on a lesion, which was partly hyperkeratotic hyperpigmented plaque, and partly atrophic and depigmented patch. On the extensor surface of both legs, there were scattered lesions of Hypertrophic Lp (Figure 1,2). Skin biopsy from ulcerated lesion at Lt. knee showed keratin filled crater with surrounding epidermis embedded deeply in dermis, with dyskeratotic cells, and keratinization giving the glassy appearance. These finding with absence of deep invasion into subcutaneous tissue was corresponding with KA (Figure 3). The histopathological examination of lesion on Rt. Knee was in favor of Lp (Figure 4, 5). The patient was referred to surgery for excision of KCM at Lt. knee.

DISCUSSION: KA and Squamous Cell Carcinoma (SCC) were reported to occur in hypertrophic LP. The favored sites for Keratoacanthoma Centrifugum Marginatum (KCM) are the pretibial regions and dorsum of the hands, which was similar to our finding in this reported case. Clinically, the lesion on Lt. leg of our reported case was typical for KCM, with progressive expansion at margin and involution at the centre. The histopathological finding of KA and a low-grade SCC are very similar which make the clinical picture is the key feature to recognize the definitive diagnosis. KAs in general were expected to heal spontaneously without any treatment, but KCM type was found not to have any tendency for spontaneous healing. Surgical removal of solitary KCM with amenable size, to be excised, is the preferred treatment. However, if surgery is not possible, other therapies could be tried, like oral retinoids, topical 5-fluorouracil as well as Intra-lesional injection of methotrexate, interferon alfa, 5-fluorouracil, or bleomycin. The effectiveness of systemic oral Retinoids is controversial with reports showed no efficacy of oral Retinoids in treatment of KCM. In our patient, surgical excision was performed, that our patient would like to get pregnant in near future and she was anxious about malignant changes in ulcerated lesion at Lt. Knee, although, it was explained to her that, in literature, regarding this type of epidermal growth, there was a study involved hundreds of patients with the same diagnosis (KCM), concluded that, no death or metastasis were reported. Our patient was well and showed no recurrence at the site of excision of KCM during the follow up visits in 6 months and 1 year after surgery.

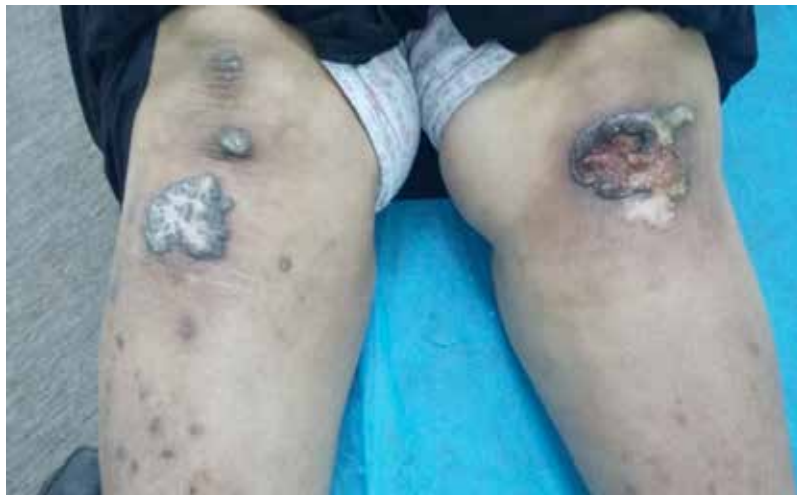Keywords: Keratoacanthoma centrifugum marginatum, hypertrophic lichen planus, oral retinoids

Figure 1



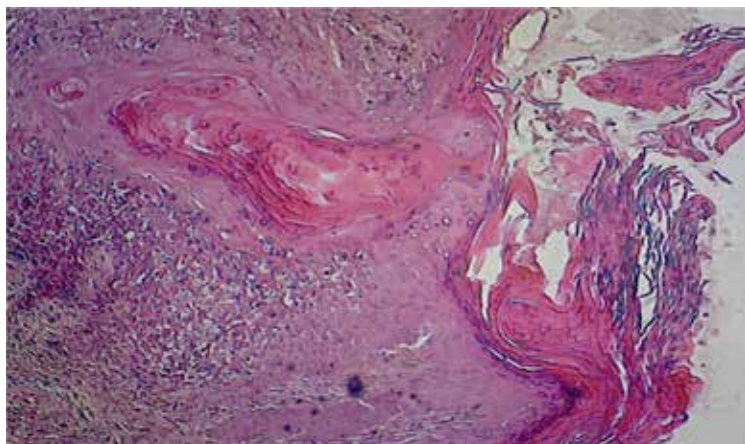
KCM at extensor surface of Lt. Knee.

Figure 2



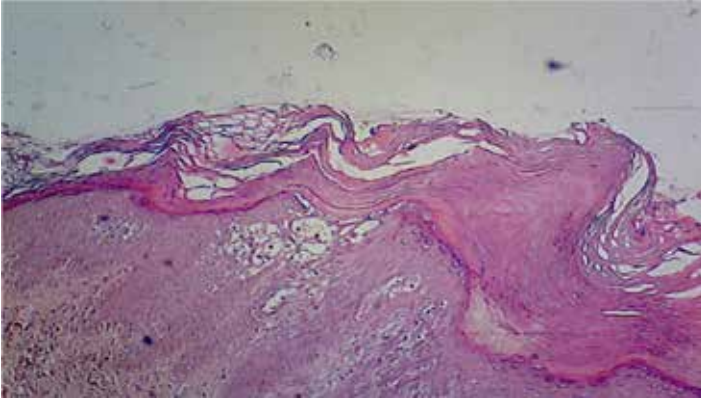hypertrophic LP lesions located on extensor surfaces of both legs

Figure 3



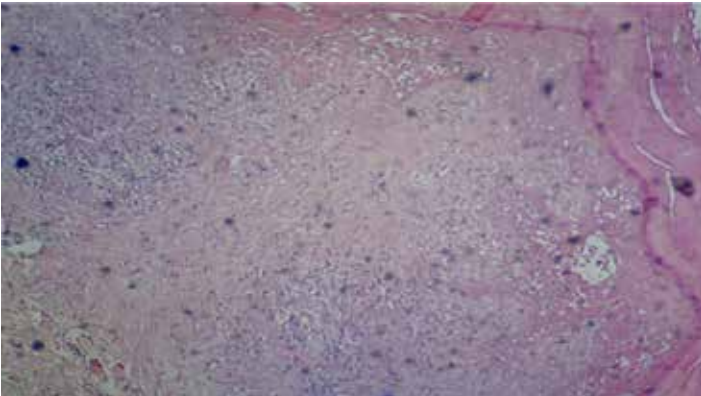
KA from Lt. knee lesion

Figure 4



Compact hyperkeratosis, hypergranulosis, Liquefaction degeneration are diagnostic features of Lp

Figure 5



Lichenoid lymphocytes in the papillary dermis with saw-toothed rete ridges are important features of Lp

3rd INDERCOS

National Dermatology & Cosmetology Congress with International Participants

14-17 MARCH, 2018
HILTON ISTANBUL BOSPHORUS HOTEL
ISTANBUL, TURKEY



PP-045

[HAIR DISORDERS/DISEASES]

FRONTAL FIBROSING ALOPECIA PRESENTING WITH LICHEN PLANUS PIGMENTOSUS

Ezgi Ozkur, Ilknur Altunay

Health Science University, Şişli Hamidiye Etfal Training and Research Hospital, Dermatology Department

A 45-year-old caucasian woman who presented to our clinic for a two-year history of pigmentation on her face and neck and also hair loss on frontal hairline. She also reported losing hair from her eyebrows. Past medical history included mucosal lichen planus 4 years ago which is treated with topical corticosteroids and didn't relapse since then. Her medical and family history otherwise unremarkable. No history of chronic medication could be elicited and there isn't any history of photosensitivity in her past. On dermatological examination, we found scarring alopecia with follicular papules and mild scaling over frontal the vertex. She had recession of frontotemporal hairline with bilaterally symmetrical band-like scarring alopecia of the same region. On her face and neck there were ill-defined, lightbrown-to-grey diffuse patches which are darker in malar area. Also there were follicular papules on her eyebrows with nonscarring alopecia and desquamation on nasolabial folds. Laboratory investigations were in normal limits and anti-nuclear-antibody(ANA) was negative. A punch biopsy was performed and histopathological examination of affected scalp revealed disruption of the follicular unit architecture, loss of sebaceous glands, and decrease in the number of hair follicles, which were replaced by fibrous tracts which were consistent with frontal fibrosing alopecia. A biopsy specimen from the neck shows a superficial, perivascular, lymphocytic infiltrate with numerous melanophages within the papillary dermis which were consistent with lichen planus pigmentosus. Recently, there has been an association described between of lichen planus pigmentosus and frontal fibrosing alopecia but particularly in African patients. We present this case because it is very rare in caucasian patients.

Keywords: frontal fibrosing alopecia, alopecia, lichen planus, lichen pigmentosus



3rd INDERCOS

National Dermatology & Cosmetology Congress with International Participants

14-17 MARCH, 2018
HILTON ISTANBUL BOSPHORUS HOTEL
ISTANBUL, TURKEY

PP-046

[PIGMENTARY DISEASES]

EVALUATION OF CARCINOGENIC POTENTIAL OF DIFFERENT ULTRAVIOLET RAYS USED IN THE TREATMENT OF PHOTORESPONSIVE DERMATOSES IN DARK SKINNED PATIENTS: A PILOT STUDY

Randa Youssef¹, Heba Mashaly¹, Ossama Shereen¹, Maha Fathy Elmasry¹, Olfat Shaker²

¹Dermatology Department, Faculty of Medicine, Cairo University, Egypt

²Medical Biochemistry & Molecular Biology department, Faculty of Medicine, Cairo University, Egypt

BACKGROUND & OBJECTIVES: 8-oxoguanine, a major product of DNA oxidation, is considered a key parameter in measuring the carcinogenic effects of ultraviolet radiation. Our objective is to assess and compare the carcinogenic potential of different photo (chemo) therapeutic modalities in photoresponsive skin diseases by measuring the levels of 8-oxoguanine in dark-skinned individuals before and after photo (chemo) therapy.

MATERIALS & METHODS: A prospective, randomized controlled pilot study was conducted in 63 patients of skin types III-V with photo-responsive dermatoses including vitiligo, psoriasis and mycosis fungoides. Patients were divided into three groups; Group 1 (received narrowband ultraviolet-B), Group 2 (received psoralen plus ultraviolet-A) and Group 3 (received broadband ultraviolet-A). Biopsies were taken before and after phototherapy to measure 8-oxoguanine levels using enzyme-linked immunosorbent assay. Biopsies were also taken from the sun-protected skin in 21 controls subjects who had no dermatological disease.

RESULTS: Regardless of the disease, a significantly higher level of 8-oxoguanine was found after treatment when compared to the pre-treatment baseline levels; however, these levels were comparable to those in control subjects. A weakly significant positive correlation was found between cumulative dose and 8-oxoguanine levels following psoralen plus ultraviolet-A therapy. In controls, comparing the 8-oxoguanine levels between skin types III and IV showed significantly lower 8-oxoguanine in skin type IV.

CONCLUSION: Therapeutic doses of ultraviolet radiation are relatively safe in dark skinned patients; however, minimizing the cumulative dose of phototherapeutic modalities (particularly psoralen plus ultraviolet-A) is recommended.

Keywords: 8-oxoguanine, skin cancer, phototherapy, NBUVB, UVA, PUVA

3rd INDERCOS

National Dermatology & Cosmetology Congress with International Participants

14-17 MARCH, 2018
HILTON ISTANBUL BOSPHORUS HOTEL
ISTANBUL, TURKEY



PP-047

[CUTANEOUS ONCOLOGY]

KAPOSI SARCOMA DEVELOPED AFTER ORGAN TRANSPLANTATION

Selma Korkmaz¹, İljal Erturan¹, Elif Emine Ozkan², Dudu Dilek Yavuz³, İbrahim Metin Ciriş⁴, Murat Koçer⁵, Mehmet Yıldırım¹

¹Suleyman Demirel University Faculty of Medicine, Department of Dermatology

²Suleyman Demirel University Faculty of Medicine, Department of Radiation Oncology

³Suleyman Demirel University Faculty of Medicine, Department of Plastic and Reconstructive Surgery

⁴Suleyman Demirel University Faculty of Medicine, Department of Pathology

⁵Suleyman Demirel University Faculty of Medicine, Department of Medical Oncology

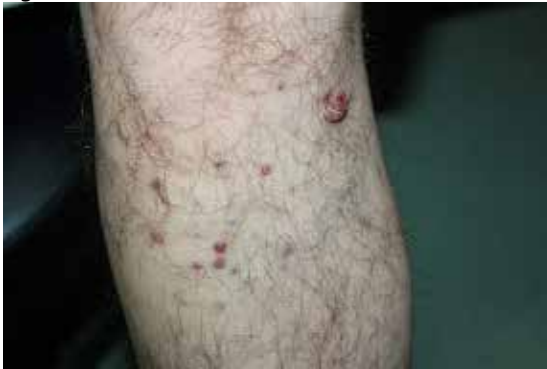INTRODUCTION: Kaposi's sarcoma (KS) is a malignant angiomatous neoplasm which was firstly described in 1872. Various clinical types of Kaposi's sarcoma are identified as classical, endemic (African type), epidemic (AIDS related), and iatrogenic. The disease can involve internal organs as well as skin. The diagnosis of KS is made via clinical findings and histopathologic examination. We presented here a 58-year-old male patient with iatrogenic Kaposi's sarcoma diagnosed after renal transplantation.

CASE: A 58-year-old man was admitted to our clinic with purple rash on the front of his right leg which was present for 2 months and he wasn't given any treatment since. The patient had congenital rudimentary kidney and was receiving dialysis treatment for 8 years due to chronic renal failure secondary to 10 years history of hypertension. The patient was undergone kidney transplantation 2 years ago and was treated with systemic tacrolimus (1 gr / day), prednisolone (5 mg / day) and mycophenolate mofetil (1 gr / day). Patient's dermatologic examination revealed purple papules on foot and anterior surface the right tibia (Fig. 1). Patient's hemogram, thyroid function tests, liver function tests and renal functions were in normal ranges. The patient was diagnosed as Kaposi sarcoma with clinical and histopathological findings (Fig. 2). Radiological work up for staging revealed no systemic involvement. The patient was consulted with medical oncology. The immunosuppressive treatment reevaluated and switched to everolimus 1.5 mg / day. The patient was also consulted with radiation oncology; however, radiotherapy was not suggested while he was immunocompromised.

DISCUSSION: Iatrogenic type Kaposi's sarcoma is not an uncommon entity in renal transplant patients especially after 16th month of immunosuppressive treatment. The lesions may be presented in a localized or widespread form. Distant spread of the disease is attributed to immunosuppression. Reduction or cessation of immunosuppression supports the treatment to provide complete remission. Excision, cryotherapy and radiotherapy are among the treatment options in localized lesions. Delayed onset of the lesions confirms the iatrogenic Kaposi's sarcoma in this case. The patient is in follow with clinically stable disease and his current immunosuppressive therapy is maintained with everolimus. In conclusion, cutaneous malignancies such as Kaposi's sarcoma should be kept in mind for organ transplant and immunosuppressive patients.

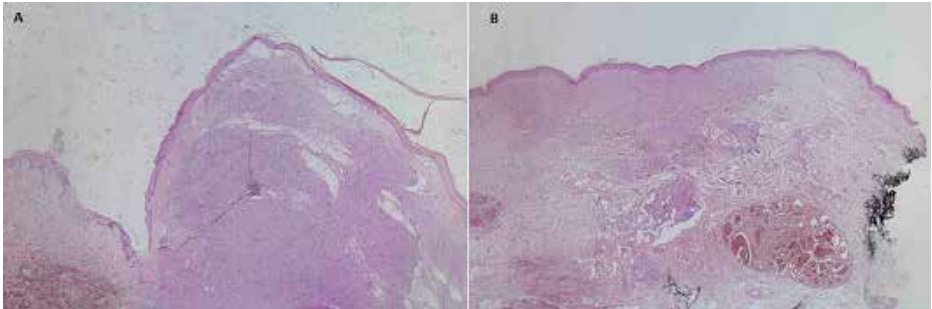
Keywords: kaposi sarcoma, immunnosupression, organ transplantation

Figure 1



Multiple purple papules and nodules on right tibia anterior surface

Figure 2 A and B



2A: Flat dermal lesion characterized by proliferation of numerous slit-like vascular spaces in the dermis and cutaneous appendages. H&E, 20x 2B: Dermis is expanded by a solid tumor nodule. Fascicles of relatively monomorphic spindled cells. H&E, 20x

3rd INDERCOS

National Dermatology & Cosmetology Congress with International Participants

14-17 MARCH, 2018
HILTON ISTANBUL BOSPHORUS HOTEL
ISTANBUL, TURKEY



PP-048

[AUTOIMMUNE CONNECTIVE TISSUE DISORDERS]

COEXISTENCE OF ERUPTIVE SYRINGOMA AND DISCOID LUPUS ERYTHEMATOSUS: A CASE REPORT

Sinem Ayşe Örnek¹, Tülin Yüksel¹, Seza Kunter¹, Özge Yöntem Günver¹, Tuğba İpin², Emek Kocatürk¹

¹Department of Dermatology, Okmeydani Training and Research Hospital, Istanbul, Turkey

²Department of Pathology, Okmeydani Training and Research Hospital, Istanbul, Turkey

Syringomas are benign adnexal neoplasm developing from the eccrine sweat glands. Eruptive syringoma (ES) is a very rare variant that presents with multiple, smooth-surfaced, yellowish or skin-colored papules on the face, anterior parts of neck and trunk. The pathophysiology of ES is still unknown. Recently, the role of the autoimmune response, rather than reactive proliferation of acrosyringium in the pathogenesis have been suggested. Reported association between ES and diabetes mellitus, alopecia areata or vitiligo supports a theory of an autoimmune role. Also, discoid lupus erythematosus (DLE) is an autoimmune disorder usually occurs on sun exposed areas of head and neck. We reported a case of ES and DLE in a 63-year old female. This is the first report that is describing of coexistence of ES and DLE as far as we know.

Keywords: eruptive syringoma, discoid lupus erythematosus, autoimmune

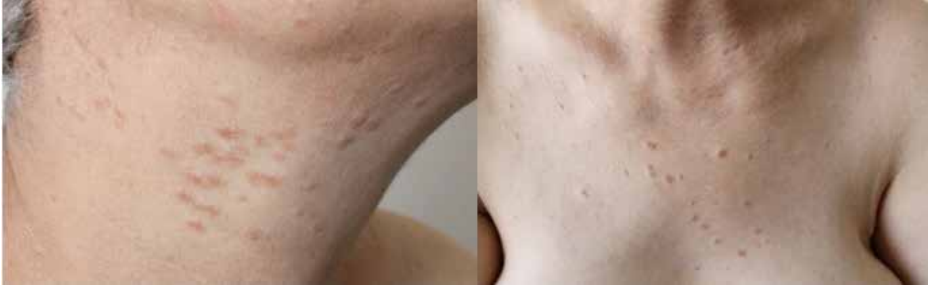

3rd INDERCOS

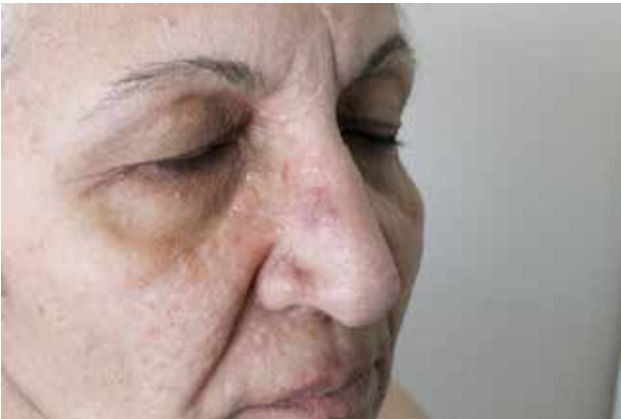National Dermatology & Cosmetology Congress with International Participants

14-17 MARCH, 2018
HILTON ISTANBUL BOSPHORUS HOTEL
ISTANBUL, TURKEY

Clinical image



Eruptive syringomas on the neck and the chest



DLE lesion on the lateral aspect of the nose

3rd INDERCOS

National Dermatology & Cosmetology Congress with International Participants

14-17 MARCH, 2018
HILTON ISTANBUL BOSPHORUS HOTEL
ISTANBUL, TURKEY



PP-049

[CUTANEOUS ONCOLOGY]

PRIMARY CUTANEOUS MARGINAL ZONE LYMPHOMA WITH LYMPH NODES AND BONE MARROW INVOLVEMENT

Emin Ozlu¹, Birgul Onec², Yunus Ozcan¹, Ebru Karagun¹, Mehmet Gamsizkan³, Ozgur Mehtap⁴

¹Duzce University School of Medicine, Department of Dermatology, Duzce, Turkey

²Duzce University School of Medicine, Department of Hematology, Duzce, Turkey

³Duzce University School of Medicine, Department of Pathology, Duzce, Turkey

⁴Kocaeli University, School of Medicine, Department of Hematology, Kocaeli, Turkey

INTRODUCTION: Primary cutaneous B-cell lymphomas are extranodal non-Hodgkin lymphomas that constitute 25% of all cutaneous lymphomas. Primary cutaneous marginal zone lymphoma (PCMZL) is one of the most common B-cell lymphomas. It typically affects patients in their fourth decade and manifests with multiple nodules mainly on the arms and upper trunk. The main therapeutic options include radiotherapy and surgery. Non-cutaneous dissemination of PCMZL is extremely rare.

CASE: A 63-year old woman developed four nodular lesions with a diameter of 0.5-1.5 cm of her back over six months. The skin biopsy obtained from the nodular lesion was compatible with cutaneous marginal zone lymphoma. Based on the medical history, clinical, histopathological and immunohistochemical findings, the patient was diagnosed with PCMZL. Further investigations confirmed stage 4 cutaneous marginal zone lymphoma with atypical lymphoid cells in bone marrow. Positron emission tomography-computed tomography scan showed increased pathological uptake at cervical and mediastinal lymph nodes. Cutaneous lesions were treated with radiotherapy. She was not started on systemic treatment due to the indolent course of the disease and had no symptom without skin involvement. Clinical and laboratory close follow up was obtained from the patient.

CONCLUSION: This case is reported due to its rare occurrence and having lymph nodes and bone marrow involvement.

Keywords: Marginal zone lymphoma, lymph node, bone marrow, systemic involvement.



3rd INDERCOS

National Dermatology & Cosmetology Congress with International Participants

14-17 MARCH, 2018
HILTON ISTANBUL BOSPHORUS HOTEL
ISTANBUL, TURKEY

PP-050

[PAEDIATRIC DERMATOLOGY]

GENERALIZED LICHEN PLANUS IN A PEDIATRIC PATIENT

Irem Mantar¹, Gülbahar Saraç¹, Hülya Cenk², Serpil Şener¹, Didem Kısacık¹, Yelda Kapıcıoğlu¹

¹Department of Dermatology, Inonu University, Malatya, Turkey

²Department of Dermatology, Sorgun State hospital, Yozgat, Turkey

INTRODUCTION: Lichen planus (LP) is an inflammatory and pruritic dermatosis. It's seen in 0,5-1 % of the adult population while it's rare in children. Pediatric cases compose 5% of all the patients with LP. It's usually manifest as violaceous, pruritic, polygonal and planar lesions in flexural regions. Scalp, nails and orogenital mucosa may be involved. Involvement of palms and soles is relatively rare. Topical or systemic antiinflammatory agents according to the clinical severity are used for the treatment of LP. There are few cases of LP treated with topical tacrolimus. Here in this case, we will present a 4-year-old child with extensive LP lesions distributed all over his body, who is treated with a combination therapy including topical tacrolimus.

CASE: A 4-years-old child was brought to our clinic with pruritic lesions on the arms, legs and sparsely on the trunk since last 25 days. At the dermatological examination, there were pruritic papules and plaques on his arms, legs and trunk with no mucosal and nail involvement. Laboratory and radiologic findings like kidney and liver function tests, complete blood count, albumin level and hepatitis panel were normal. His lesions regressed after the treatment with topical steroids. One month later, he came back with extensive lichenoid lesions covering 80% of his body and with palmoplantar desquamation and hyperkeratosis (Figure 1,2). He was hospitalized and treated with 1 mg/kg systemic steroid, topical steroid alternately with 0,01% tacrolimus ointment. Systemic steroid dosage was tapered gradually in ten days and then stopped. The patient continued the topical tacrolimus ointment as a maintenance treatment and after 3-month follow up, there was only postinflammatory hyperpigmentation left.

DISCUSSION: This patient had a typical lichen planus clinic but approximately with an 80% involvement of the total body surface. Additionally, there was palmoplantar involvement of LP which is rarely encountered even in reported large case series. The lesions were controlled in the first treatment course but after the last severe recurrence, he was treated with systemic steroids in combination with topical tacrolimus ointment. CD8 T-cells play an important role in the LP etiopathogenesis. They cause a degeneration on basal keratinocytes via cell-mediated immunity. Tacrolimus blocks the production of interleukin-2 (IL-2), a growth factor for T-cell proliferation. It's generally preferred in oral lichenoid lesions, but recently cutaneous lichen planus has been another treatment field. Tacrolimus treatment in the pediatric patients with LP has been reported in a limited number of cases.

CONCLUSION: Lichen planus is a rare and pruritic disease in the pediatric population. Now that the topical drugs are absorbed more in a pediatric patient, topical steroids may have more unwanted side effects in the long term. So, topical tacrolimus treatment may represent a useful treatment option for childhood LP.

3rd INDERCOS

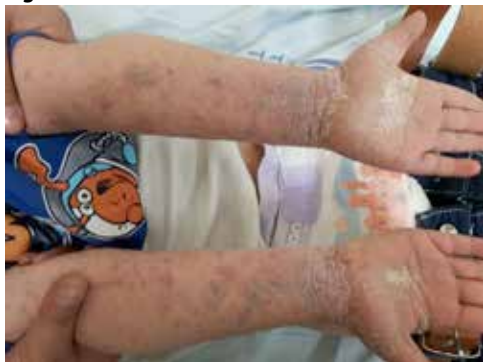National Dermatology & Cosmetology Congress with International Participants

14-17 MARCH, 2018
HILTON ISTANBUL BOSPHORUS HOTEL
ISTANBUL, TURKEY



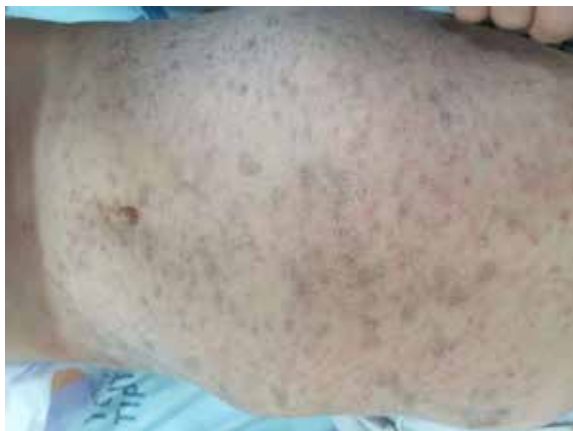Keywords: lichen planus, child, topical tacrolimus

Figure 1



lichenoid papules and plaques on arms and palmar hyperkeratosis

Figure 2



lichenoid papules and plaques on trunk



3rd INDERCOS

National Dermatology & Cosmetology Congress with International Participants

14-17 MARCH, 2018
HILTON ISTANBUL BOSPHORUS HOTEL
ISTANBUL, TURKEY

PP-051

[PAEDIATRIC DERMATOLOGY]

ATRICHIA CONGENITA WITH TWENTY-NAIL DYSTROPHY: A CASE REPORT

Begüm Ünlü, Büşra Deniz, Melodi Çekiç, Ümit Türsen

Department of Dermatology, Mersin University medical school, Mersin, Turkey

Congenital atrichia is the absence of whole body hair at birth, an inherited condition that may be inherited as an autosomal dominant or autosomal recessive pattern. It can be isolated or associated with other anomalies. Twenty-nail dystrophy, is used to describe thin, brittle nails with excessive longitudinal ridging. Both of the entities are rare disorders.

An 6 month old female patient, referred to our dermatology clinic with absence of whole body hair, nevus flammeus on her neck and twenty-nail dystrophy since birth. They did not report abnormal dentition, abnormal sweating or anhidrosis, musculoskeletal, ocular, or neurologic symptoms.

This is first case in english literature presented with congenital atrichia, twenty nail dystrophy and nevus flammeus.

Keywords: atrichia, alopecia, nail, trachyonychia, navus flammeus

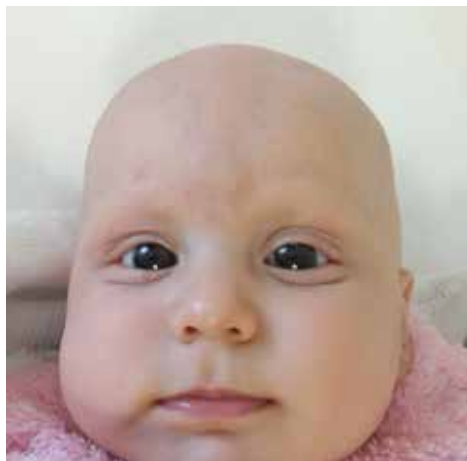3rd INDERCOS

National Dermatology & Cosmetology Congress with International Participants

14-17 MARCH, 2018
HILTON ISTANBUL BOSPHORUS HOTEL
ISTANBUL, TURKEY

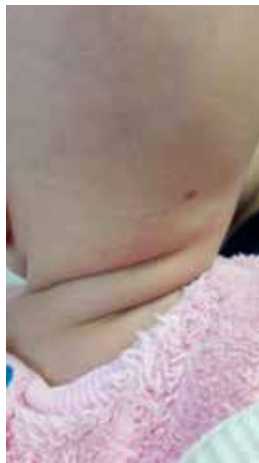

Figure 1



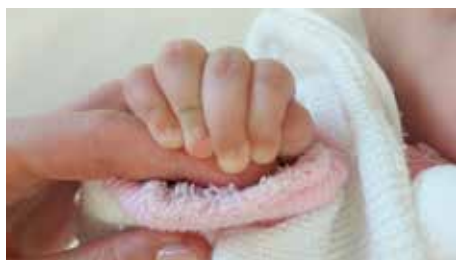Absence of eyebrow, eyelashes and scalp hair

Figure 2



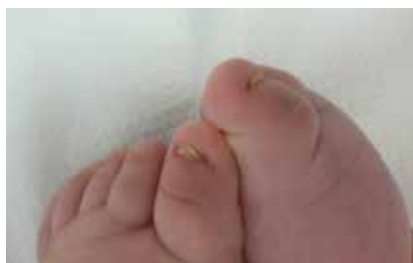Nevus flammeus

Figure 3



Twenty-nail Dystrophy

Figure 4



Twenty-nail Dystrophy



3rd INDERCOS

National Dermatology & Cosmetology Congress with International Participants

14-17 MARCH, 2018
HILTON ISTANBUL BOSPHORUS HOTEL
ISTANBUL, TURKEY

PP-052

[INFLAMMATORY SKIN DISEASES]

THIOL/DISULFIDE HOMEOSTASIS AND ITS RELATION WITH INSULIN RESISTANCE PATIENTS WITH ROSACEA

Suzan Demir Pektas¹, Nese Cinar², Gokhan Pektas³, Gulhan Akbaba², Ahmet Kara⁴, Hilal Semra Hancer¹, Deniz Demircioglu Duman⁵, Salim Neselioglu⁶, Ozcan Erel⁶, Duygu Yazgan Aksoy⁷

¹Mugla Sitki Kocman University, Faculty of Medicine, Department of Dermatology, Mugla/TURKEY

²Mugla Sitki Kocman University, Faculty of Medicine, Department of Endocrinology and Metabolic Diseases, Mugla/TURKEY

³Mugla Sitki Kocman University, Faculty of Medicine, Department of Internal Medicine, Mugla/TURKEY

⁴Mugla Sitki Kocman University, Faculty of Medicine, Department of Family Medicine, Mugla/ TURKEY.

⁵Acibadem University, Department of Dermatology, Istanbul/TURKEY

⁶Yildirim Beyazit University, Faculty of Medicine, Department of Biochemistry, Ankara/TURKEY

⁷Acibadem University, Department of Internal Medicine, Istanbul/TURKEY.

INTRODUCTION: Rosacea is chronic inflammatory skin disorder which is reported to have a association with cardiometabolic disorders. Oxidative stres is known to play a role in the pathophysiology of rosacea. Thiol disulphide homeostasis, a recently defined oxidative stress marker, has been shown to contribute to antioxidant protection, detoxification and apoptosis.

OBJECTIVE: We aimed to find out if there is a change in serum thiol / disulfidehomeostasis in rosacea patients. We also determined to find out any possible association between serum thiol/ disulfide homeostasis and metabolic parameters.

METHODS: 42 rosacea patients (16 males and 26 females) and 50 age and sex matched healthy individuals (30 females and 20 males) were included in the study. Demographic data, clinical features of rosacea patients, anthropometric measures, laboratory findings, and blood pressure levels were recorded. Thiol/disulfide homeostasis were evaluated by automated spectrophotometric method.

RESULTS: Rosacea patients had high values for weight (72.9 ± 12.9 kg vs. 63.1 ± 7.6 kg, $p < 0.001$), BMI (27.9 ± 5.2 kg/m² vs. 23 ± 1.4 kg/m², $p < 0.001$), WHR (0.87 ± 0.1 vs. 0.77 ± 0.8 , $p < 0.001$), FPG (90.8 ± 16.4 mg/dL vs. 84.3 ± 8.6 mg/dL, $p < 0.05$), basal insulin levels (13.2 ± 8.3 mU/l vs. 6.5 ± 2.4 mU/l, $p < 0.001$) and HOMA-IR values (3.0 ± 2.0 vs. 1.3 ± 0.5 , $p < 0.001$) compared to the control group. Disulfide levels, disulfide/nativethiol and disulfide/ total thiol ratios were increased ($p < 0.05$), while nativethiol, total thiol levels and native thiol/total thiol ratio was decreased in the serum of rosacea patients ($p < 0.05$). Rosacea subtype had no effect on oxidative stres markers. Disease duration positively correlated with disulfide/nativethiol and disulfide/total thiol ratios in rosacea group. Increased disulfide/nativethiol, disulfide/total thiol ratios and decreased native and total thiol levels and native/total thiol were also significantly associated with basal insulin and HOMA-IR values.

CONCLUSION: Thiol oxidation increases in rosacea patients and and insulin resistance are more common in rosacea patients. Chronic inflammation with increased insulin resistance may have a role in the pathogenesis of increased oxidative stress in rosacea or vice versa.

Keywords: Rosacea, oxidative stress, insulin resistance.



PP-053

[PHOTOBIOLOGY AND PHOTOALLERGY]

A PEDIATRIC CASE OF HYDROA VACCINIFORME TREATED WITH HYDROXYCHLOROQUINE

Irem Mantar¹, Gülbahar Saraç¹, Hülya Cenk², Serpil Şener¹, Yelda Kapıcıoğlu¹

¹Department of Dermatology, Inonu University, Malatya, Turkey

²Department of Dermatology, Sorgun State hospital, Yozgat, Turkey

INTRODUCTION: Hydroa vacciniforme (HV) is a very rare disease with childhood-onset and it regresses spontaneously in the early adulthood. HV affects the sun-exposed areas of the body and heals with scarring. Quality of life (QoL) Index in patients with HV is lower than the patients with psoriasis and atopic dermatitis. Herein, we will present a severe case of HV treated with systemic steroid and hydroxychloroquine.

CASE: A 12 years old boy was brought to our polyclinic by his family with the complaint of wounds on the face, neck and arms. He had erythematous and impetiginous crusted plaques on his face, neck and ears besides periorbital edema on the face. There were necrotic crusted, erythematous papules with a sharp demarcation line beginning from proximal arms and the lesions spread distally with some atrophic scars (Picture 1-2). Laboratory findings such as serum level of ANA and porphyrins were normal. The polymerase chain reaction results were negative for herpes simplex virus type 1 and 2. After consulting the Department of Ophthalmology, 20 mg/d systemic steroid, 5 mg/kg hydroxychloroquine and topical steroid treatments were commenced. The patient was advised to protect himself from the sun by using sunscreens. The lesions had completely regressed and there wasn't any recurrence of the lesions within 2 months.

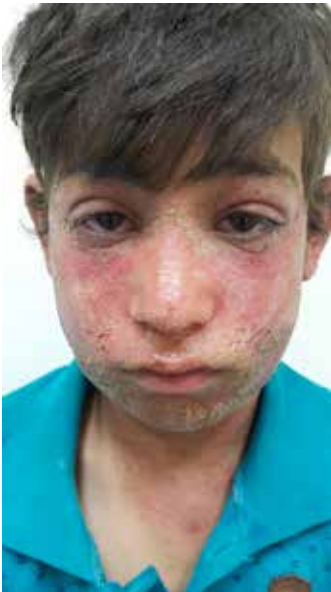DISCUSSION: HV is a rare childhood photodermatosis and differential diagnoses include polymorphic light eruption, porphyria cutanea tarda, erythropoietic porphyria, bullous lupus erythematosus, actinic prurigo and solar urticaria. Additionally, HV like T cell lymphoma (HVLL) is similar to HV in terms of clinical lesions like necrotic crusts and papulovesicles, but differently, HVLL affects also the sun-spared skin. HV is accompanied by systemic signs and findings like fever, weariness, anemia, hepatomegaly and often associated with EBV infection. Histochemical immunostaining with EBNA and LMP is important in discriminating between HV and HVLL. Also, Chin Chen et al. conducted a study indicating that 17 % of the patients with HV might progress to HCLL during a long-term follow-up. HV etiology has been still unclarified and there isn't any definitive treatment but still, sun-screens may be enough for those having a mild disease. There are few case reports regarding the treatment with antimalarial drugs in HV patients. Antimalarial drugs reduce the recurrence of the HV lesions by raising UVA/UVB exposure threshold required for the development of HV lesions. Therefore, these drugs enhance the QoL by allowing prolonged sun-exposure time.

CONCLUSION: Herein, we present a severe HV case treated with hydroxychloroquine.

Hydroxychloroquine is a good treatment option for HV patients now that it provides a lower the rate of recurrence and a higher QoL. Also, it must be kept in mind that HV must be discriminated from HVLL and there is a risk of HVLL development in HV patients over the long years.

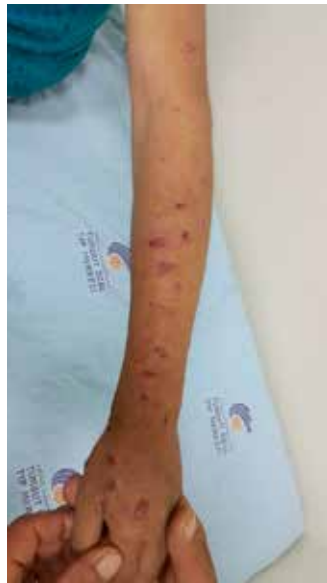Keywords: Hydroa vacciniforme, Hydroxychloroquine, photodermatosis

Figure 1



*erythematous and impetiginous crusted plaques
on his face, neck and ears*

Figure 2



necrotic crusted, erythematous papules on arm

3rd INDERCOS

National Dermatology & Cosmetology Congress with International Participants

14-17 MARCH, 2018
HILTON ISTANBUL BOSPHORUS HOTEL
ISTANBUL, TURKEY



PP-054

[PHOTOTHERAPY, PHOTODYNAMIC THERAPY]

ROLE OF LONG-WAVELENGTH ULTRAVIOLET A1 (UVA1) PHOTOTHERAPY IN ACRAL VITILIGO

Bakr Mohamed El Zawahry, Maha Fathy Elmasry, Amira Ragab
Dermatology Department, Faculty of Medicine, Cairo University, Egypt

INTRODUCTION: Response of acral vitiligo to treatment is often disappointing. Our objective was to evaluate the effect of medium dose long-wavelength ultraviolet A (UVA1) phototherapy (40 J -70 J) in the treatment of acral vitiligo and comparing it with topical psoralen and ultraviolet A (PUVA).

Material/METHODS: Patients in this comparative study (over 12 weeks) were divided into two groups; medium dose UVA1 group & topical PUVA group (10 acral vitiligo patients each). Every patient was clinically evaluated monthly according to point counting and vitiligo area and severity index (VASI).

RESULTS: No statistically significant clinical difference was found between patients in UVA1 and topical PUVA groups.

CONCLUSIONS: Further studies using higher UVA1 doses should be performed.

Keywords: UVA1, acral vitiligo, topical PUVA



3rd INDERCOS

National Dermatology & Cosmetology Congress with International Participants

14-17 MARCH, 2018
HILTON ISTANBUL BOSPHORUS HOTEL
ISTANBUL, TURKEY

PP-055

[DERMATOPATHOLOGY]

A NEWBORN WITH AN ORAL MASS: NON-NEURAL GRANULAR CELL TUMOR

Ebru Zemheri¹, Müzeyyen Müge Savaş¹, Ceyhan Şahin², İlkin Zindancı³

¹Department of Pathology, Sağlık Bilimleri University, Umraniye SUAM Training and Research Hospital, Istanbul, Turkey

²Department of Pediatric surgery, Sağlık Bilimleri University, Umraniye SUAM Training and Research Hospital, Istanbul, Turkey

³Department of Dermatology, Sağlık Bilimleri University, Umraniye SUAM Training and Research Hospital, Istanbul, Turkey

The granular cell tumor is a common benign mesenchymal neoplasm originated from peripheral neural elements, particularly the Schwann cells. It is, therefore, strongly positive to S100 protein. In contrast to granular cell tumor, S-100 negative granular cell tumor (so-called primitive polypoid non-neural granular cell tumor) is a rare, subsequently identified diagnosis. To date, several cutaneous and only five oral cases of S-100 negative granular cell tumors have been published. However, no case of non-neural granular cell tumor with oral involvement of a newborn has been reported so far. Here, we describe the first reported case of a 'newborn' with oral S-100 negative granular cell tumor presenting with an oral mass at birth. Physical examination revealed a 2.2 x 2 x 1.7 cm mobile mass originating from the floor of the mouth and hanging out of the lips. Microscopic examination showed large polygonal cells with round, euchromatic nuclei and abundant eosinophilic granular cytoplasm. Immunohistochemical studies revealed positive staining for neuron-specific enolase, CD63 (NK1/C3) and CD68; but negative for S100 and desmin. Non-neural granular cell tumor is a diagnosis of exclusion based largely upon immunohistochemical findings. In the present case we describe the first report of a 'newborn' with oral non-neural granular cell tumor.

Keywords: Granular cell tumor, non-neural granular cell tumor, newborn

3rd INDERCOS

National Dermatology & Cosmetology Congress with International Participants

14-17 MARCH, 2018
HILTON ISTANBUL BOSPHORUS HOTEL
ISTANBUL, TURKEY



PP-056

[CONTACT AND OCCUPATIONAL DERMATITIS]

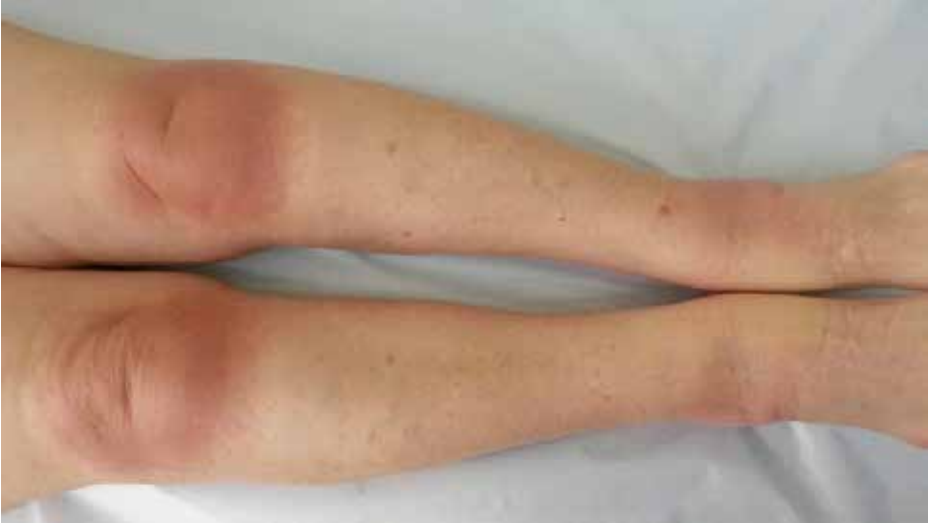A CASE OF ALLERGIC CONTACT DERMATITIS DUE TO MANDRAGORA RADIX

*Hilal Kaya Erdoğan, Nihan Yüksel Çanakçı, Ersoy Acer, Zeynep Nurhan Saraçoğlu
Eskişehir Osmangazi Üniversitesi, Deri ve Zührevi Hastalıkları Anabilim Dalı, Eskişehir*

Allergic contact dermatitis is a frequent eczematous skin disease usually caused by various allergens such as chemicals in the jewellery, personal care products, topical medications, plants and chemicals at work. Plants have been used to treat diseases for many years and they can cause allergic reactions. Mandragora species have sedative, aphrodisiac, emetic, analgesic, and anesthetic effects. To our knowledge only two cases have been previously reported. A 69 years old woman admitted to our clinic with redness and itching on her knees and ankles. She revealed that her complaints had started after the local application of Mandragora radix for few days (Figure 1). She used the radix to reduce the pain on her knees and ankles. Dermatological examination revealed irregular bordered, erythematous and edematous plaques on the knees and ankles (Figure 2). She was diagnosed with allergic contact dermatitis due to mandragora radix. We planned patch testing; but the patient refused the test. In addition to prevent re-exposure to suspicious allergic material, we treated patient with topical corticosteroids and oral antihistaminics. Lesions completely resolved within 3 days. Herein we present a 69 years old woman diagnosed with allergic contact dermatitis due to Mandragora Radix.

Keywords: Allergic Contact Dermatitis, Mandragora Radix, phytodermatitis

Figure 2



Resim 1





PP-057

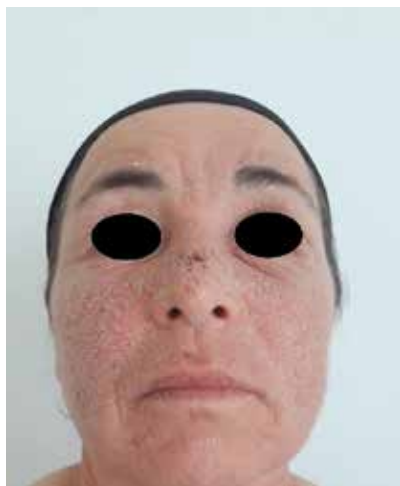**[ADVERSE DRUG REACTIONS, TEN]
DAPSONE HYPERSENSITIVITY SYNDROME**

Betül Şerefliçan, Tekden Karapınar, Gülden Konur, Serap Sertkaya, Ali Haydar Parlak
Department of Dermatology, Abant İzzet Baysal University Faculty of Medicine, Bolu, Turkey

Dapson (4,4'- diaminodiphenylsulfone) is a drug used in the treatment of various infectious, immunological and hypersensitivity disorders. Common side effects of this drug are dose-independent (idiosyncratic) skin hypersensitivity reactions and dose-related hemolytic anemia and methemoglobinemia. The dapson hypersensitivity reaction is characterized by fever, skin rash, eosinophilia, lymphadenopathy, hepatic, pulmonary and other systemic involvement and is a rare fatal reaction. A 51-year-old female patient with a diagnosis of cicatricial pemphigoid was treated with dapson for about 6 weeks. After treatment, eczematous lesions developed on the face and neck and elevation in liver function tests was detected (Figure 1-2). Dapson hypersensitivity syndrome can lead to irreversible multi-organ damage if it is not diagnosed early and it is a fatal side effect. The side effects of dapson should be kept in mind and clinicians should be careful in this regard.

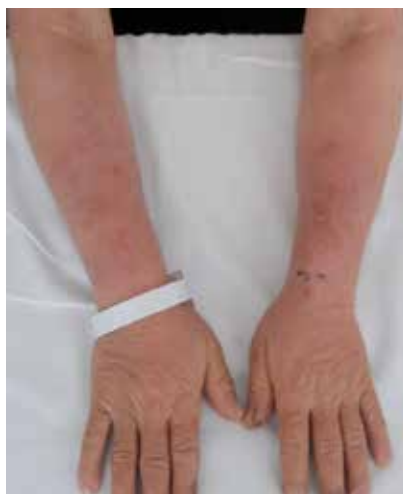Keywords: dapson, drug reaction, hypersensitivity syndrome

Figure 1



erythematous, eczematoid plaques on her face

Figure 2



erythematous, eczematoid plaques on dorsum of the hand



3rd INDERCOS

National Dermatology & Cosmetology Congress with International Participants

14-17 MARCH, 2018
HILTON ISTANBUL BOSPHORUS HOTEL
ISTANBUL, TURKEY

PP-058

[INHERITED SKIN DISEASES]

THE WITKOP SYNDROME: A CASE REPORT

Mualla Polat¹, Serap Sertkaya¹, Seval Bayrak², Tekden Karapınar¹

¹Department of Dermatology, Faculty of Medicine, Abant İzzet Baysal University, Bolu, Turkey

²Department of Oral and Maxillofacial Radiology, Abant İzzet Baysal University Faculty of Dentistry, Bolu, Turkey

INTRODUCTION: The Witkop syndrome was first reported by Carl Witkop in 1965, is a form of ectodermal dysplasia and also known as 'nail dysgenesis and hypodontia'. It is characterized by the absence or impaired function of two or more ectodermally derived structures such as teeth, hair, nails and glands. This rare genetic disorder is autosomal dominantly inherited.

CASE: A 30 year old female patient was referred to the AİBÜ Dentistry Faculty for the pain in her inferior jaw. In clinical examination, her lateral and canine teeth that were located upper jaw right and left region, were observed as milk teeth. In detailed examination, absence of bilateral lateral and canine teeth was detected and she was consulted to our Dermatology department. In dermatologic examination of the patient, koilonychia and hypoplasia in bilateral toenails, keratosis pilaris in bilateral upper extremities were detected. By these symptoms, the patient was diagnosed with Witkop syndrome.

DISCUSSION: We aimed to present this case whom was referred to us with tooth and nail dysgenesis and evaluated as Witkop syndrome while it was seen as a rare disorder in clinical practice.

Keywords: Witkop syndrome, teeth, hair, nail

3rd INDERCOS

National Dermatology & Cosmetology Congress with International Participants

14-17 MARCH, 2018
HILTON ISTANBUL BOSPHORUS HOTEL
ISTANBUL, TURKEY



PP-059

[AUTOIMMUNE CONNECTIVE TISSUE DISORDERS]

ERYTHEMA MULTIFORME AS A SUSPICION FOR DIAGNOSIS OF CONNECTIVE TISSUE DISEASE: ROWELL SYNDROME

Sümeyye Tanır, Recep Dursun, Arzu Ataseven, Ilkay Özer, Selami Aykut Temiz

Department of Dermatology, Necmettin Erbakan University Meram Faculty of Medicine, Konya, Turkey

A 20 year old female patient presented with multiple erythematous papules and plaques on the nose, cheeks and hands. The eruption had appeared on her nose first 3 months ago and then subsequently spread to her cheeks and hands. The lesions were persistent and not itchy. Some of the plaques have target like appearance. She has no history of any infectious disease or drug intake for a last few weeks and also no previous history of any chronic disease.

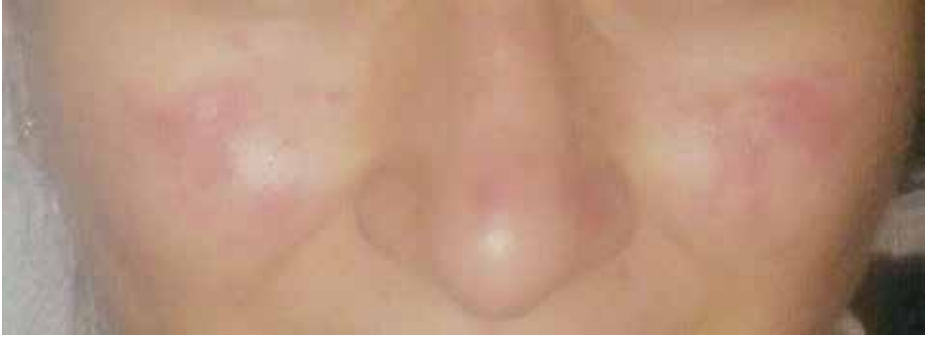Leucopenia and thrombocytopenia exist at complete blood count tests. When she was questioned about SLE symptoms, transient joint pains and recurrent oral ulcer complaints detected. Other laboratory findings showed that antinuclear antibody (ANA) was positive in granular pattern, anti-dsDNA, anti-Ro antibody anticardiolipin antibody, anti-SM/RNP, and anti-ribosomal-P protein were also positive. C3, C4 levels were low. ESR 9, CRP< 0,1, urinary examination, renal function tests and liver enzymes were normal. Rheumatoid factor was negative. Systemic lupus erythematosus (SLE) was diagnosed after rheumatology consultation. 5 mg/day prednisone and 400mg/day hydroxychloroquine treatment started for SLE. The lesions fade away within 1 month.

Rowell Syndrome is a rare coexistence of erythema multiforme and lupus erythematosus. This syndrome requires three major and at least one of three minor criterias for diagnose. Major criterias are: systemic, discoid, or subacute LE, EM-like lesions with or without mucosal involvement, and speckled pattern ANA; and three minor criterias are: chilblains, antiRo or antiLa antibodies, and positive rheumatoid factor. In this case we detected EM-like lesions, systemic lupus erythematosus, positive ANA and positive antiRo antibodies. According to these findings diagnostic criterias of Rowell syndrome has provided.

We called her as Rowell Syndrome but more importantly this rare coexistence brought a suspicion for systemic lupus erythematosus and helped us for early diagnose of this high morbid disease.

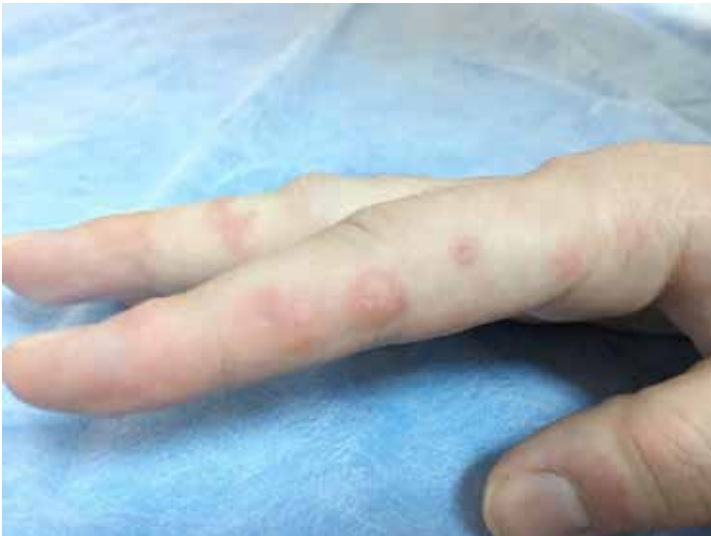Keywords: Erythema multiforme, systemic lupus erythematosus, rowell syndrome

Face lesions



Erythema multiforme lesions on the nose and cheeks

Hand lesions



Erythema Multiforme lesions on the hand

3rd INDERCOS

National Dermatology & Cosmetology Congress with International Participants

14-17 MARCH, 2018
HILTON ISTANBUL BOSPHORUS HOTEL
ISTANBUL, TURKEY



PP-060

[INHERITED SKIN DISEASES]

TUBEROUS SCLEROSIS COMPLEX ASSOCIATED WITH GIANT CELL ASTROCYTOMA: A CASE REPORT

Fatma Tunçez Akyürek¹, Nihal Sarı¹, Ebru Tunçez³, Gülcan Saylam Kurtipek¹, Zeliha Esin Çelik²

¹Department of Dermatology Selcuk University, Konya, Turkey

²Department of Pathology Selcuk University, Konya, Turkey

³Şanlıurfa Education and Research Hospital, Clinic of Medical Genetics, Şanlıurfa, Turkey

INTRODUCTION: Tuberous sclerosis complex (TSC) is an autosomal dominant transition disease that can affect many organs such as; skin, central nervous system, eye, kidney, heart, etc. Dermatological examination is important for diagnosis because the earliest symptoms of this rare disease are observed on skin. Diagnostic symptoms of this disease are hypopigmented macules (Ash leaf macules), angiofibroma on face skin, Shagreen patches (connective tissue nevus), fibrous plaque on forehead, and fibromas around the nail. In this report, a case with subependymal giant cell astrocytoma which diagnosed as TSC by cutaneous lesions is discussed.

CASE: A 16-year-old presented with hypopigmented leaf-shaped macula that has been present from birth on his left leg. There was a rough surface skin-colored plaque lesion formed on the right hip two weeks ago. He was operated due to subependymal giant cell astrocytoma at neurosurgical department about 1.5 years ago. An incisional biopsy specimen taken from the patient's right hip showed that hyperkeratosis in the epidermis and dense collagen bundles in the dermis. It was compatible with connective tissue nevus both clinically and histopathologically. According to neurological and cutaneous symptoms, the patient was followed up with TSC diagnosis.

CONCLUSION: Skin symptoms for TSC diagnosis are among the major diagnostic criteria and it is one of common symptoms in patients. The most common and earliest skin symptoms are hypopigmented macules. Oval, long or polygonal macules similar to the Ash-leaf macules are the most frequent macules at birth. Shagreen patches seen less frequently are connective tissue nevus. It is usually in the skin color of the lumbosacral region or in the form of slightly yellowish raised and rough surface plaques. Hypopigmented macules and Shagreen patches are not specific symptoms on their own, however together with other skin or systemic symptoms make TSC diagnosis. In conclusion, comprehensive dermatologic examination plays a key role for TSC diagnosis

Keywords: Ash-leaf macules, connective tissue nevus, giant cell astrocytoma, tuberous sclerosis complex,



3rd INDERCOS

National Dermatology & Cosmetology Congress with International Participants

14-17 MARCH, 2018
HILTON ISTANBUL BOSPHORUS HOTEL
ISTANBUL, TURKEY

PP-061

[INFLAMMATORY SKIN DISEASES]

A RARE ANNULAR LESION: ANNULAR ELASTOLYTIC GIANT CELL GRANULOMA

Özge Yöntem¹, Tülin Yüksel¹, Sinem Ayşe Örnek¹, Ömer Özdemir¹, Selver Özekinci², Özgür Emek Kocatürk Göncü¹

¹Department of Dermatology, Okmeydani Training and Research Hospital, Istanbul, Turkey

²Department of Pathology, Okmeydani Training and Research Hospital, Istanbul, Turkey

Annular elastolytic giant cell granuloma (AEDHG) is a rare disease that appears on sun-exposed areas (face, neck, hand, forearm dorsum, etc.), characterized by annular, erythematous by edges, centrally hypopigmented or atrophic plaques.

Histopathological findings include granulomatous reaction and elastofagocytosis that consist of multinuclear giant cells in which no mucin accumulation and necrobiosis accompany.

Herein, we present a 54-year-old female patient who had lesions that first appeared 7-8 months ago, localized on the forearm, erythematous, annular and clinicopathologically diagnosed with AEDHG.

Keywords: Annular elastolytic giant cell granuloma, elastophagocytosis, granulomatous disorder

3rd INDERCOS

National Dermatology & Cosmetology Congress with International Participants

14-17 MARCH, 2018
HILTON ISTANBUL BOSPHORUS HOTEL
ISTANBUL, TURKEY



PP-062

[PSORIASIS]

INCREASED SERUM LEVELS OF BISPHENOL A AND BETATROPHIN IN PATIENTS WITH PSORIASIS

Suzan Demir Pektas¹, Nigar Yilmaz², Ibrahim Kivrak³

¹Department of Dermatology, Mugla Sitki Kocman University, Faculty of Medicine, Mugla, Turkey

²Department of Biochemistry, Mugla Sitki Kocman University, Faculty of Medicine, Mugla

³Department of Chemistry and Chemical Treatment Techniques, Mugla Vocational School of Higher Education, Mugla Sitki Kocman University, Mugla, Turkey

INTRODUCTION: Psoriasis is a common and serious systemic inflammatory disease. The purpose of this study is to investigate the relationship between bisphenol A, betatrophin, urocortin 3 and vitamin D levels in patients with psoriasis.

MATERIAL-METHOD: Sixty patients with psoriasis (mean age, 34.1±9.6 years) and twenty six age- and gender-matched healthy individuals (mean age, 35.5 ±10.5 years) were included in this study. Bisphenol A, betatrophin, urocortin 3 and vitamin D levels were assessed by using enzyme-linked immunosorbent assay. Serum levels of bisphenol A were detected using UPLC-ESI-MS/MS.

RESULTS: In psoriasis patients, the median bisphenol A serum level was 0.537 ng/mL (range 1.1), and significantly lower compared to controls (median 0.2 range 0.9 ng/mL). Bisphenol A concentration (36.6%) was lower than 0.500 ng/mL in 22 patients. The median serum level of betatrophin was 270 (range 5834.7 ng/mL) in patients with psoriasis, and significantly different from the control group (median 198.7, range 198.2). The median serum level of urocortin 3 was 63.3 (range 129.1) in patients with psoriasis, and it was not significantly different compared to control group (median 27 range 537.9). The median serum level of vitamin D was 23.6 (range 377), and it was significantly lower than the control group (median 156.8 range 247.1). A positive correlation was found between serum bisphenol A and PASI scores in patients with psoriasis. Furthermore, urocortin positively correlated with the duration of illness. In ROC analysis, bisphenol A values greater than 0.764 predicted psoriasis with 88.3% sensitivity and 61.5% specificity. Betatrophin levels greater than 0.819 predicted psoriasis with 80% sensitivity and 69.2% specificity.

CONCLUSION: We have determined a relationship between bisphenol A, betatrophin and vitamin D levels in the inflammatory process in the pathophysiology of psoriasis. Bisphenol A and betatrophin may be predictive markers for presence of psoriasis and the disease severity.



3rd Indercos

National Dermatology & Cosmetology Congress with International Participants

14-17 MARCH, 2018
HILTON ISTANBUL BOSPHORUS HOTEL
ISTANBUL, TURKEY

Keywords: Psoriasis, bisphenol A, betatrophin, urocortin 3, vitamin D

PP-063

[ANGIOLOGY, HAEMANGIOMAS, VASCULAR MALFORMATIONS, VASCULITIS] GARDNER-DIAMOND SYNDROME IN CHILDHOOD: A CASE REPORT

Fatma Tunçöz Akyürek, Gülcan Saylam Kurtipek

Department of Dermatology Selcuk University, Konya, Turkey

INTRODUCTION: Gardner-Diamond syndrome is a condition that mostly affects young woman and characterized by recurrent, painful localized inflammation and ecchymoses. The syndrome, also known as psychogenic purpura or autoerythrocyte sensitization syndrome is a rare condition in which ecchymoses was the result of autosensitization to extravasated erythrocytes after tissue trauma. In some cases, episodes may also be accompanied by fever, arthralgia, myalgia, headache, and dizziness or gastrointestinal symptoms.

CASE: An 14-year-old girl presented with a seven-month history of recurrent episodes of painful ecchymotic lesions over the bilateral upper extremity. The lesions were sudden in onset, recurring every few weeks, and associated with arthralgia, myalgia, headache. The patient's major complaint was pruritus. No personal or family history of bleeding disorders or injury, self harm, insect bites, or use of drugs such as aspirin were reported. The patient had received antihistamines and topical corticosteroids without any benefit.

CONCLUSION: Pediatric cases of Gardner-Diamond syndrome may be confused with several disorders with dermatologic manifestations including idiopathic thrombocytopenic purpura, Henoch-Schonlein purpura, child abuse. Confirmation can therefore involve histories taken from family members, as well as consults involving psychiatry, dermatology and hematology.

Keywords: Autoerythrocyte sensitization syndrome, Gardner-Diamond syndrome, psychogenic purpura

3rd INDERCOS

National Dermatology & Cosmetology Congress with International Participants

14-17 MARCH, 2018
HILTON ISTANBUL BOSPHORUS HOTEL
ISTANBUL, TURKEY



PP-064

[INFLAMMATORY SKIN DISEASES]

DISSEMINATED SUPERFICIAL POROKERATOSIS: A CASE REPORT

Ceyda Çaytemel¹, Şenay Ağıröğl¹, Meltem Hüdaverdi¹, Kamile Altunda², Zafer Türkoğlu¹

¹Department of Dermatology, Haseki Research and Training Hospital, Istanbul, Turkey

²Department of Pathology, Haseki Research and Training Hospital, Istanbul, Turkey

Introduction & OBJECTIVES: Porokeratosis group diseases are keratinization disorders, characterized by hyperkeratotic bordered plaques, and cornoid lamella which are histopathologic hallmark. Disseminated superficial parakeratosis (DSP); is a relatively common subtype of porokeratosis. We consider it appropriate to present this case with reason for being rare in the practice of dermatology.

MATERIALS & METHODS: A 40-year-old male patient was admitted to our clinic with a multipl annular plaque lesions; 5-7mm in size, dark brown color, a hyperkeratotic ridge all around, and relatively atrophic in the middle, distributed on the trunk, arms and legs. On the biopsy specimen histopathologic examination revealed; parakeratotic columns and orthokeratosis and thinning the granular layer under parakeratosis areas was determined.

RESULTS: The patient was evaluated as DSP with clinical and histopathological findings. In contrast to disseminated superficial actinic keratosis, these patients are associated with immunosuppression (HIV, Hepatitis C, organ transplantations, malignancies, etc.) rather than UV exposure. In this respect, patients should be carefully screened and followed up. In particular, it is necessary to be more careful in sudden onset forms. We have not detected any pathology except mild liver enzyme elevation in our patient. Moisturizers, topical calcipotriol and oral retinoic acid may be effective in the treatment. We treat the patient with potent steroids.

CONCLUSIONS: Porokeratosis is a relatively rare disease characterized by keratinizing disorders. It is important for the prognosis of the patient to recognize and follow these patients as DSP can be seen to be related to immunosuppression that can be undergone. Long-term follow-up of these patients will provide information about etiology and prognosis.

Keywords: porokeratosis, disseminated, superficial



3rd INDERCOS

National Dermatology & Cosmetology Congress with International Participants

14-17 MARCH, 2018
HILTON ISTANBUL BOSPHORUS HOTEL
ISTANBUL, TURKEY

PP-065

[INFLAMMATORY SKIN DISEASES]

CASE REPORT: PENILE PYODERMA GANGRENOSUM

Emin Ozlu¹, Alpaslan Yukse², Yunus Ozcan¹, Mehmet Gamsızkan³, Ragıp Ertas⁴, Kemal Ozyurt⁴

¹Duzce University School of Medicine, Department of Dermatology, Duzce, Turkey

²Duzce University School of Medicine, Department of Urology, Duzce, Turkey

³Duzce University School of Medicine, Department of Pathology, Duzce, Turkey

⁴Kayseri Training and Research Hospital, Department of Dermatology, Kayseri, Turkey

INTRODUCTION: Pyoderma gangrenosum is an ulcerative skin disorder showing characteristic non-infectious ulcer. It usually affects female patients and occurs mostly on lower extremities. Pathogenesis is not clear. Immune complex-mediated neutrophilic vascular damage and impaired neutrophil phagocytosis play an important role. Approximately 50% of cases have an underlying comorbidity. In particular, patients should be investigated for inflammatory bowel diseases and rheumatoid arthritis. Treatment includes super potent topical corticosteroids, topical tacrolimus, topical pimecrolimus, systemic corticosteroids, cyclosporine, azathioprine, dapsone, thalidomide, cyclophosphamide, clofazimine, infliximab and adalimumab. Lesions heal with atrophy and scarring. To date, there have been a few cases of pyoderma gangrenosum on the penis.

CASE: A 74 years-old man presented with a round to oval, 3x2 cm, yellow to white ulcerative lesion on the dorsum of his penis. The surrounding area had a well demarcated purplish-erythematous plaque. The lesion appeared one month ago and associated with intense pain. In his medical history he had autoimmune thyroid disease. Laboratory and microbiological findings were unremarkable including tests for sexually transmitted infections. Based on the medical history, clinical, laboratory and histopathological findings, the patient was diagnosed with pyoderma gangrenosum of the penis. The patient was treated with topical clobetasol propionate % 0.05 and topical fusidic acid % 2 for one month. The ulcerated lesion completely regressed after one month.

CONCLUSION: This case has been reported due to having an unusual localization for pyoderma gangrenosum.

Keywords: Penis, pyoderma gangrenosum, ulcer.

3rd INDERCOS

National Dermatology & Cosmetology Congress with International Participants

14-17 MARCH, 2018
HILTON ISTANBUL BOSPHORUS HOTEL
ISTANBUL, TURKEY



PP-066

[INFLAMMATORY SKIN DISEASES]

DERMATOMIYOSITIS-LIKE LICHEN PLANUS WITH GOTTRON PAPULES

Handan Bilen¹, Mehmet Melikoğlu¹, Şevki Özdemir¹, Erdal Pala¹, Elif Demirci²

¹Ataturk University, Department of Dermatology, Erzurum, Turkey

²Ataturk University, Department of Pathology, Erzurum, Turkey

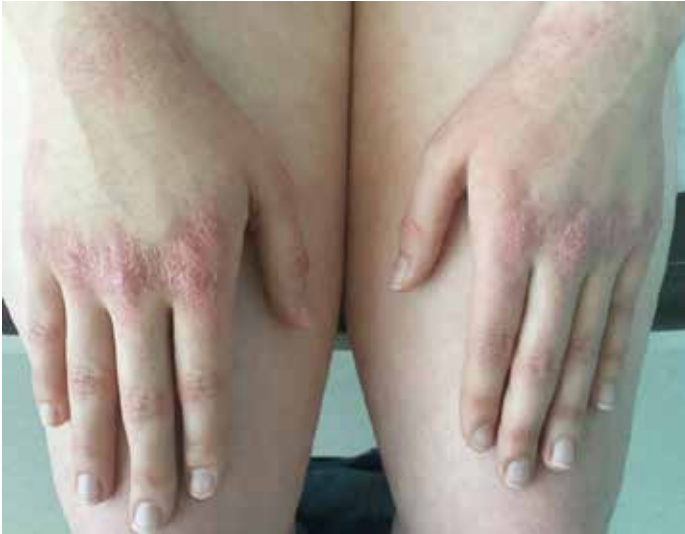INTRODUCTION: Dermatomyositis (DM) is an autoimmune disease that most often affects both the muscles and the skin (classic dermatomyositis), but also may occur in a skin-predominant form that termed as clinically amyopathic dermatomyositis. Heliotrope rash and Gottron papules are characteristic cutaneous lesions in DM. Lichen planus (LP) is an idiopathic inflammatory disease of the skin and mucous membranes whose primary lesion is a pruritic, violaceous papule, commonly located on the flexor wrists and forearms, the dorsal hands, the shins, and the presacral area. We present a case showing Gottron papule like skin changes, which are pathognomonic for DM, in LP located on extensory sites of hands and limbs with oral mucosal involvement.

CASE: A 20-year-old female patient presented with pruritic, erythematous, scaly plaques located on her trunk and limbs for about 12 years. Last 3 years erythematous, flat violaceous papules grew on the backs of her metacarpophalangeal joints (Figure 1), elbows and knees. She had a very subtle musculoskeletal pain. There were not any other characteristic lesions for DM. Oral mucosal lichenoid changes observed soon (Figure 2). Laboratory investigations showed that the serum levels of muscle enzymes were normal. Electromyography of the proximal muscles was also normal. Autoimmunity panel (anti-nuclear antibodies (ANA), extractable nuclear antigens (ENA), anti-double stranded DNA (anti-dsDNA), anti-Jo 1 antigens, cytoplasmic antineutrophil cytoplasmic antibodies (ANCA), perinuclear ANCA, rheumatoid factor (RF) showed no autoantibody. Biopsy specimen taken from the extensory site of third metacarpophalangeal joint was revealed hyperkeratosis, hypergranulosis and basal vacuolar changes (Figure 3). Based on clinical, histopathological and laboratory findings, LP was diagnosed.

CONCLUSION: Although Gottron papules are highly diagnostic skin lesion for DM, it may be seen alone in some other diseases like LP. If there are not any additional diagnostic criteria, except Gottron papule, for DM we should keep in our mind other skin diseases that are in the differential diagnosis of DM like LP, psoriasis, lupus erythematosus.

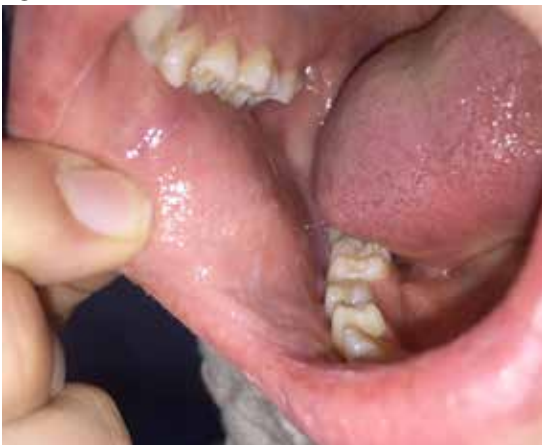Keywords: Gottron papule, dermatomyositis, lichen planus

Figure 1



Erythematous, flat violaceous papules on the backs of metacarpophalangeal joints

Figure 2



Oral mucosal lichenoid changes

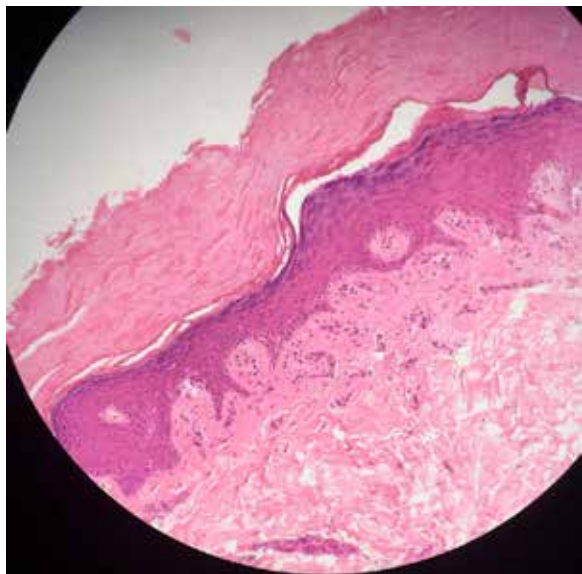
3rd INDERCOS

National Dermatology & Cosmetology Congress with International Participants

14-17 MARCH, 2018
HILTON ISTANBUL BOSPHORUS HOTEL
ISTANBUL, TURKEY



Figure 3



Hyperkeratosis, hypergranulosis and basal vacuolar changes

PP-067

[PSORIASIS]

TREATMENT RESISTANCE IMPETIGO HERPETIFORMIS: A CASE REPORT

Atiye Ogrum¹, Zennure Takcı¹, Havva Yıldız Seckin¹, Elif Cetin²

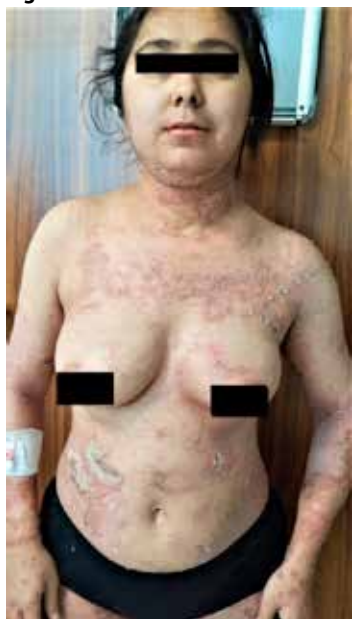¹Department of Dermatology and Venereology, Gaziosmanpaşa University, Tokat, Turkey

²Department of Pathology, Gaziosmanpaşa University, Tokat, Turkey

Impetigo herpetiformis is a rare disease of pregnancy with the onset beeing in the second half of pregnancy and resolution after delivery. It is associated with a high rate of perinatal mortality and fetal abnormalities. Clinical and histological features of the disease are consistent with pustuler psoriasis. We reported a case of 25-year-old female gravida 1 para 0, who responded poorly to treatments with systemic steroids, cyclosporine, intravenous immunoglobulin, and acitretin. Good response was obtained with adding infliximab to the therapy.

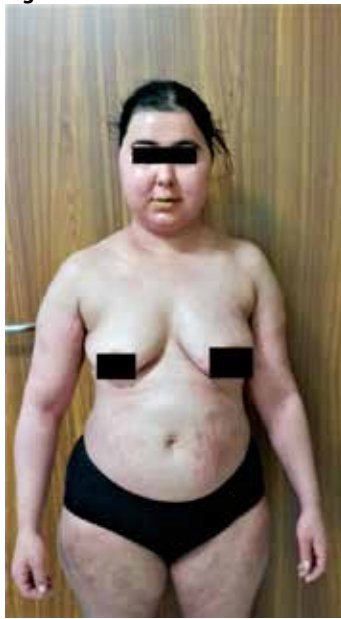Keywords: Impetigo herpetiformis, treatment, treatment resistance

Figure-1



Before treatment

Figure-2



After treatment

3rd INDERCOS

National Dermatology & Cosmetology Congress with International Participants

14-17 MARCH, 2018
HILTON ISTANBUL BOSPHORUS HOTEL
ISTANBUL, TURKEY



PP-068

[ACNE AND RELATED DISORDERS, HIDRADENITIS SUPPURATIVA]

DECREASED BILIRUBIN LEVELS IN PATIENT ISOTRETINOIN-TREATED ACNE WITH GILBERT SYNDROME

Gülcan Saylam Kurtipek, Nihal Köylü, Fatma Tunçez Akyürek

Department of Dermatology, Selçuk University, Faculty of Medicine, Konya, Turkey

The use of isotretinoin for the treatment of severe acne has been widely known over the past 30 years. Many adverse reactions to isotretinoin have been reported. Several studies have shown that hepatotoxicity could occur in about 10% and hyperlipidaemia in 20–45% of the patients. Gilbert's syndrome is a benign and inherited state characterised by intermittent unconjugated hyperbilirubinaemia with accompanying jaundice in the absence of haemolysis or underlying liver disease. Previous studies have shown that Gilbert's syndrome affects 5–7% of the population, mainly postpubertal male patients. Twenty-three years old male patient with Gilbert syndrome had moderate acne vulgaris. It has been started 20 mg/day isotretinoin for acne vulgaris. After one month it has been observed significant decreased the serum bilirubin levels according to starting level. In literature a recent study was observed decreasing bilirubin levels with Gilbert's syndrome patients. Similarly our case with Gilbert's syndrome isotretinoin-treated bilirubin levels showed substantial decrease over the four week follow-up, compared with the basal level.

Keywords: Bilirubin levels, Gilbert's syndrome, acne

PP-069

[DERMATOLOGICAL SURGERY]

RING-SHAPED DIGITAL BLOCK ANESTHESIA IN NAIL SURGERY

Hasan Mete Aksoy¹, Berna Aksoy²

¹Bahcesehir University, Faculty of Medicine, Department of Plastic and Reconstructive Surgery, Istanbul; VM Medicalpark Hospital, Plastic and Reconstructive Surgery Clinic, Kocaeli, Turkey

²Bahcesehir University, Faculty of Medicine, Department of Dermatology, Istanbul; VM Medicalpark Hospital, Dermatology Clinic, Kocaeli, Turkey

Nail surgery is a procedure that causes serious pain. For this reason, it is very important to provide efficient anesthesia. A ring-shaped digital block anesthesia that is frequently used in nail surgery is a safe and effective method of block anesthesia when properly applied. In this anesthesia method, both digital and volar nerve pairs are blocked and digital marker signals are not lost. In this presentation, the application of the ring-shaped digital block anesthesia method used in nail surgery is shown by the help of clinical photographs.

Keywords: anesthesia, nail, surgery

PP-070

[INFECTIOUS DISEASES, PARASITIC DISEASES, INFESTATIONS] TUBERCULOSIS VERRUCOSA CUTIS

Özgür Gündüz, Gülşah Koçak

Department of Dermatology, Kırıkkale University, Kırıkkale, Turkey

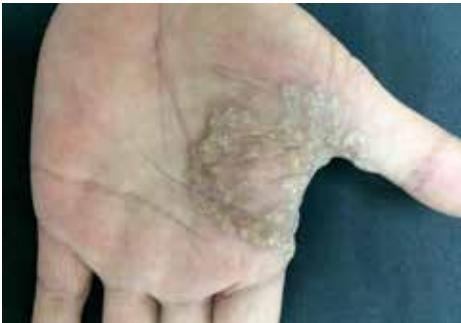INTRODUCTION: About 1/3rd of the world's population is infected with pathogenic mycobacteria that are established as etiologic factors for tuberculosis. According to the incidence rates, countries are divided into "high-incidence" (i.e. China, India) and "low-incidence" countries (i.e. US, Germany). Due to increase of international migration, the low-incidence countries may have to face an ever-increasing Tbc-burden.

CASE: A 65-year-old male patient with presented with an asymptomatic verrucous plaque on his left hand. His medical history was unremarkable. A purplish verrucous plaque was observed on his left hand, extending laterally from thenar eminence to the dorsum of the hand (Figure 1). The plaque had occurred about 3 years ago and slowly progressed. A skin biopsy revealed epidermal hyperplasia and dermal noncaseous granulomatous reaction. Tuberculin skin test was positive. Chest radiography showed no abnormalities. *M.bovis* was cultured from the biopsy specimen. Further diagnostic procedures revealed no other systemic involvement. Cryotherapy was started for the treatment of the cutaneous lesions.

CONCLUSION: Although cutaneous Tbc have been accepted as a relatively rare disease (and usually seen in high-incidence countries), its incidence may increase even in the low-burden countries in the near future. We present this case aiming to increase the awareness for the cutaneous Tbc.

Keywords: tuberculosis, granulomatous reaction, cryotherapy

Figure 1



Asymptomatic verrucous plaque on the left palmar surface

3rd INDERCOS

National Dermatology & Cosmetology Congress with International Participants

14-17 MARCH, 2018
HILTON ISTANBUL BOSPHORUS HOTEL
ISTANBUL, TURKEY



PP-071

[MISCELLANEOUS]

DISSEMINATED SUPERFICIAL ACTINIC POROKERATOSIS:CASE REPORT

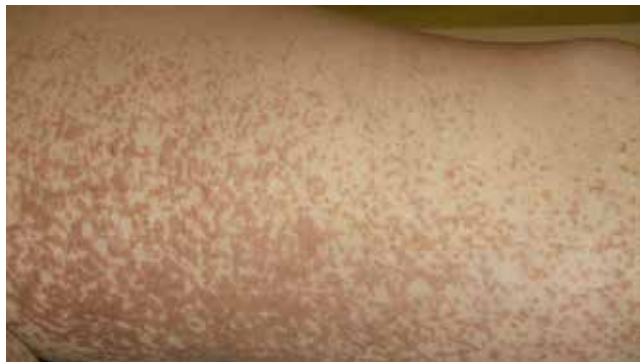Mustafa Anıl Yılmaz, Büşra Altun Deniz, Tamer Irfan Kaya, Ümit Türsen

Department of Dermatology,Mersin University,Mersin,Turkey

Disseminated superficial actinic porokeratosis (DSAP) is the most common type of porokeratosis. Lesions tend to be multiple, superficial, skin-coloured to light-brown, annular patches with an elevated ridge, located on the extensor surfaces of legs and arms.¹ Malignant transformation of porokeratosis into squamous cell carcinomas has been found in all forms of porokeratosis. Patients with large lesions, those of long-standing duration, and the linear type have a higher risk these patients should be successfully treated and closely monitored.² There were no randomized controlled trials on the treatment of PK, but mainly case reports and case series. Topical vitamin D acid derivatives may be the best therapeutic option for disseminated PK. Surgical interventions and cryotherapy may be preferred in areas where the use of topical agents is difficult or contraindicated.³ We present the case of an 58 year old female patient, who was presented to the dermatology clinic with erythematous rounded lesions disseminated on her legs accompanied by moderate itching of approximately 6 month duration. we took an incisional biopsy. biopsy revealed a keratin-filled epidermal invagination with a parakeratotic column cornoid lamella, and a mononuclear inflammatory infiltrate in the papillary dermis consistent with porokeratosis. We have been applying cryotherapy to right lower extremity and topical calcipotriol, diclofenac, 5-fluorouracil combined therapy to left lower extremity twice a day for four weeks. we aimed to present this case because of rarity and assesment affect of treatment modalities on our patient.

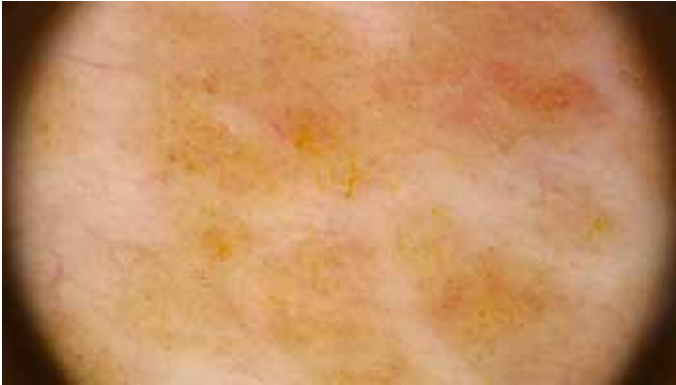Keywords: Disseminated superficial actinic porokeratosis, keratinization disorders, DSAP,

closer inspeciton of left thigh skin



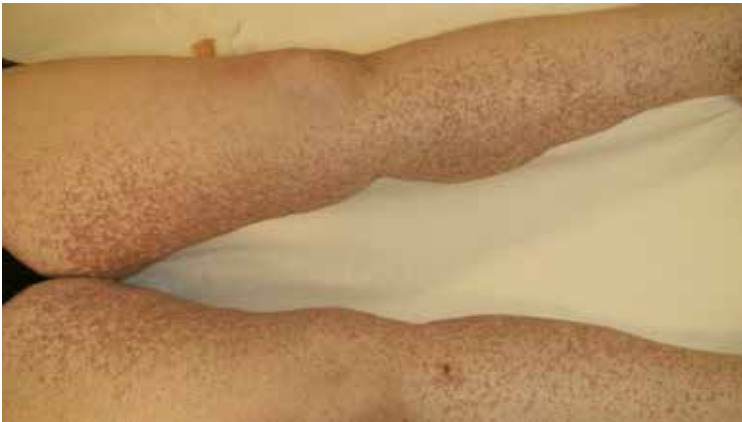multiple, superficial, skin-coloured to light-brown, annular patches with an elevated ridge, located on the extensor surfaces of legs

dermoscopy of superficial porokeratozis



central atrophy and an annular border with scales

gross inspection of lower extremities



multiple, superficial, skin-coloured to light-brown, annular patches with an elevated ridge, located on the extensor surfaces of legs

3rd INDERCOS

National Dermatology & Cosmetology Congress with International Participants

14-17 MARCH, 2018
HILTON ISTANBUL BOSPHORUS HOTEL
ISTANBUL, TURKEY



PP-072

[MISCELLANEOUS]

RESOLUTION OF GENERALIZED ANNULAR ELASTOLYTIC GIANT CELL GRANULOMA LESIONS AFTER BIOPSY

Ilkin Zindanci¹, Fatıma Gürsoy², Melike Kibar Ozturk¹, Ebru Zemheri²

¹Department of Dermatology, Sağlık Bilimleri University, Umranıye SUAM Training and Research Hospital, Istanbul, Turkey

²Department of Pathology, Sağlık Bilimleri University, Umranıye SUAM Training and Research Hospital, Istanbul, Turkey

Annular elastolytic giant cell granuloma (AEGCG) is considered a distinct entity characterized by appearance of annular erythematous to skin-colored lesions preferentially on sun-exposed areas. Histopathologically with a granulomatous reaction with elastolysis, phagocytosis of the elastic fibers, and multinucleate giant cells with absence or reduction of elastin fibers. Histopathological hallmarks also include absence of collagen necrobiosis or mucin deposition. AEGCG and granuloma annulare (GA) often have similar clinical appearance. The diagnosis is made histopathologically. Similar treatments can be used in both. Resolution of granuloma annulare after various forms of trauma, including biopsy, is a wellknown and controversial phenomenon in the dermatologic literature. But there is a few knowledge about AEGCG and healing after biopsy. We want to present a 55 years old female patient with generalized AEGCG whose lesions resolved 3 weeks after biopsy.

Keywords: Annular elastolytic giant cell granuloma, biopsy, granuloma annulare



3rd INDERCOS

National Dermatology & Cosmetology Congress with International Participants

14-17 MARCH, 2018
HILTON ISTANBUL BOSPHORUS HOTEL
ISTANBUL, TURKEY

PP-073

[ALLERGOLOGY AND IMMUNOLOGY]

A CASE OF DYSHIDROSIS FOLLOWING ORF INFECTION

Zerrin Ogretmen, Alper Ekinci

Faculty of Medicine, Department of Dermatology and Venerology, Çanakkale Onsekiz Mart University, Turkey

INTRODUCTION: Orf (Ecthyma contagiosum) is a zoonotic infection which is caused by Parapoxvirus which is transmitted to human via sheep. There are a lot of reported complications following orf infection such as fever, lymphangitis etc.. There is no report regarding dyshidrosiform vesicles as an id reaction following orf infection. The case of linear dyshidrosiform vesicles occurred 2 weeks later than orf infection of hand is reported as an interesting case.

CASE: 15 year old woman had applied to our clinic with the complaints of a nodular lesion with intense colour on the middle finger of her left hand and little vesicles filled with fluid surrounding the nodular lesion. The intense coloured nodular lesion had occurred 15 days ago and the surrounding vesicles had appeared 1 days ago. For her nodular lesion, wound care with topical antibiotic had been launched by her physician. Her medical history and her family's medical history had no relevant finding. Dermatological examination revealed a bulky, 1.4 cm sized nodular lesion covered by hemorrhagic crust on the middle finger of her left hand. Also, dyshidrosiform vesicles spreading in a linear manner from the adjacent of the orf lesion along the arm had been detected. These vesicles were more on the dorsum of the hand and getting lesser on the proximal of the arm. There was no skin punch biopsy material obtained because of the patient's withdrawal but the dyshidrosiform appearance of the vesicles was so typical. Remainder of the systemic examination was completely normal. There was no pathological finding in her laboratory tests.

DISCUSSION: There are various complications following orf infection such as fever, lymphangitis, secondary infection, erythema polymorphe. Besides, there are case reports regarding otoimmun bullous disease following orf infection in the literature. One of our case was also bullous pemphigoid following orf infection. But, in this current case, lesions were dyshidrosiform vesicles as an id reaction following orf infection. There is no case report regarding dyshidrosis following orf infection in the literature. Thus, our case is reported as an interesting case.

Keywords: orf infection, dyshidrosis, otoimmun bullous disease

3rd INDERCOS

National Dermatology & Cosmetology Congress with International Participants

14-17 MARCH, 2018
HILTON ISTANBUL BOSPHORUS HOTEL
ISTANBUL, TURKEY



Figure 1

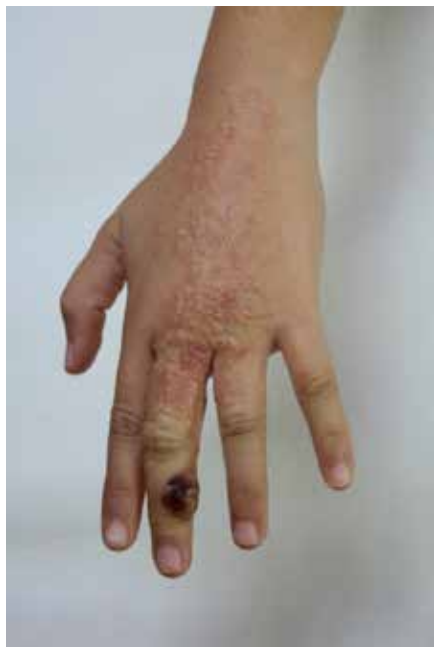
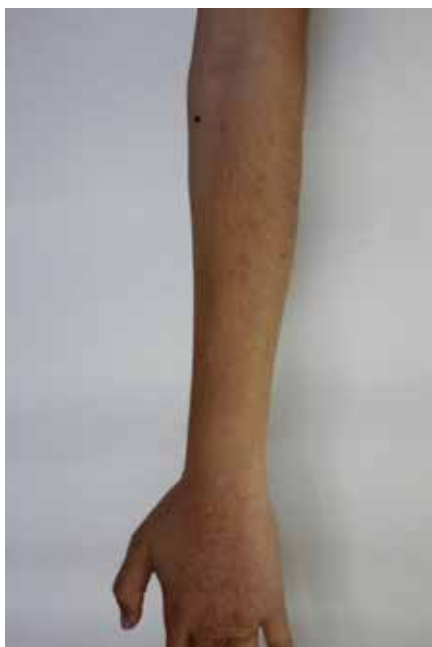
Figure 2





3rd INDERCOS

National Dermatology & Cosmetology Congress with International Participants

14-17 MARCH, 2018
HILTON ISTANBUL BOSPHORUS HOTEL
ISTANBUL, TURKEY

PP-074

[PAEDIATRIC DERMATOLOGY]

MILIUM OF THE NIPPLE: A RARE DIAGNOSIS

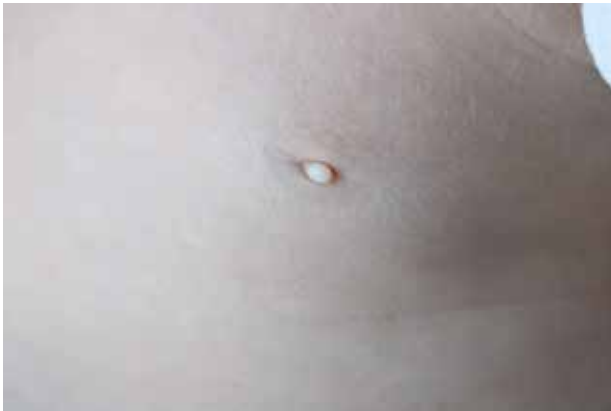Burçe Can Kuru¹, Ilkin Zindancı²

¹Department of Dermatology, Istanbul Medeniyet University, Göztepe Training and Research Hospital, Istanbul, Turkey

²Department of Dermatology, Umraniye Training and Research Hospital, Istanbul, Turkey

Milia commonly occur on the face of newborns. They result from retention of keratin within the dermis. They appear as tiny 1-2 mm pearly white or yellow papules. Milia may be primary or secondary. Primary milia may be congenital or have onset later in life and disappear spontaneously. Secondary milia arise after prolonged trauma or other injuries to the skin at places with a predisposing condition or some chronic medications. Lesions most commonly occur on the cheeks, nose, chin, and rarely seen on the nipple. Here we report a 20 month-old-girl clinically diagnosed as milia on the nipple.

Keywords: milia, cyst, nipple



pearly white lesion on the left nipple



PP-075

[DERMATOPATHOLOGY]

ECCRINE ANGIOMATOUS HAMARTOMA, PRESENTATION OF A RARE CASE

Ebru Zemheri¹, Merve Aydemir¹, Ilkin Zindanci², Melike Kibar Ozturk², Aypinar Kolay²

¹Department of Pathology Sağlık Bilimleri University, Umraniye SUAM Training and Research Hospital, Istanbul, Turkey

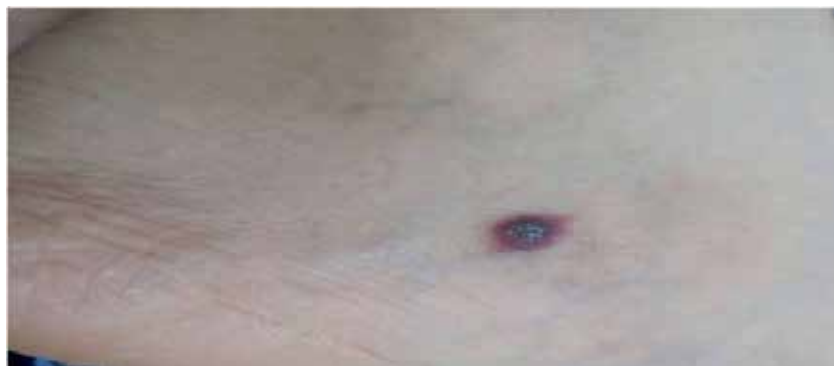²Department of Dermatology, Sağlık Bilimleri University, Umraniye SUAM Training and Research Hospital, Istanbul, Turkey

A 17-year-old female patient was admitted to our clinic due to the lesion that was present in the left medial region of the foot. There was no subjective complaint. On the dermatological examination, 0.5 cm diameter sized purple papulonodular lesion surrounded by livid erythema was seen. The histopathological examination of the total lesion, intense capillary proliferation was observed around the superficial middle dermis and around the cardinal glands. Immunohistochemically, vascular structures were CD31 and GLUT1 positive. Eccrine Angiomatous Hamartoma (EAH) was diagnosed in the lesion.

EAH is a rare, benign nodular lesion characterized by the proliferation of vascular and eccrine structures. It is rarely seen in congenital or childhood. Pain and hyperhidrosis may accompany. It should be considered in differential diagnosis of nonspecific livid-purple papulonodular lesion, particularly in childhood and adolescence. We want to present our case because of rarity.

Keywords: eccrine angiomatous hamartoma, histopathology, vascular, eccrine

Figure 1



Clinical appearance of the lesion



3rd INDERCOS

National Dermatology & Cosmetology Congress with International Participants

14-17 MARCH, 2018
HILTON ISTANBUL BOSPHORUS HOTEL
ISTANBUL, TURKEY

PP-076

[PHARMACOLOGY AND SKIN-RELATED TOXICOLOGY, PHLEBOLOGY]

A RARE SIDE EFFECT OF TERBINAFINE: SMELL SENSATION LOSS

Mualla Polat¹, Tekden Karapınar¹, Tuna Sezer², Yusuf Özgür Biçer³, Özge Uzun⁴

¹Department of Dermatology, Faculty of Medicine, Abant İzzet Baysal University, Bolu, Turkey

²Department of Dermatology, İzzet Baysal State Hospital, Bolu, Turkey

³Department of Otolaryngology, Faculty of Medicine, Abant İzzet Baysal University, Bolu, Turkey

⁴Department of Pharmacology, Faculty of Medicine, Abant İzzet Baysal University, Bolu, Turkey

INTRODUCTION: Terbinafine is an antifungal drug from the allylamine group that is widely used in the treatment of onychomycosis. Common side effects include nausea, abdominal pain and allergic skin reactions. It has been reported in the literature that this commonly used drug has 0.6-2.8% change in taste sensation. However, the effect on the sense of smell was not emphasized as much as the taste sensation.

CASE: A 52-year-old male patient admitted to our clinic due to a loss of sense of smell after using terbinafine tablets one month ago due to onychomycosis. Patient assessed by us and was consulted for otorhinolaryngologic disease. The patient, who was examined by otorhinolaryngologic diseases, and was found to have 100% sense of smell loss. No other pathology was found to cause olfactory sensation loss and it was thought to be related to the drug. It was decided to stop the medicine. Although terbinafine therapy has been discontinued, there was no improvement in smell sensation over 4 months.

DISCUSSION: It has been reported that permanent or temporary sense of smell loss may occur due to many drugs such as amiodarone, ACE inhibitors, anesthetics, betamethasone, calcium channel blockers, cocaine, doxycycline, class of antibiotics of floccinolone, methotrexate, interferon. There are very few case reports in the literature with sense of smell loss due to terbinafine. We present a case report of terbinafine, a commonly used drug in dermatology clinics, to show this rare side effect.

Keywords: Side Effect, Terbinafine, Smell Loss

PP-077

[MISCELLANEOUS]

AN UNUSUAL GIANT CALCINOSIS CUTIS OF SCROTUM; A CASE REPORT

Ilkin Zindanci¹, Ebru Zemheri², Elif Yılmaz³, Melike Kibar Öztürk¹

¹Department of Dermatology, Sağlık Bilimleri University, Umraniye SUAM Training and Research Hospital, Istanbul, Turkey

²Department of Pathology, Sağlık Bilimleri University, Umraniye SUAM Training and Research Hospital, Istanbul, Turkey

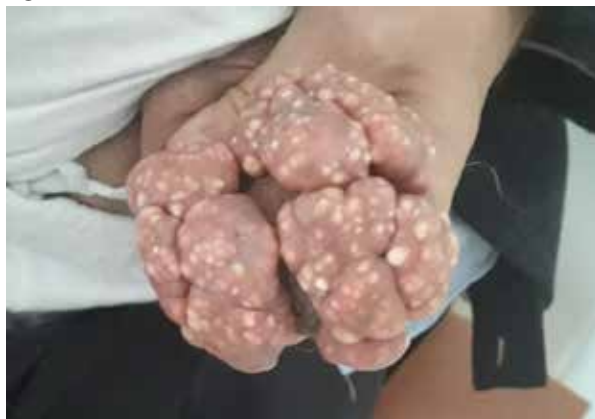³Department of Plastic and Reconstructive Surgery, Sağlık Bilimleri University, Umraniye SUAM Training and Research Hospital, Istanbul, Turkey

Idiopathic scrotal calcinosis is a rare and benign condition characterized by multiple calcific deposits occurring in scrotum and formed as nodules and lumps within scrotal skin. Clinically, it consists of hard, yellowish nodules within the dermis of scrotal skin. Nodules vary in size and number (solitary or multiple). The nodules are usually asymptomatic and patients seek medical advice mainly for cosmetic reasons. Histological examination shows calcium deposits with in the dermis that may be surrounded with histiocytes and an inflammatory giant cell reaction.

We report the case of 59-year-old man with an unusual massive lesions for 20 years. Treatment was surgical with complete excision of the affected part of the scrotum wall.

Keywords: Calcinosis cutis, scrotum, histopathology

Figure 1



Clinical appearance of the case



3rd INDERCOS

National Dermatology & Cosmetology Congress with International Participants

14-17 MARCH, 2018
HILTON ISTANBUL BOSPHORUS HOTEL
ISTANBUL, TURKEY

PP-078

[WOUNDS, CHRONIC WOUNDS, WOUND HEALING, ULCER] AN ULCERATIVE LESION ON THE LEG OF AN EIGHT YEARS OLD GIRL

Irem Mantar¹, Gülbahar Saraç¹, Hülya Cenk², Serpil Şener¹, Yelda Kapıcıoğlu¹

¹Department of Dermatology, Inonu University, Malatya, Turkey

²Department of Dermatology, Sorgun State hospital, Yozgat, Turkey

INTRODUCTION: Necrobiosis lipoidica (NL) is a chronic granulomatous inflammatory skin disease of unknown origin. It's associated with diabetes mellitus and glucose intolerance. 25% of the patients may have ulcerated lesions. It usually begins in the third or fourth decade of life. There are few reported pediatric cases of ulcerated necrobiosis lipoidica associated with type-1 diabetes mellitus (DM). Here in this case, an eight years old girl who had been diagnosed with NL before she was diagnosed with diabetes mellitus will be presented.

CASE: An eight years old girl has been consulted to our clinic due to an ulcerative lesion on her ankle for six months. There was a 9x9 cm sized, ulcerated and hemorrhagic-crusted plaque on an erythematous basis on her right ankle (Figure 1). The histopathologic assessment revealed necrobiotic collagen, mucin accumulation and histiocytic cell proliferation around. After two months of treatment with a cicatrisant magistral and topical tacrolimus 0.1 % twice a day, the lesion has shown regression (Figure 2).

DISCUSSION: There are few pediatric case reports of NL, some of these are as follows: a 16 years old girl, a 14 years old boy and a 17 years old girl who have had underlying DM, respectively for 15 years, 9 years and 2,5 years. Considering these cases, all of them have had underlying type-1 DM for years. Our case was diagnosed with NL before the diagnosis of DM and to our knowledge, she is the youngest pediatric case reported in the literature. Necrobiosis lipoidica is typically seen on the lower extremity as erythematous plaques and it slowly turns into yellowish atrophic plaques. Without a treatment, it may show ulceration over the time and rarely squamous cell carcinoma development may be encountered on the lesion. There are two main theories of NL etiopathogenesis including microangiopathy and immunologic vasculitis. Degeneration of collagenous tissue due to microangiopathy may lead to granulomatous reaction in the dermis. Although there are various agents for the treatment of NL, our knowledge on treatment is limited to the reported case series. Tacrolimus prevents granulomatous reaction and ulceration by inhibiting the fusion of monocytes to form multinucleated giant cells.

CONCLUSION: Necrobiosis lipoidica mostly develops in the patients who are in their middle ages and have DM for a long time. Especially in patients who have a familial history of DM, it must be kept in mind that ulcerated NL lesions may be seen even in early childhood.

Keywords: Necrobiosis lipoidica, ulcer, child, topical tacrolimus

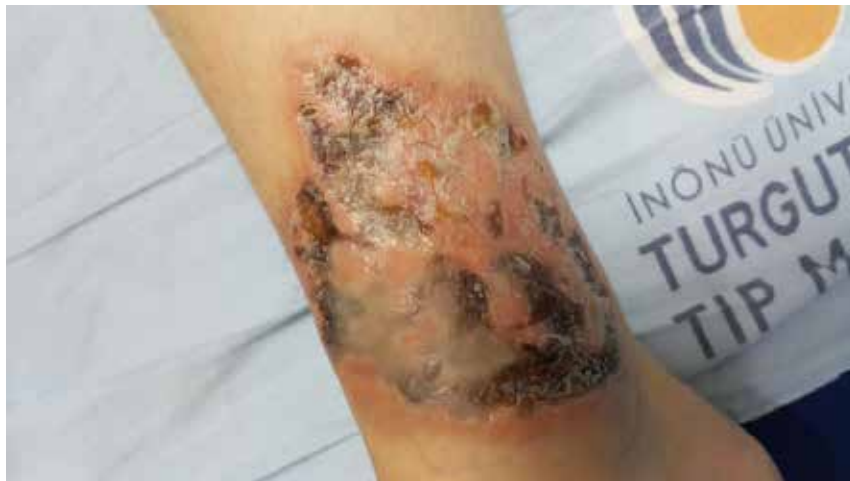3rd INDERCOS

National Dermatology & Cosmetology Congress with International Participants

14-17 MARCH, 2018
HILTON ISTANBUL BOSPHORUS HOTEL
ISTANBUL, TURKEY

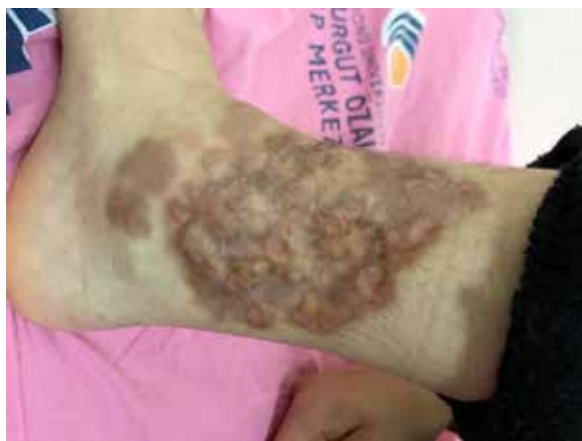

Figure 1



ulcerated and hemorrhagic-crust plaque on an erythematous basis on her right ankle

Figure



after topical tacrolimus treatment



3rd INDERCOS

National Dermatology & Cosmetology Congress with International Participants

14-17 MARCH, 2018
HILTON ISTANBUL BOSPHORUS HOTEL
ISTANBUL, TURKEY

PP-079

[INFECTIOUS DISEASES, PARASITIC DISEASES, INFESTATIONS]

"IDENTIFICATION OF INTERTRIGINOUS MYCOTIC AND PSEUDOMYCOTIC (ERYTHRASMA) INFECTIONS AND THEIR CAUSATIVE AGENTS WITH EMPHASIZE ON CLINICAL PRESENTATIONS"

Roshanak Daie Ghazvini, Samaneh Halvaei

Department of Medical Parasitology and Mycology, School of Public Health, Tehran University of Medical Sciences, Tehran, Iran

BACKGROUND: Intertrigo is an erythematous inflammatory condition with multiple etiologies including fungi and bacteria. Intertrigo manifests in different clinical forms with various complaints. This study was conducted to evaluate the causative agents of intertriginous infections with emphasize on clinical presentations.

METHODS: This descriptive cross-sectional study was carried out in a two year period (2015-2016) on 188 patients with clinical suspicion of superficial and cutaneous intertriginous infections in Tehran, Iran. Demographic and additional related data were obtained by questionnaire from all participants. Specimens were collected by gentle scraping of the affected areas. Direct examination and culture were performed for all specimens and grown colonies were identified based on the macroscopic and microscopic features. Supplementary tests were done whenever needed. Data were analyzed in SPSS.

RESULTS: Among 188 patients, 80 (42.5%) cases with the mean age of 43.5 years were confirmed for intertrigo. Dermatophytosis was the predominant cause in this study with 36 (45%) cases followed by erythrasma (28 cases, 35%), tinea versicolor (10 cases, 12.5%) and candidiasis (6 cases, 7.5%). Intertrigo lesions with *dermatophytic agents* significantly were observed in groin in comparison to different infections among body sites ($P < 0.05$). Itching was the most common clinical presentation (57 cases, 71.3%) and also significant association between different infections and clinical manifestations were observed (P values < 0.05).

CONCLUSION: Different clinical manifestations may be observed in infectious intertrigo. Regarding the significant association observed in this study, some clinical features can be used for presumptive diagnosis of diseases but further studies are required to make it clear.

Keywords: Intertrigo, Tinea, Candidiasis, Erythrasma, Signs and symptoms

3rd INDERCOS

National Dermatology & Cosmetology Congress with International Participants

14-17 MARCH, 2018
HILTON ISTANBUL BOSPHORUS HOTEL
ISTANBUL, TURKEY



PP-080

[PHARMACOLOGY AND SKIN-RELATED TOXICOLOGY, PHLEBOLOGY]

A CASE OF DRESS SYNDROME THAT PRESENTS WITH PITYRIASIS ROSEA-LIKE RASH

Mualla Polat¹, Gülden Konur¹, Selma Erdoğan Düzcü², Tekden Karapınar¹

¹Department of Dermatology, Faculty of Medicine, Abant İzzet Baysal University, Bolu, Turkey

²Department of Pathology, Faculty of Medicine, Abant İzzet Baysal University, Bolu, Turkey

INTRODUCTION: Dress syndrome is a rare but life threatening acute hypersensitivity reaction induced by drugs. Characteristic features of this syndrome include fever, maculopapular rash, lymphadenopathy, blood count abnormalities and visceral organ involvement. It is difficult to diagnose since its clinical findings could mimic the clinical features of other systemic diseases. Aromatic anticonvulsants, sulfonamides, allopurinol, dapsone, minocycline and vancomycin are the agents that are most commonly related with the development of DRESS syndrome. Symptoms develop 2-6 weeks after drug ingestion.

CASE: A 74 year old male patient presented to our clinic with the complaint of rash on his trunk. It was learned that the patient had rash on the 20th day of his allopurinol treatment that was initiated for the diagnosis of gout. During the dermatologic examination there were erythematous plaques with a collarlet of fine scale on some areas of the trunk. The result of the biopsy was reported as compatible with Pityriasis rosea. In his follow-up, the patient's condition deteriorated. Because of the development of widespread erythema on the whole body, maculopapular rash, fever, facial edema, impaired liver function tests, eosinophilia and leukocytosis, it was diagnosed as "DRESS syndrome induced with allopurinol".

DISCUSSION: Pityriasis rosea may develop as a drug related rash. The clinical appearance of our case initiated with the features of drug eruption resembling Pityriasis rosea and then intensified and systemic findings were added. For this reason, even if all findings are not present at presentation, the patients with the history of taking suspicious drugs should be evaluated with attention dealing with the risk of developing DRESS syndrome and it must be kept in mind that DRESS syndrome can come out with different types of rashes.

Keywords: DRESS Syndrome, Pityriasis Rosea, Allopurinol

PP-081

[INFECTIOUS DISEASES, PARASITIC DISEASES, INFESTATIONS]

MOLLUSCUM CONTAGIOSUM AFTER NOSE PIERCING "HIZMA": A CASE REPORT

Fatma Tunçöz Akyürek, Gülcan Saylam Kurtipek

Department of Dermatology Selçuk University, Konya, Turkey

Piercing can be performed at different sites on the body areas as the helix (ear), eyebrows, nose, lips, tongue, chin, nipples and navel. Most body piercing jewelry is made of metal, usually stainless steel, gold, niobium, titanium, or alloys. Hizma is popular among Anatolian women that is the application of nose piercing. The application of body piercing is observed to cause complications such as infections, pain, bleeding, hematoma formation, cyst formation, allergic reaction, hypertrophic scarring, and keloid formation. Herein, we describe Molluscum contagiosum as an uncommon complication of Hizma.

Keywords: Hizma, Molluscum contagiosum, piercing



3rd INDERCOS

National Dermatology & Cosmetology Congress with International Participants

14-17 MARCH, 2018
HILTON ISTANBUL BOSPHORUS HOTEL
ISTANBUL, TURKEY

PP-082

[CUTANEOUS ONCOLOGY]

A CASE OF BOWENOID ACTINIC KERATOSIS

Büşra Aydın¹, Berna Solak¹, Çiğdem Berna Çetin²

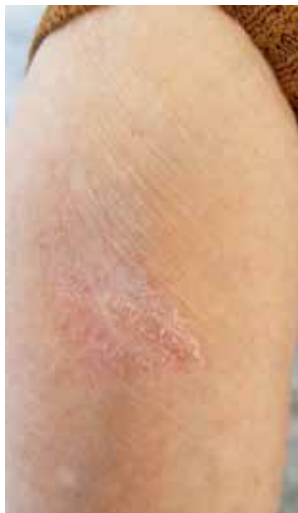¹Department of Dermatology, Sakarya University Training and Research Hospital, Sakarya, Turkey

²Department of Pathology, Sakarya University Training and Research Hospital, Sakarya, Turkey

A 75 years old female patient presented with an erythematous patch, which had been present for one year. On dermatological examination, there was an erythematous, sharp-edged plaque measuring 3x4 cm on the dorsal aspect of right forearm (Figure 1). There were not any subjective symptoms related to the lesion such as itching. Skin biopsies of the lesions revealed hyperkeratosis with dysplasia of the basal keratinocytes, as well as full thickness squamous atypia in two areas, and solar elastosis (Figure 2). On immunohistochemical staining, p53 (Figure 3) and ki-67 (Figure 4) expression were positive for atypical keratinocytes. Actinic keratosis is a common skin lesion that scaly, erythematous papule or plaque, associated with prolonged sun exposure, mostly seen in elderly patients. Due to its pre-neoplastic nature, early diagnosis and treatment of actinic keratosis is of great importance. There are five histological types of actinic keratosis as follows: hypertrophic, atrophic, bowenoid, acantholytic and pigmented. Unlike other types, full-thickness dysplasia is seen in bowenoid actinic keratoses and may be referred to as in situ squamous cell carcinoma. Bowenoid actinic keratosis is histologically indistinguishable from Bowen's disease, and may be considered severe actinic keratosis. Marked irregularity in the nucleus of the epidermis, coarsening of the nucleus, and dyskeratosis are seen in both conditions. Nevertheless, bowenoid actinic keratosis has solar damage in the dermis, unlike bowen's disease. Since more aggressive course of bowenoid actinic keratosis, we would like to present this case as a reminder for practicing dermatologists.

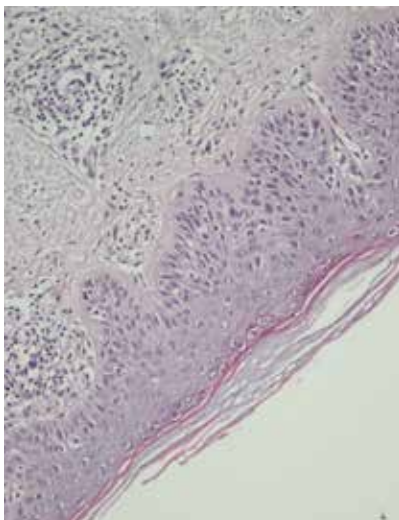
Keywords: Bowenoid Actinic Keratosis, In Situ Squamous Cell Carcinoma, Solar Damage

Figure 1



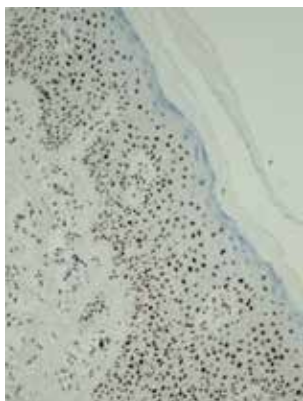
Erythematous, sharp-edged plaque

Figure 2



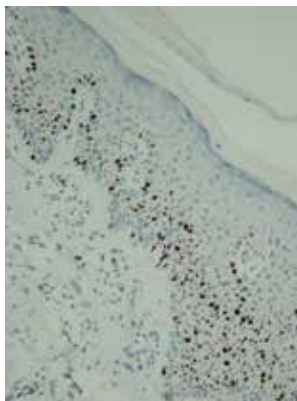
Hyperkeratosis with Dysplasia and Solar Damage

Figure 3



p53 Expression for Atypical Keratinocytes

Figure 4



Ki-67 Expression for Atypical Keratinocytes



3rd INDERCOS

National Dermatology & Cosmetology Congress with International Participants

14-17 MARCH, 2018
HILTON ISTANBUL BOSPHORUS HOTEL
ISTANBUL, TURKEY

PP-083

[WOUNDS, CHRONIC WOUNDS, WOUND HEALING, ULCER]

A MORTAL CASE OF PYODERMA GANGRENOSUM WITH PULMONARY INVOLVEMENT

Sevim Baysak, Tuğba Falay Gür, Neslihan Kaya Terzi, Cüneyt Kara, Caner Unay, Bilal Doğan
Department of dermatology, Sultan Abdulhamid Han Training and Research Hospital, Istanbul, Turkey

INTRODUCTION: Pyoderma gangrenosum (PG) is a rare chronic inflammatory disease that is classified as neutrophilic dermatosis. The characteristic lesion is a painful, raised from skin, red or violaceous necrotic ulcer with irregular borders that heals with cribriform scarring.

CASE: A 68 years-old male patient with stage IV chronic lymphocytic leukemia (CLL) was referred to our clinic from hematology department for perianal ulcer. The lesion that appeared 2 months ago and has increased in size was painful. The patients was given oral antibiotics, antiviral drugs and topical therapies for the treatment of the lesion. The patient has been on ibrutinib for CLL for a month and underwent surgical debridement 3 weeks ago. Dermatological examination revealed 10x8 cm ulcerative lesions with irregular borders that are slightly raised from skin located extending from perianal area to bilateral gluteal regions. Laboratory tests revealed no abnormalities except for a decrease in hemoglobin (8,81 g/dl) and platelet (76,000) counts. Histopathologic examination showed mixed type inflammatory cell infiltration with neutrophils mainly with accompanying lymphocytes. The possible causes of perianal ulcers were eliminated. The patient was diagnosed with PG based on clinical, laboratory and histopathologic findings. Methylprednisolone 80 mg/day treatment was initiated. In the follow-up, cough and hemoptysis symptoms of the patient led to a thorax CT which detected bilateral multiple increased nodular density that were partly cavitory especially in upper lobe of right lung. Amphotericin B was started as an empirical therapy and transthoracic lung biopsy was planned but the patient died on the third day of the treatment.

DISCUSSION: 50% of PG cases are associated with an underlying systemic disease like it was in our case. There is a case report of PG associated with ibrutinib in literature. The lesion of our patient had appeared 1 month before the initiation of ibrutinib therapy but it is also possible that the current lesion worsened due to ibrutinib. The pathergy test positivity was reported in 25% of PG cases. The increase in size of the lesion following surgical debridement pointed out the possibility of pathergy test positivity in our case. A small number of PG cases with pulmonary involvement were reported in literature. Unilateral or bilateral nodules with or without necrosis are present radiologically. In addition to that, most of the PG cases with pulmonary involvement are associated with hematological disorders. CT scan of our case revealed bilateral multiple nodules. CLL diagnosis and CT scan of our patient indicated a PG case with a possible pulmonary involvement. Our case report is significant as it emphasizes the seriousness of the disease by having a lesion with rare location (perianal region), pathergy test positivity, and mortality with pulmonary involvement.

Keywords: Pyoderma Gangrenosum, Pulmonary Involvement, Pathergy

3rd INDERCOS

National Dermatology & Cosmetology Congress with International Participants

14-17 MARCH, 2018
HILTON ISTANBUL BOSPHORUS HOTEL
ISTANBUL, TURKEY



PP-084

[MISCELLANEOUS]

ACQUIRED REACTIVE PERFORATING COLLAGENOSIS: A CASE REPORT

Kiyimet Handan Kelekçi¹, Ali Karakuzu¹, Aslı Kahraman Akkalp²

¹*Department of Dermatology, İzmir Katip Çelebi University Atatürk Training and Research Hospital, İzmir, Turkey*

²*Department of Pathology, İzmir Katip Çelebi University Atatürk Training and Research Hospital, İzmir, Turkey*

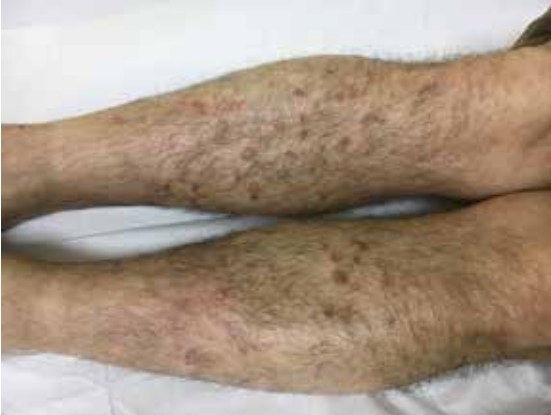INTRODUCTION: Acquired reactive perforating collagenosis is an uncommon condition characterized by transepidermal elimination of dermal material. The discrete papules pinhead-sized, skin-colored papules that grow to a diameter of 4–6 mm and develop a central area of umbilication in which keratinous material is lodged. Acquired reactive perforating collagenosis may involve sites of frequent trauma, such as the backs of the hands, forearms, elbows, and knees. Most reports usually support an autosomal recessive mode of inheritance or underlying diseases, such as diabetes mellitus or renal diseases. No specific treatment is indicated.

CASE: A 62-year-old male presented with generalized pruritus for about six months, resulting in skin lesions on the upper limbs, lower limbs, and trunk. He was known to have diabetes mellitus, hypertension and hepatitis B but was otherwise well. Pathological history revealed systemic arterial hypertension and diabetes mellitus for ten years. Dermatological examination revealed pruritic erythematous papules and nodules with a keratotic center on the upper limbs, lower limbs, and trunk (Figures 1,2). Umbilicated papular lesions, with central keratotic plugs, as seen on the shoulder head and anterior calf had the same predominant morphological features of the dermatological picture (Figure 3). Histopathological examination revealed ruptured epidermis with elimination of dermal material Masson's trichrome and Weigert-Van Gieson stains showed elimination of degenerated collagen and elastic fibers on the ulcer base (Figure 4).

CONCLUSION: Acquired reactive perforating collagenosis are rare, skin disorder occurring predominantly in the upper limbs, lower limbs, and trunk. Acquired perforating dermatosis is strongly linked with longstanding diabetes and chronic kidney disease, often in association with haemodialysis. In the presence of diabetes mellitus and severe pruritus with pruritic papules, acquired reactive perforating collagenosis must be considered in the differential diagnosis.

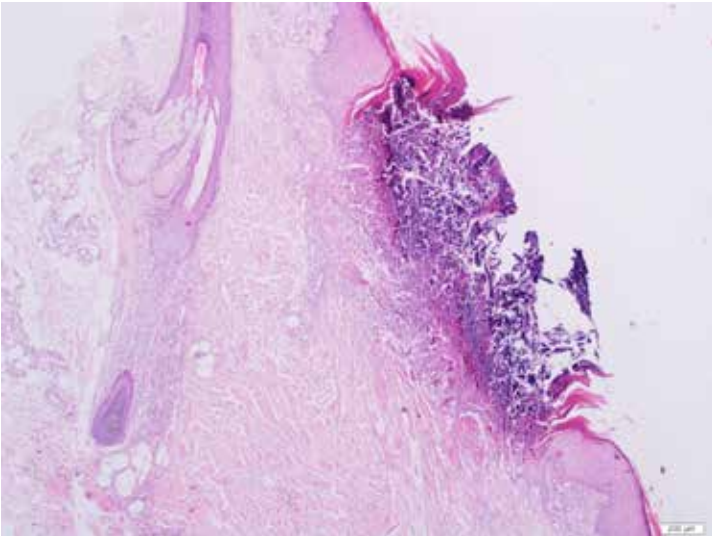
Keywords: acquired, diabetes mellitus, reactive perforating collagenosis,

Figure 1



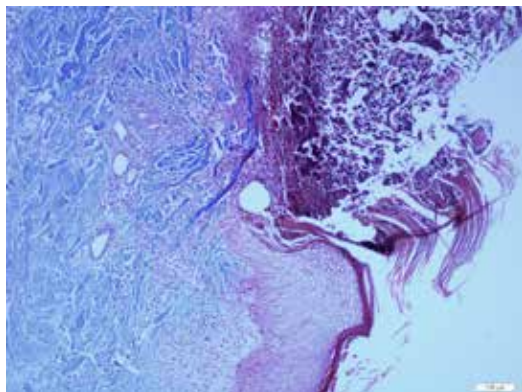
Discrete purple colored papules with develop a central area of umbilication on legs

Figure 2



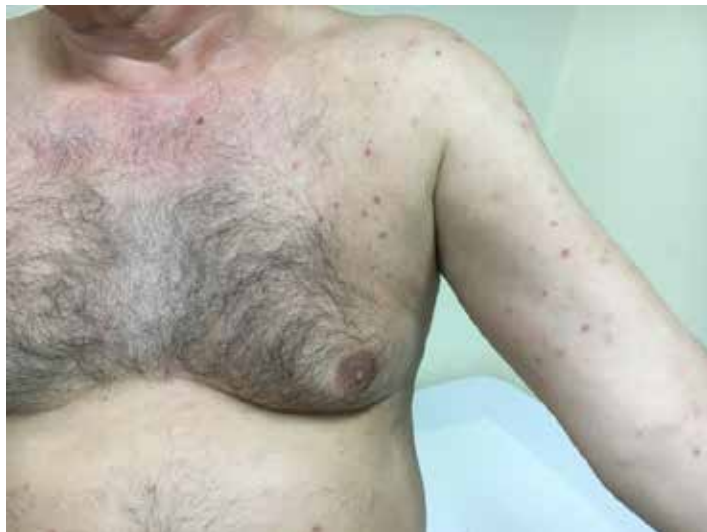Biopsy through the center of the lesion. Ulceration, crusting, and intense inflammation.

Figure 3



Masson Trichrome stains showed the blue collagen fibers into and through the epidermis at the end of the ulcer.

Figure 4



Discrete purple colored papules with develop a central area of umbilication on upper arm and trunk



3rd INDERCOS

National Dermatology & Cosmetology Congress with International Participants

14-17 MARCH, 2018
HILTON ISTANBUL BOSPHORUS HOTEL
ISTANBUL, TURKEY

PP-085

[RESEARCH IN D/V, EXPERIMENTAL D/V]

EVOLUTION AND INNOVATION OF DERMO-COSMETIC PRODUCTS

Eva Sobczyk¹, Mercedes Siguenza², Guillermo Solano Lopez³,

Joanna Wantuch Oszczak⁴, Dorota Prandecka⁵, Marcin Kwasniewski⁶

¹*Eva Sobczyk Clinical Research and Regulatory Affairs, Toulouse, France*

²*Mercedes Siguenza, Dermatologist, Madrid, Spain*

³*Guillermo Solano-Lopez, Dermatologist, Madrid, Spain*

⁴*Joanna Wantuch-Oszczak, Dermatologist, Warsaw, Poland*

⁵*Dorota Prandecka, Dermatologist, Warsaw, Poland*

⁶*Marcin Kwasniewski, Dermatologist, Warsaw, Poland*

PRESENTATION: The development of heavy industry, the excessive use of chemical products and the intensification of skin diseases over the last ten years in Europe have strongly influenced habits and trends of the European dermo-cosmetic market. The creation of more natural and innovative dermo-cosmetic products has increased over 4 times and their use has become an obligatory part of daily activities. A prestige and an unquestionable advantage: the European dermo-cosmetic sector holds the 1st place on the global market.

OBJECTIVES: The aim of this study is the analysis of use of dermo-cosmetic products by women between 30 and 60-year-old and their innovative diversification over the last decade: contribution to physiological skin disorders' treatment, (atopic dermatitis, contact allergy, acne, severely dry skin, psoriasis, depigmentation, etc.)

MATERIAL-METHODS: It was a multicentric study in an open environment in Germany, Spain, France, Italy, Holland, Poland, Portugal and United Kingdom. Anonymous survey was conducted by the author among 1000 users. Statistics: test of χ^2 , Kruskal-Wallis' non-parametric test and Spearman's correlation. Bibliography.

RESULTS: Analysis of the data showed that there is a change in use of dermo-cosmetics among women in the EU. The results show that women use dermo-cosmetics more often and rather as a complementary therapy in skin disorders than for beauty care. Health and skin protection, curative properties wellbeing and natural composition are the most important feature. Consequently new phenomena introduced new dermo-cosmetics with recent formulations like « preservatives free », « healing skin recovery » or « only plant ingredients ».

CONCLUSION: Taking care of skin and feel better function as the main reasons to use the dermo-cosmetics. Younger women tend to use natural products and as a supplement of pharmaceutical treatment of skin disorders. With age, women add also comfort and wellbeing. Nevertheless, the most common, is a high use of these products which innovation is a constant challenge for several European laboratories.

Keywords: Dermo-cosmetics, skin disorders' treatment, innovation

3rd INDERCOS

National Dermatology & Cosmetology Congress with International Participants

14-17 MARCH, 2018
HILTON ISTANBUL BOSPHORUS HOTEL
ISTANBUL, TURKEY



PP-086

[INFLAMMATORY SKIN DISEASES]

COEXISTING AND COLOCALIZED VITILIGO AND PSORIASIS: TWO CASE REPORTS

Emin Ozlu¹, Yunus Ozcan¹, Ebru Karagun¹, Mehmet Gamsizkan², Ragip Ertas³

¹Duzce University School of Medicine, Department of Dermatology, Duzce, Turkey

²Duzce University School of Medicine, Department of Pathology, Duzce, Turkey

³Kayseri Training and Research Hospital, Department of Dermatology, Kayseri, Turkey

INTRODUCTION: Vitiligo is an acquired pigmentary disorder with an estimated 1% prevalence worldwide. The cause is thought to be autoimmune or autoinflammatory in origin and other autoimmune diseases usually accompany. Psoriasis is a chronic inflammatory skin disease often with thick-scaled plaque formation. The etiology is multifactorial, autoimmunity and genetic basis have clear roles. There are few reports coexistence and colocalization of psoriasis and vitiligo.

CASE REPORTS: We present two cases with the coexistence and colocalized of vitiligo and psoriasis. The first case, who was 49 years-old woman, had vitiligo since childhood and psoriasis vulgaris since 7 years. Dermatological examination revealed scaling erythematous plaques and depigmented patches on her lower extremities. She had a colocalized lesion on the dorsum of her left foot..

The second case, who was 56 years-old woman, had vitiligo since childhood and psoriasis vulgaris since 28 years. Dermatological examination revealed colocalization of scaling erythematous plaques and depigmented patches on her lower and upper extremities. Histopathological findings of patients were compatible with vitiligo and psoriasis. Both patients were diagnosed with colocalized vitiligo and psoriasis based on the history and clinical findings.

CONCLUSION: The cases were reported due to rare occurrence of coexistence and colocalization of psoriasis and vitiligo.

Keywords: Coexistence, psoriasis, vitiligo.

PP-087

[CUTANEOUS ONCOLOGY]

PERIANAL PAGET'S DISEASE: A CASE REPORT

Hilal Kaya Erdoğan¹, Hatice Parlak¹, Ersoy Acer¹, Funda Canaz², Zeynep Nurhan Saracoglu¹

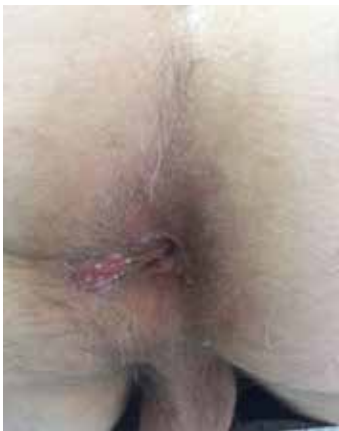¹Eskişehir Osmangazi Üniversitesi, Deri ve Zührevi Hastalıkları Anabilim Dalı, Eskişehir

²Eskişehir Osmangazi Üniversitesi, Patoloji Anabilim Dalı, Eskişehir

Paget's disease is as a disease of the breast skin and associated with adenocarcinoma. Perianal Paget's disease is a rare subtype and represents approximately 20% of cases of extra-mammary Paget's disease. Patients usually present with anal pruritus and can be misdiagnosed with hemorrhoids. A 51-years-old male was admitted to the our clinic with complaints of itching and nonhealing scar on perianal region for 1 year. The patient had used oral antihistamines, antibiotics, topical fucidic acid, antifungals and steroids at different periods without regression of the lesion. On dermatologic examination, an erythematous, ulcerated, discoid plaque about 1.5 cm in diameter on the left side of the anal region was detected (Figure 1). Complete blood count, biochemical tests and urinalysis were within normal limits. No pathological finding was found in urinary system ultrasonography. A punch biopsy was performed and histopathology was consistent with Paget's disease. The patient was consulted to urology and general surgery departments to exclude urogenital and gastrointestinal malignancies. Herein, we present a 51 years old man diagnosed with perianal Paget's disease.

Keywords: Paget's disease, perianal, adenocarcinoma

Figure 1



3rd INDERCOS

National Dermatology & Cosmetology Congress with International Participants

14-17 MARCH, 2018
HILTON ISTANBUL BOSPHORUS HOTEL
ISTANBUL, TURKEY



PP-088

[MISCELLANEOUS]

INTESTINAL MALIGNANT MELANOMA. PRIMARY? OR SECONDARY?

Ebru Zemheri¹, Hande Nur Aksoy¹, Merve Aydemir¹, İlkin Zindancı², Melike Kibar Ozturk², Aypınar Kolay²

¹Department of Pathology, Sağlık Bilimleri University, Umraniye SUAM Training and Research Hospital, Istanbul, Turkey

²Department of Dermatology, Sağlık Bilimleri University, Umraniye SUAM Training and Research Hospital, Istanbul, Turkey

A 70-year-old male patient was urgently operated with intestinal intussusception and secondary bowel obstruction. Two tumors were detected in 4x3x1.3 cm of ileum and 6.5x4.8x3.5 cm of cecum. In the microscopic examination, intestinal pigmentary malignant melanoma (MM) was detected in both foci and the patient was referred for dermatology consultation for primary tumour of the skin. A 0.4 cm sharp nevus was seen behind the right ear in the examination. Dermoscopic examination revealed two axial asymmetry, irregular extensions, a frosted appearance at the center, scattered asymmetric dots and globular traces. In microscopic examination after excision, lentiginous type melanoma in situ and dermis regression findings were observed in the epithelium. With this finding, the case was evaluated as regressive MM and intestinal metastasis. Brain metastasis was detected in the patient's systemic scan. The BRAF V600 gene mutation in the tumor was studied but could not be quantified by extensive pigmentation.

Skin MM usually metastasize to the lymph node, lung, brain liver, bone and gastrointestinal tract. Gastrointestinal melanoma is a very rare entity and it is difficult to detect whether it is primary or metastatic. Dermatological examination and systemic screening are absolutely necessary for primary or secondary tumor.

Keywords: malignant melanoma, gastrointestinal tractus, metastasis



3rd INDERCOS

National Dermatology & Cosmetology Congress with International Participants

14-17 MARCH, 2018
HILTON ISTANBUL BOSPHORUS HOTEL
ISTANBUL, TURKEY

PP-089

[MISCELLANEOUS]

RECURRENT UNILATERAL LINEAR CAPILLARITIS: A VERY RARE VARIANT OF PIGMENTED PURPURIC DERMATOSIS

Fadime Kılınç¹, Akin Aktaş², Sibel Orhun Yavuz³, Ayşe Akbaş¹, Sertaç Şener¹

¹Ataturk Training and Research Hospital, Dermatology Clinic, Ankara, Turkey

²Yildirim Beyazıt University, Medical Faculty, Department of Dermatology, Ankara, Turkey

³Ataturk Training and Research Hospital, Pathology Clinic, Ankara, Turkey

Pigmented purpuric dermatosis; is a chronic group of dermatoses characterized by petechiae and pigmented macules, usually seen in the lower extremities, with similar histopathological features. As clinically, five different types are described: Progressive pigmented purpuric dermatosis (Schamberg's purpura), Purpura annularis telangiectoides (Majocchi purpura), lichen aureus, pigmented purpuric lichenoid dermatosis of Gougerot and Blum and eczematoid-like purpura of Doucas and Kapetanakis. Furthermore, there are also very rare variants that are not included in the classification: These are granulomatous and unilateral linear capillaritis variants. Unilateral linear capillaritis is a very rare variant of pigmented purpuric dermatosis. It is characterized by unilateral, linear or segmental purpuric macules. It is mostly observed in the lower extremities but may also be seen in the upper extremities. As far as we know, up to now 15 cases have been reported. In here; because of its rarity, a 18 years old woman was presented with 3 years history of recurrent linear purpuric rash on left upper limb.

Keywords: linear, pigmented purpuric dermatose, unilateral



PP-090

[INFECTIOUS DISEASES, PARASITIC DISEASES, INFESTATIONS]

A CUTANEOUS LARVA MIGRANS CASE OBSERVED IN DÜZCE REGION

Ali Haydar Parlak¹, Tekden Karapınar¹, Gizem Yavuzcan², Serap Sertkaya¹, Betül Şereflican¹

¹Department of Dermatology, Abant İzzet Baysal University Faculty of Medicine, Bolu, Turkey

²Department of Dermatology, Atatürk Public Hospital, Düzce, Turkey

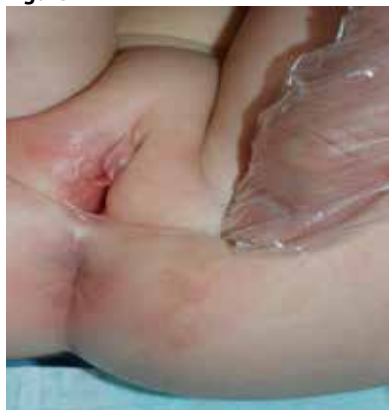INTRODUCTION: Cutaneous larva migrans caused by penetration of hookworm larvae into the skin. It is more commonly seen in those who have contact with soil contaminated by cat and dog's hookworm larvae. People are often transmitted by contact with contaminated soil or sand. This case is presented because of the rarity of this condition with skin findings in our country.

CASE: A 2-year-old infant was brought to the polyclinic by her family because of the itchy lesion spreading from the gluteal region to the perineum and vulva for 1 month. In the gluteal region of the patient there was an arc-shaped, annular, linear, slightly hyperpigmented plaque. On the vulva, slightly raised larvae lines were observed inside the labium majus (Figure 1). There was a story of the patient sitting on the sand and soil. She was diagnosed as having cutaneous larva migrans. Albendazole treatment was given and the lesion was cured in a short time.

DISCUSSION: Cutaneous larva migrans is most common in tropical and subtropical geographical regions. There is not enough data about the incidence in our country. We presented this case with the aim of reminding that cutaneous larva migrans should be kept in mind in differential diagnosis of itchy linear lesions.

Keywords: albendazole, cutaneous larva migrans, hookworm

Figure 1



arc-shaped, annular, linear larvae lines on the gluteal region



3rd INDERCOS

National Dermatology & Cosmetology Congress with International Participants

14-17 MARCH, 2018
HILTON ISTANBUL BOSPHORUS HOTEL
ISTANBUL, TURKEY

PP-091

[ADVERSE DRUG REACTIONS, TEN]

A CASE OF ACUTE GENERALISED EXANTHEMATOUS PUSTULOSIS INDUCED BY FLUCONAZOLE

Mahmut Can Koska¹, Burçe Can Kuru¹, İlkin Zındancı¹, Sıdıka Şeyma Özkanlı²

¹Department of Dermatology and Venereology, Istanbul Medeniyet University Goztepe Research and Training Hospital, Istanbul, Turkey

²Department of Pathology, Istanbul Medeniyet University Goztepe Research and Training Hospital, Istanbul, Turkey

INTRADUCTION: Acute Generalised Exanthematous Pustulosis (A.G.E.P.) is an uncommon eruption mostly caused by drugs. It is characterised by non-follicular pustules on erythematous and oedematous base. Many drugs have been reported so far.

CASE: 87 year-old female patient with non-follicular pustules on erythematous and oedematous base. Lesions involved mainly inframammary folds, trunk, buttock, neck and face. Her past medical revealed development of her lesion one day after initiation of Fluconazole. With clinical and histopathologic findings we confirmed diagnosis of A.G.E.P. After withdrawal and systemic corticosteroid therapy lesions resolved rapidly.

DISCUSSION: A.G.E.P. is a widespread eruption which is mainly caused by drugs although insect bites, viral infections and contact allergens have been reported. Delayed type of hypersensitivity reactions are responsible for eruption and Patch tests can be beneficial for identification of agent. Many drugs have been reported including Aminopenicilline, Cephalosporins, Clindamycin, Sulfonamides. Although very frequently used drug, Fluconazole has been rarely reported.

Keywords: Fluconazole, Acute Generalised Exanthematous Pustulosis, A.G.E.P.

3rd INDERCOS

National Dermatology & Cosmetology Congress with International Participants

14-17 MARCH, 2018
HILTON ISTANBUL BOSPHORUS HOTEL
ISTANBUL, TURKEY



PP-092

[CUTANEOUS ONCOLOGY]

SUBCUTANEOUS PANNICULITIS LIKE NK/T CELL LYMPHOMA, NASAL TYPE; AN UNUSUAL CASE PRESENTATION

Ebru Zemheri¹, Merve Aydemir¹, İlkin Zindancı², Melike Kibar Ozturk², Aypınar Kolay²

¹Department of Pathology, Sağlık Bilimleri University, Umraniye SUAM Training and Research Hospital, Istanbul, Turkey

²Department of Dermatology, Sağlık Bilimleri University, Umraniye SUAM Training and Research Hospital, Istanbul, Turkey

A 51-year-old woman presented with great nodules on her arms. Three years ago, the patient was informed that intestinal involvement of nasal type extranodal NK / T cell lymphoma was present in the small intestine resection material. On the dermatologic examination of the patient, erythematous, tender, hot, 3-10 cm sized, subcutaneous nodules were observed with palpation on her upper extremities. Histopathological examination revealed diffuse infiltration and nodules infiltrating deep dermis and fat lobule. The infiltrate consisted of small to medium-sized lymphocytes, granulomatous structures, giant cells. CD2, CD7, Granzyme B, CD56 positive NK cells in the nodule areas. CD3, CD2, CD5, CD7 were positive in the diffuse areas. It was common with EBER (ISH). These findings were reported as extranodal NK / T cell lymphoma, nasal type skin involvement. Extranodal NK / T cell lymphoma, nasal type skin involvement is very rare and have poor prognosis. We presented our rare case with literature information and differential diagnosis.

Keywords: Subcutaneous panniculitis, NK/T cell lymphoma nasal type, histopathology, cutaneous lymphoma

PP-093

[DERMATOPATHOLOGY]

RETICULAR ERYTHEMATOUS MUCINOSIS ON THE BACK: A CASE REPORT

Ceyda Tetik Aydogdu¹, Suzan Demir Pektas¹, Emine Tugba Alatas¹, Leyla Tekin², Hilal Semra Hancer¹, Gursoy Dogan¹

¹Department of Dermatology, Mugla Sitki Kocman University, Faculty of Medicine, Mugla/TURKEY

²Pathology of Dermatology, Mugla Sitki Kocman University, Faculty of Medicine, Mugla/TURKEY

Reticular erythematous mucinosis is a rare dermatologic condition which is typically characterized erythematous papules tend to coalesce into reticulated pattern of plaque on the midline of chest and back. Histologically; perivascular lymphocytic infiltrate with mucin deposit in dermis can be seen. We report a case of 31-year-old man who presented erythematous papules and excoriations on the back of 6 years' duration. On the histological examination; superficial perivascular and periadnexal lymphocytic infiltrate and mucin deposit between collagen fibers of dermis were determined. Based on clinical and histopathological findings, the diagnosis was made as reticular erythematous mucinosis. Although reticular erythematous mucinosis is uncommon diseases, it must be remembered for the differential diagnosis in midline dermatologic conditions.

Keywords: Reticular erythematous mucinosis, rare disease, erythematous papules

Figure 1

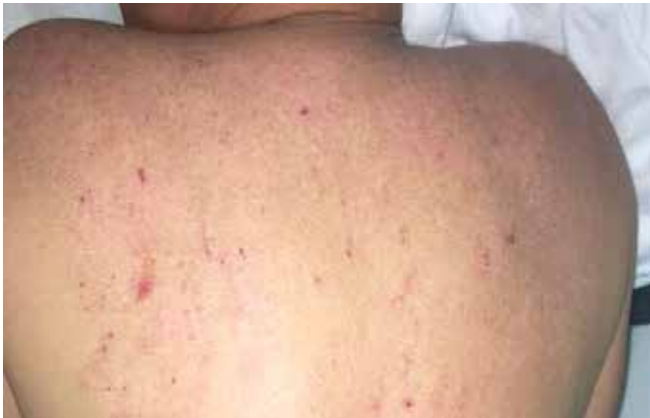

Figure 1: Erythematous papules and excoriations on the upper back.

Figure 2

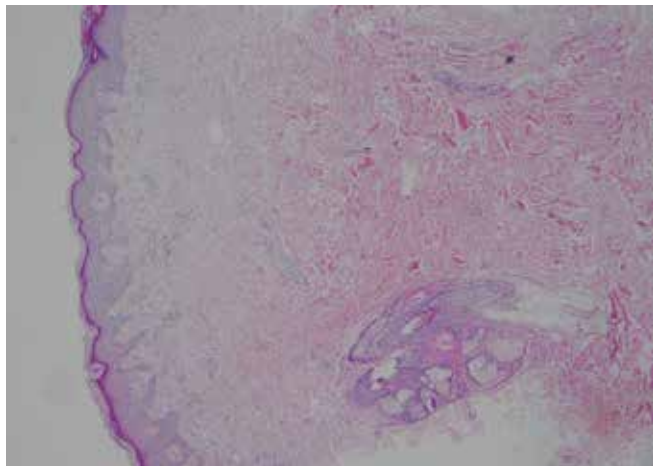


Figure 2: Sections show a superficial and reticular perivascular and periadnexal mononuclear infiltrate

Figure 3

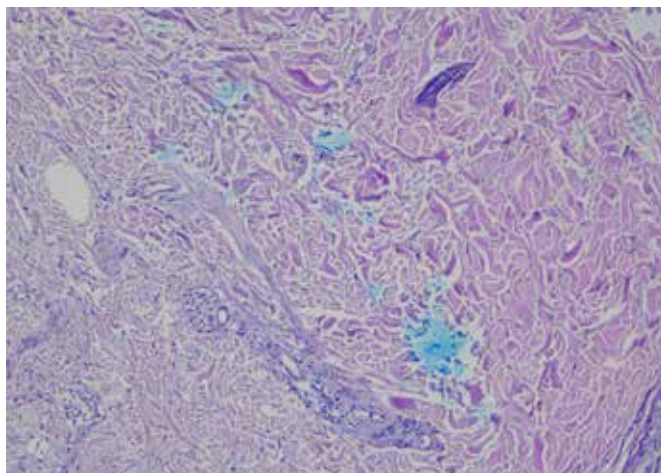


Figure 3: The presence of mucin between collagen fibres of dermis is characteristic of the disorder.



3rd INDERCOS

National Dermatology & Cosmetology Congress with International Participants

14-17 MARCH, 2018
HILTON ISTANBUL BOSPHORUS HOTEL
ISTANBUL, TURKEY

PP-094

[CUTANEOUS ONCOLOGY]

"LYMPHOMATOID PAPULOSIS WITH 6P25.3 REARRANGEMENT": A NEW SUBTYPE OF LYMPHOMATOID PAPULOSIS

Meryem Doğan Altınpulluk¹, Ebru Zemheri¹, İlkin Zindancı², Melike Kibar Öztürk²

¹Department of Pathology, Sağlık Bilimleri University, Umraniye SUAM Training and Research Hospital, Istanbul, Turkey

²Department of Dermatology, Sağlık Bilimleri University, Umraniye SUAM Training and Research Hospital, Istanbul, Turkey

A 67-year-old male presented with a 6-month history of recurrent erythematous papules on his face, scalp and extremities persisting for approximately 7 weeks before resolving spontaneously. Dermatological examination revealed multiple erythematous 0.5-2 cm. sized papulonodules. The lesion located on his leg was larger and hemorrhagic. He was systemically well with no B symptoms, lymphadenopathy or hepatosplenomegaly.

A punch biopsy was performed. At low-power magnification, biopsy showed a prominent dermal nodule with a dense lymphoid infiltrate. The epidermis was nonulcerated and peppered with atypical small- to medium-sized mononuclear cells with irregular nuclei in a pagetoid reticulosis pattern. The atypical cells in the dermis were medium to large in size with hyperchromatic, irregular nuclei and abundant finely granular cytoplasm. Large atypical cells had a CD3+, CD4-, CD8-, CD2-, CD5-, CD7+ immunophenotype. CD30 staining is biphasic with stronger staining of dermal compared with epidermal cells. ALK-1 and CD56 were negative and Ki-67 was > 95%.

Lymphomatoid papulosis (LyP) is a chronic, recurring CD30-positive T-cell lymphoproliferative disorder. We presented a new variant of Lymphomatoid Papulosis consistently associated with rearrangements associated with rearrangements of the IRF4-DUSP22 locus on 6p25.3. Without appropriate clinical information this case could be misdiagnosed as transformed Mycosis fungoides or another aggressive lymphoma, potentially resulting in overtreatment in an elderly patient population. Thus, the presented case highlights the importance of careful clinicopathologic correlation and points to the expanding role of new molecular tools in the definition and routine diagnosis of human neoplasms.

Keywords: lymphomatoid papulosis, cutaneous CD30-positive T-cell lymphoproliferative disorder, chromosomal translocation

3rd INDERCOS

National Dermatology & Cosmetology Congress with International Participants

14-17 MARCH, 2018
HILTON ISTANBUL BOSPHORUS HOTEL
ISTANBUL, TURKEY



PP-095

[URTICARIA, ANGIOEDEMA]

HODGKIN LYMPHOMA IN A PATIENT WITH NORMOCOMPLEMENTEMIC URTICARIAL VASCULITIS

Kübra Kızıldağ¹, Sinem Ayşe Örnek¹, Ömer Özdemir¹, Koray Taşçılar², Emek Kocatürk¹

¹Department of Dermatology, Okmeydanı Training and Research Hospital, Istanbul, Turkey

²Department of Internal Medicine, Okmeydanı Training and Research Hospital, Istanbul, Turkey

Urticarial vasculitis is a small-vessel vasculitis with predominant skin involvement which characterized by wheals persisting for more than 24 hours, burning rather than itching and resolving with hyperpigmentation. Besides urticarial wheals other cutaneous manifestations including purpura, papules, vesicles, bullae and necrotic-ulcerative lesions may also present during the course of the disease. Urticarial vasculitis is known to be associated with a variety of disorders including viral infections, Henoch-Schönlein purpura, systemic lupus erythematosus, Sjögren's syndrome, IgM paraproteinaemia (Schnitzler's syndrome) and malignancies. No underlying disease can be detected in most cases of urticarial vasculitis. A patient with UV who developed Hodgkin lymphoma is reported here.

A 33-year-old woman presented to our allergy clinic with symptoms of hives and intense pruritus for a year. Her skin biopsy compatible with urticarial vasculitis. Her history was negative for fever, chills, weight loss, fatigue, joint pain, abdominal pain or any other systemic complaints. There is no family history of urticaria. She had normal serum C3, C4 levels. After 3 years she developed fever especially at night, chills, weight loss and cough. Investigations revealed high erythrocyte sedimentation rate (ESR) and C-reactive protein (CRP) levels. On USG examination, the patient had cervical, axillary and inguinal lymphadenopathy. After excisional biopsy of the axillary lymph nodes Hodgkin lymphoma diagnosis was made. The patient referred to hematology department.

Urticarial vasculitis has been described as a rare association with hematological and visceral malignancy. Malignancy should be investigated patients with systemic symptoms and treatment resistant disease.

Keywords: urticarial vasculitis, systemic symptoms, lymphoma

PP-096

[DERMATOPATHOLOGY]

LOCALIZED LOOSE SKIN ON THE BACK; ACQUIRED LOCALIZED CUTIS LAXA

Mustafa Aksoy¹, Rana Anadolu²

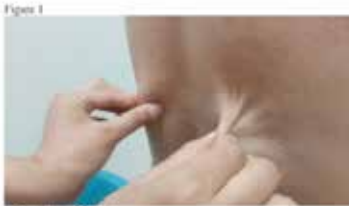¹Department of Dermatology and Venereology, Harran University, Sanliurfa, Turkey

²Department of Dermatology, Special Rana Anadolu Dermatology Clinic, Ankara, Turkey

Cutis laxa; is a rare disease characterized clinically by loose puffy skin and histologically dermal elastic tissue loss. Both forms of hereditary or acquired cutis laxa may be generalized or localized. Acquired cutis laxa can be seen in all ages, but most commonly occurs in the second and third decades. Acquired cutis laxa, which is less common than congenital cutis laxa, carries the risk of systemic involvement. The localized form of acquired cutis laxa is not very common, and there is often an inflammatory lesion before it. It is very rare that this form develops without inflammatory lesions in the beginning. Here, we present a male patient with a localized cutis laxa at the age of 34 years who developed a loosening of the skin under the right scapula and developed without an inflammatory lesion or dermatosis at the beginning.

Keywords: Acquired cutis laxa, loose skin, dermal elastic tissue loss

Figure 1 and 2



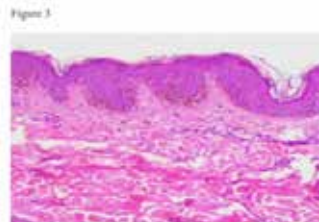
Back (middle upper part)



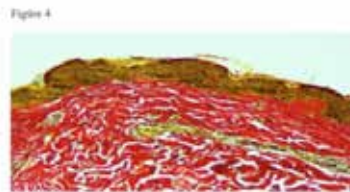
Right medial line of the back (lateral area)

Clinic photos

Figure 3 and 4



Histopathology



Verhoeff-Van Gieson stain

Histopathologic photos

3rd INDERCOS

National Dermatology & Cosmetology Congress with International Participants

14-17 MARCH, 2018
HILTON ISTANBUL BOSPHORUS HOTEL
ISTANBUL, TURKEY



PP-097

[PAEDIATRIC DERMATOLOGY]

A PEDIATRIC PATIENT WITH LIVEDOID VASCULITIS WITH NAIL FOLD DERMATOSCOPY FINDINGS

İlkin Zındancı¹, Melike Kibar Öztürk¹, Betül Sözeri², Ebru Zemheri³

¹Department of Dermatology, Umraniye Training and Research Hospital, Istanbul, Turkey

²Department of Child Rheumatology, Umraniye Training and Research Hospital, Istanbul, Turkey

³Department of Pathology, Umraniye Training and Research Hospital, Istanbul, Turkey

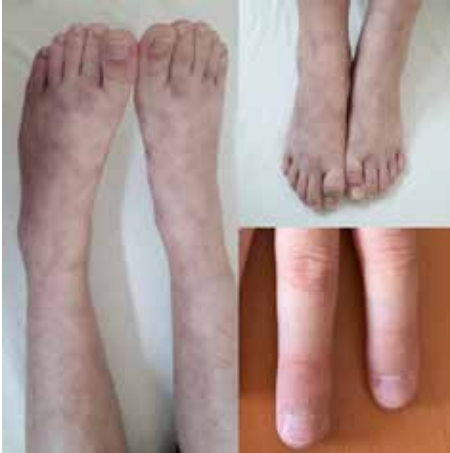BACKGROUND: Livedoid vasculitis (LV) is a skin disease with recurrent reticularis and ulcers, mainly affecting the feet and lower legs. The pathogenesis of LV has not been yet thoroughly understood, but thrombosis is thought to play a major role because fibrin deposition within both the wall and lumen of affected vessels is pathologically detected.

CASE: A 10-year-old child first presented to our hospital in 2017 with a 6 months history of a reticular rash on the lower legs and desquamation on hand fingers (fig 1). Screening tests for vasculitis and collagen disease were mostly normal except elevated C-ANCA value (5.74 U/ml). Thus, we conclude that it is the reason of LV. We evaluated the proximal nail fold with dermatoscopy and saw distinct vascular abnormalities with desquamation around nails (fig 2). There were loss of capillaries accompanied with elongated and large capillaries.

CONCLUSION Since there is not any report in the literature about dermatoscopic changes in nailfolds in LV, we wanted to show clinical pictures and dermatoscopic images of LV a patient in pediatric population.

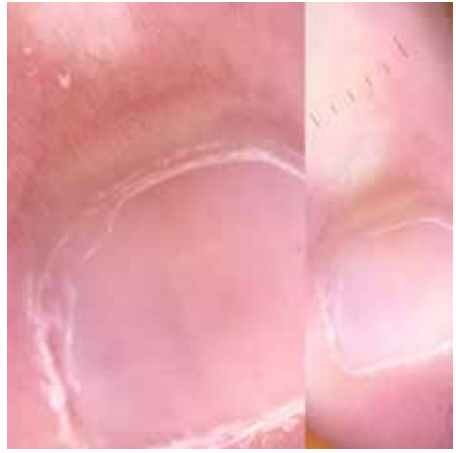Keywords: livedoid vasculitis, nail fold dermatoscopy, pediatrics

Figure 1



*Clinical pictures of reticular rash on the lower legs
desquamation on hand fingers.*

Figure 2



*Dermatoscopic picture of loss of capillaries and
accompanied with elongated and large capillaries*

3rd INDERCOS

National Dermatology & Cosmetology Congress with International Participants

14-17 MARCH, 2018
HILTON ISTANBUL BOSPHORUS HOTEL
ISTANBUL, TURKEY



PP-098

[PSORIASIS]

**PSORIASIS LESIONS DEVELOPING ON THE LOCALIZATION OF ZONA ZOSTER: ISOTOPIC RESPONSE?
ISOMORPHIC RESPONSE?**

Mualla Polat¹, Tekden Karapınar¹, Aslıhan Geyik¹, Selma Erdoğan Düzcü²

¹Department of Dermatology, Faculty of Medicine, Abant İzzet Baysal University, Bolu, Turkey

²Department of Pathology, Faculty of Medicine, Abant İzzet Baysal University, Bolu, Turkey

INTRODUCTION: Wolf's isotopic response refers to the occurrence of a new dermatosis at the site of unrelated, previously healed herpetic lesions. Koebner's phenomenon or isomorphic response is caused by deep traumatic or nonspecific stimulation. It appears on damaged and traumatized skin.

CASE: A 51-year-old male patient with psoriasis vulgaris was admitted with the complaint of a red, bloody rash that developed in the right part of his back in the last 15 days. Approximately 1.5 months ago, the patient was found to have zona zoster disease at the localization where the rash was present and then lesion was cured. On dermatological examination, erythematous, scaly plaques with dermatomal localization on the right side of the back were detected. Patient was diagnosed with psoriasis on account of the punch biopsy findings and dermatological examination findings.

DISCUSSION: Numerous stimulating factors have been reported that trigger the Koebner phenomenon. Physical and thermal traumas, dermatoses, infections, medications and light treatments are the triggers for Koebner phenomenon. After the zona zoster disease in the patient, it was thought that psoriatic lesions appear with the koebner phenomenon in that region.

Keywords: Psoriasis, Isotopic response, Isomorphic response



3rd INDERCOS

National Dermatology & Cosmetology Congress with International Participants

14-17 MARCH, 2018
HILTON ISTANBUL BOSPHORUS HOTEL
ISTANBUL, TURKEY

PP-099

[CUTANEOUS ONCOLOGY]

A CASE OF LYMPHOMATOID PAPULOSIS TYPE A

Kiymet Handan Kelekçi¹, Ali Karakuzu¹, Aslı Kahraman Akkalp²

¹Department of Dermatology, İzmir Katip Çelebi University Atatürk Training and Research Hospital, İzmir, Turkey

²Department of Pathology, İzmir Katip Çelebi University Atatürk Training and Research Hospital, İzmir, Turkey

Lymphomatoid papulosis (LyP) is an uncommon, defined as a chronic, recurrent, self-healing papulonecrotic or papulonodular skin disease with histologic features suggestive of a (CD30-positive) malignant lymphoma. LyP may occur at any age. The lesions evolve to papulovesicular, papulopustular, or hemorrhagic, then necrotic papules over days to weeks. LyP lesions typically heal spontaneously within 8 weeks. The duration of the disease ranges from several months to more than 40 years. LyP may be preceded by, associated with, or followed by another type of cutaneous or systemic lymphoma. The prognosis of LyP is usually excellent.

CASE: A 23-year-old male patient presented with complaints of rash on his legs. He stated that his complaints have been for 2 months. Dermatological examination revealed multipl, purple papulopustular, and necrotic papules on his legs(Figüre 1). Routine tests and peripheral smear blood tests were normal. LDH and beta 2 microglobulin were normal. Skin punch biopsy was performed from the necrotic papular lesions. The histopathological evaluation revealed characteristic cells with large vesicular nuclei, there is a background population of lymphocytes and eosinophils in the dermis(Figüre 2). Deep biopsy from the leg was compatible with Lpy type A. Topical steroid therapy was began. Lymphomatoid papulosis (LyP) is an indolent skin disease characterized by chronic, recurrent, self-healing papules and nodules with histologic findings suggestive of malignant lymphoma. Despite sharing histologic features of malignant lymphoma, LyP is an indolent skin disease. LyP is associated with an increased risk of secondary lymphoma and thus requires long-term follow-up is required in all patients with LyP.

Keywords: Lymphomatoid papulosis, cutaneous lymphoproliferative disorder, lymphoma

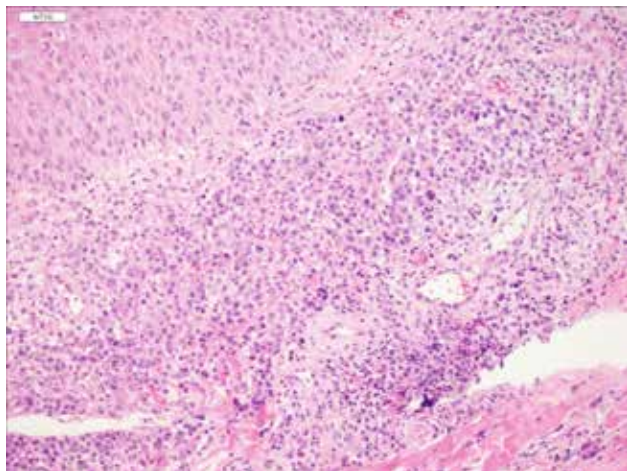
3rd INDERCOS

National Dermatology & Cosmetology Congress with International Participants

14-17 MARCH, 2018
HILTON ISTANBUL BOSPHORUS HOTEL
ISTANBUL, TURKEY

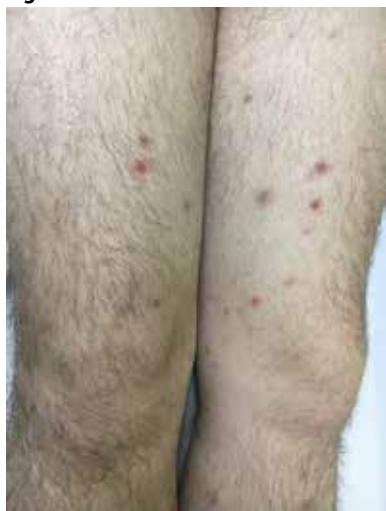

Figure 2



Charasteristic cells with large vesicular nuclei, there is a background population of lymphocytes and eosinophils

Figure 1



Lyp presents multipl necrotic papulosis on legs

PP-100

[INFLAMMATORY SKIN DISEASES]

IMITATION EARRING AND WATCH-INDUCED PSORIASIS IN A CHILD

Havva Yıldız Seçkin, Zennure Takçı, Atiye Oğrum

Gaziosmanpaşa University, School of Medicine, Department of Dermatology, Tokat

Psoriasis is a common chronic immune-mediated inflammatory disorder affecting the skin, nails and joints in both children and adults. Its prevalence has been estimated as 1 to 3 % in white population. It is estimated that approximately 30–50 % of adults with psoriasis developed psoriasis before 20 years of age. Psoriasis begins in childhood in almost one-third of the cases. The Kobner phenomenon is the development of typical lesions after injury to uninvolved skin of patients with certain dermatologic diseases. Koebner phenomenon is seen most frequently in psoriasis. We report a child with psoriasis following imitation earring and watch use.

CASE REPORT: A 2-year-old girl presented to our clinic with a 6-week history of scaling lesions on her both ear lobes and wrist. In the dermatological examination of the patient; Auspitz and wax stain phenomene-positive, erythematous plaques detected to located in her both ear lobes and left wrist (figure 1,2). No other skin lesions. There was no family history of psoriasis or of any other skin disorder.

Keywords: Psoriasis, Koebner phenomenon, Child

Figure 1

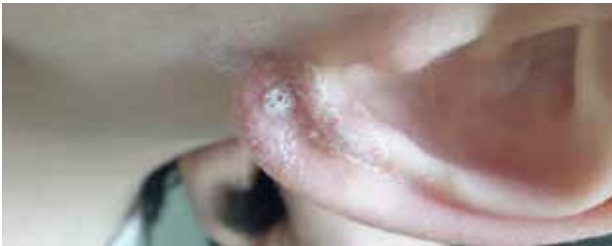

Figure 2



3rd INDERCOS

National Dermatology & Cosmetology Congress with International Participants

14-17 MARCH, 2018
HILTON ISTANBUL BOSPHORUS HOTEL
ISTANBUL, TURKEY



PP-101

[ANGIOLOGY, HAEMANGIOMAS, VASCULAR MALFORMATIONS, VASCULITIS] A CASE WITH PENILE MONDOR'S DISEASE

Hülya Cenk¹, Gülbahar Saraç²

¹Department of Dermatology, Sorgun State Hospital, Yozgat, Turkey

²Department of Dermatology, Inonu University, Malatya, Turkey

INTRODUCTION: Mondor's disease (MD) is a rare condition characterized by superficial thrombophlebitis or thrombosis of subcutaneous veins. It's most commonly seen on the anterior chest wall, although it can involve other areas, such as the neck, abdomen and penis. Penile MD (PMD), is much more rare compared to thoracic MD. It appears as a cord-like and an indurated lesion which is palpable along the involved vein tract. Its physiopathology is not exactly known, but vigorous sexual activity, trauma and surgery of the pelvis or external genitalia are the possible triggers considered to be associated. It heals mostly within 4 to 6 weeks without any medical treatment.

CASE: A 47 years old married male patient who has had pemphigus vulgaris for 13 years admitted to our polyclinic. He has been using 4 mg/day systemic steroid treatment for the last 4 months and 2 mg/day for the former 2 years. He had also type-2 diabetes mellitus and he was on oral antidiabetic treatment. He complained of a sudden, painless, indurated lesion on the penis shaft for 15 days. He had a cord-like, indurated, longitudinal lesion along the lateral distal third of the penis shaft and the lesion became more prominent after stretching the penis (Picture 1). He is clinically diagnosed with PMD. He denied all the possible triggering factors except strenuous sexual activity. A doppler ultrasonography is planned but the patient refused the research because he believed that it was a benign condition as the lesion was painless. After 1-week of sexual rest, the lesion regressed spontaneously.

DISCUSSION: PMD is a rare and self-limited disease and it can be clinically diagnosed. Differential diagnoses of PMD are Peyronie's disease and nonvenereal sclerosing lymphangitis. They can be discriminated from each other by clinical findings, but in difficult cases, doppler ultrasonography and histopathology may be required.

In this case, we have thought of a possible diabetic angiopathy and a possible prothrombotic effect of steroid treatment could have been contributed to the other possible reasons for the development of PMD such as vigorous sexual activity. Even if it's a benign, self-limited condition, we found it valuable to share because of its rarity.



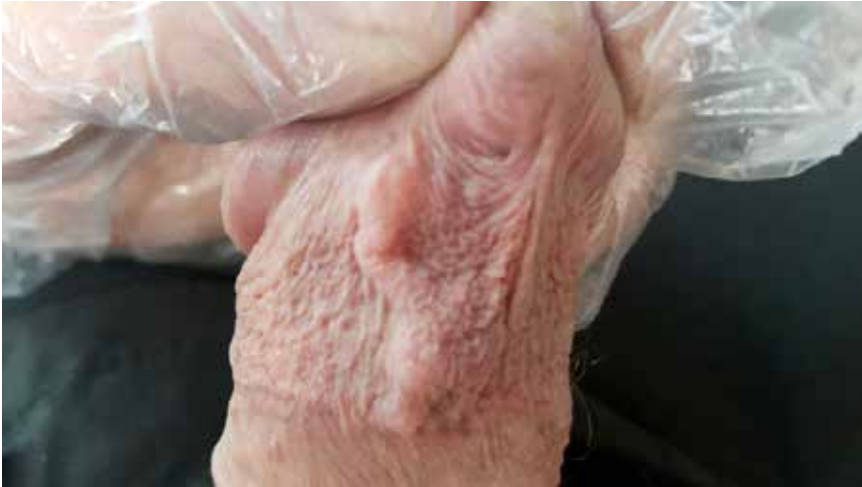3rd INDERCOS

National Dermatology & Cosmetology Congress with International Participants

14-17 MARCH, 2018
HILTON ISTANBUL BOSPHORUS HOTEL
ISTANBUL, TURKEY

Keywords: Mondor's Disease, penile, thrombophlebitis

Figure 1



A cord-like, indurated, longitudinal lesion along the lateral distal third of the penis shaft



PP-102

[LASERS]

THE EFFECT OF PULSED DYE LASER ON DEMODEX DENSITY

Ragıp Ertas¹, Ozan Yaman², Reşat Akkuş¹, Emin Özlü³, Atıl Avcı¹, Yılmaz Ulaş¹, Kemal Özyurt¹, Mustafa Atasoy¹

¹Health Sciences University, Kayseri Health Training and Research Center, Dermatology Clinic, Kayseri, Turkey

²Health Sciences University, Kayseri Health Training and Research Center, Parasitology Clinic, Kayseri, Turkey.

³Düzce University, School of Medicine, Department of Dermatology, Düzce, Turkey.

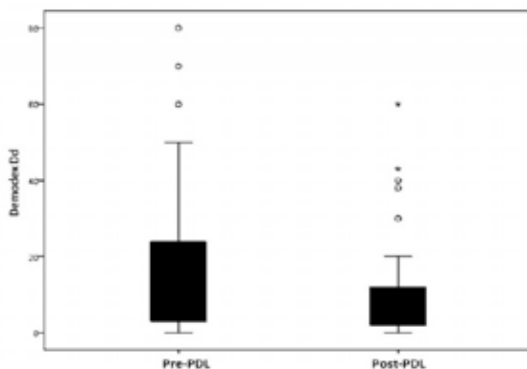
BACKGROUND: Recently, treatment with acaricides, which is aimed at reducing excessive proliferation of demodex mites, has gained popularity due to its providing a significant improvement in the symptoms of diseases, such as rosacea, seborrhoeic dermatitis and perioral dermatitis. The effect of IPL on demodex mites was reported in skin biopsy specimens in three patients, however, to the best of our knowledge, no study exists to date, which evaluates the effect of PDL (Pulse dye laser) on demodex density (Dd) in larger patient group. We aim here in to observe the Dd before and after PDL therapy with two different skin biopsy techniques.

MATERIAL AND METHODS: Thirty-one patients diagnosed with rosacea, were included in the study who received PDL treatment. Dds which were measured by using both the SSSB (standardized skin surface biopsy) and CTM (cellophane tape method) techniques before and after three weeks of PDL therapy were evaluated.

RESULTS AND DISCUSSION: The Dd of patients before PDL treatment was 13.0(Interquartile range(IQR);5.0-28.0) and after three weeks of PDL treatment it was 6.0 (IQR;3.0-12.0) with SSSB. After PDL treatment, the Dd was significantly lower than pre-treatment the Dd ($p=0.002$). The present study shows that PDL significantly reduced Dd in facial skin with one session.

Keywords: Demodex, demodex density, pulsed dye laser, standardized skin surface biopsy, cellophane tape method.

Figure 1



The effect of Pulse Dye Laser on Dd before treatment and after three weeks.



3rd INDERCOS

National Dermatology & Cosmetology Congress with International Participants

14-17 MARCH, 2018
HILTON ISTANBUL BOSPHORUS HOTEL
ISTANBUL, TURKEY

PP-103

[TOPICAL THERAPY]

IMPROVEMENT WITH IMIQUIMOD CREAM IN A WOMAN OF LARGE ORF VIRUS INFECTION

*Fatma Tunçez Akyürek, Gülcan Saylam Kurtipek
Department of Dermatology Selcuk University, Konya, Turkey*

INTRODUCTION: Orf is a viral infection caused by the parapoxvirus that is common among farming communities. Human can be infected by contact with sheep and goats. Disease tends to be self-limiting and resolve spontaneously within 6-8 weeks. It is usually characterized by a small ulcer or nodule on the hand or finger however there may be multiple and giant lesions located in atypical localizations. It has been reported that rapid improvement of giant and recurrent orf infection with topical imiquimod cream in previous case reports.

CASE: We present the case report of a 38-year-old woman who developed two erythematous nodular lesions on her fingers after contact with sheep meat. Her lesions continued to grow and a large tumoral lesion approximately 3cm in diameter was seen on the left hand second finger and a smaller lesion noted on the right hand third finger. We observed a rapid improvement in the lesions of the patient even in the first week of imiquimod treatment.

CONCLUSION: Orf infection may show progressive course in immunosuppressed patients. Only very few cases of large and atypical orf lesions develop in immunocompromised patients have been described in the literature. In these patients; the lesions do not regress spontaneously. Imiquimod is an agent with antiviral activity and it can be considered as an effective agent in the treatment of large and resistant orf lesions.

Keywords: Imiquimod, Orf, Parapoxvirus

3rd INDERCOS

National Dermatology & Cosmetology Congress with International Participants

14-17 MARCH, 2018
HILTON ISTANBUL BOSPHORUS HOTEL
ISTANBUL, TURKEY



PP-104

[INFLAMMATORY SKIN DISEASES]

GENERALIZED ANNULAR PURPURIC LESIONS: A RARE ATYPICAL FORM OF PITYRIASIS ROSEA

Havva Yıldız Seçkin¹, Atiye Oğrum¹, Zennure Takçı¹, Akgül Arıcı²

¹Gaziosmanpasa University, School of Medicine, Department of Dermatology, Tokat

²Gaziosmanpasa University, School of Medicine, Department of Pathology, Tokat

Pityriasis rosea (PR) is an acute inflammatory skin disease characterized by erythematous scaling macules, papules, and plaques predominantly on the trunk and proximal extremities. PR may present in atypical clinical forms. Purpuric PR, a rare variant of PR, is characterised by the presence of pruritic annular patches. A 25-year-old female presented with progressive eruption of mildly itchy, dusky red lesions of 2 weeks' duration that started on the trunk and then spread to the legs and arms. There was no history of preceding fever, sore throat, arthralgia, recent drug intake, or any systemic complaints. Cutaneous examination revealed multiple, 1-6 cm sized round to oval, purpuric, maculopapular lesions over the trunk, arms, thighs and legs (Figure 1). Many lesions were annular with mildly raised erythematous margins and flat rust-colored centers with mild scaling (Figure 2). A herald patch was not discernable. Mucosal and systemic examinations were normal. Four millimeter skin biopsy obtained from the annular patch revealed compact hyperkeratosis, epidermal spongiosis, superficial perivascular lymphohistiocytic infiltrate and erythrocyte extravasation (Figure 3). Laboratory evaluation including complete blood count, hepatic and renal function tests, coagulation studies, anti-streptolysin antibody, VDRL, serology for HIV, and urinalysis revealed no abnormality. The patient was started on oral antihistamines and emollients. Over the next 4 weeks, new lesions developed and pruritus increased for which she was given 1% hydrocortisone acetate cream for twice-a-day and systemic steroid (10mg daily, 10 days). All lesions cleared completely in the next two weeks without any recurrence.

Keywords: Pityriasis rosea, Purpuric, Atypic

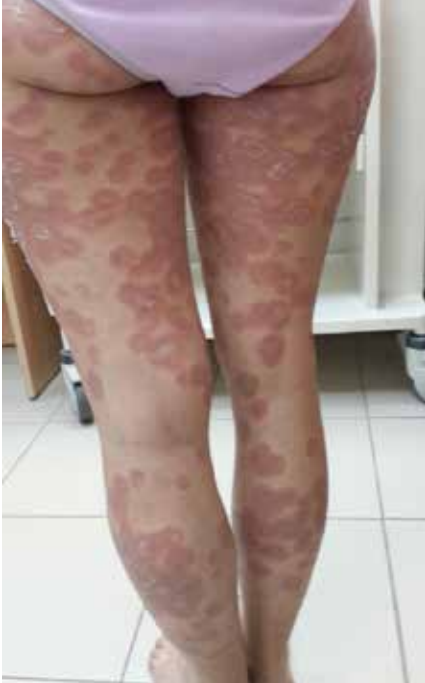

3rd INDERCOS

National Dermatology & Cosmetology Congress with International Participants

14-17 MARCH, 2018
HILTON ISTANBUL BOSPHORUS HOTEL
ISTANBUL, TURKEY

Figure 1



3rd INDERCOS

National Dermatology & Cosmetology Congress with International Participants

14-17 MARCH, 2018
HILTON ISTANBUL BOSPHORUS HOTEL
ISTANBUL, TURKEY



PP-105

[ADVERSE DRUG REACTIONS, TEN]

PITYRIASIS ROSEA-LIKE ERUPTION INDUCED BY ETANERCEPT

Emin Ozlu¹, Safinaz Ataoglu², Yunus Ozcan¹, Mehmet Gamsızkan³, Ebru Karagun¹

¹Düzce Üniversitesi, Tıp Fakültesi, Dermatoloji, Düzce,Türkiye

²Düzce Üniversitesi, Tıp Fakültesi, Fizik Tedavi ve Rehabilitasyon, Düzce,Türkiye

³Düzce Üniversitesi, Tıp Fakültesi, Patoloji, Düzce,Türkiye

INTRODUCTION: Pityriasis rosea is a benign and self-limited exanthema of unknown etiology. Various infectious agents and drugs are commonly accused. Etanercept is a tumor necrosis alpha antagonist drug that used in the treatment of dermatologic and rheumatologic diseases. Various cutaneous and systemic side effects have been reported during the use of etanercept.

CASE: A 62 year-old-woman presented at our clinic with erythematous maculopapular rash located on the trunk and extremities that had been present for one week. From the medical history, the patient had been on follow-up due to RA for the last 12 years and had been receiving systemic corticosteroids for the last 8 years. The dermatological examination revealed asymptomatic, pinkish-reddish, multiple, mildly scaly, 0.5-2 cm in diameter maculopapular lesions located in the trunk, upper and lower extremities. His complaints had developed after the sixth course of etanercept treatment. A skin biopsy was taken from maculopapular lesion and clinical, histopathological findings were compatible with the diagnosis of pityriasis rosea-like drug eruption. Etanercept treatment was discontinued. She was started on topical 0.1% mometasone furoate and after 4 weeks lesions were mostly cleared up.

DISCUSSION: Pityriasis rosea-like eruption is often overlooked in daily practice. It should be kept in mind that pityriasis rosea-like eruption could also develop following the use of etanercept.

Keywords: Pityriasis rosea, drug eruption, etanercept.



3rd INDERCOS

National Dermatology & Cosmetology Congress with International Participants

14-17 MARCH, 2018
HILTON ISTANBUL BOSPHORUS HOTEL
ISTANBUL, TURKEY

PP-106

[SYSTEMIC TREATMENT]

PARTIAL RESPONSE TO METHOTREXATE IN A PATIENT WITH PRURIGO NODULARIS

Hilal Kaya Erdoğan, Esra Ağaoğlu, Ersoy Acer, Zeynep Nurhan Saraçoğlu

Eskişehir Osmangazi Üniversitesi, Deri ve Zührevi Hastalıkları Anabilim Dalı, Eskişehir

Prurigo nodularis is a common, chronic, inflammatory disease of the skin which affects quality of life. It is usually seen as multiple, firm, flesh to pink colored nodules on the extensor surfaces of the extremities. Therapeutic approaches of prurigo such as topical corticosteroids, oral antihistaminics, moisturizing ointments and phototherapy may be non-effective. Methotrexate is a folic acid antagonist widely used in the management of various dermatological diseases. A 28 years old woman admitted to our clinic with pruritic lesions on arms and legs. She had received topical, intralesional and systemic steroids, oral antihistaminics, systemic cyclosporine, narrow band phototherapy and omalizumab at different times; but had no benefit. Her medical history was unremarkable. Dermatologic examination revealed erythematous, excoriated papules and nodules located on arms, legs and groins (Figure 1). Histopathological examination of the punch biopsy obtained from the right leg was consistent with prurigo nodularis. She was treated with gabapentin (900 mg/day, for 3 months); but in follow up her complaints did not decreased. Subcutaneous methotrexate 15 mg per week was started. The lesions and the pruritus partially regressed in 3 months (Figure 2). No side effect was seen during the treatment. Herein, we present a 28 years old woman with prurigo nodularis who is resistant to conventional therapies and treated with systemic methotrexate.

Keywords: prurigo nodularis, methotrexate, therapy

3rd INDERCOS

National Dermatology & Cosmetology Congress with International Participants

14-17 MARCH, 2018
HILTON ISTANBUL BOSPHORUS HOTEL
ISTANBUL, TURKEY



Figure 1

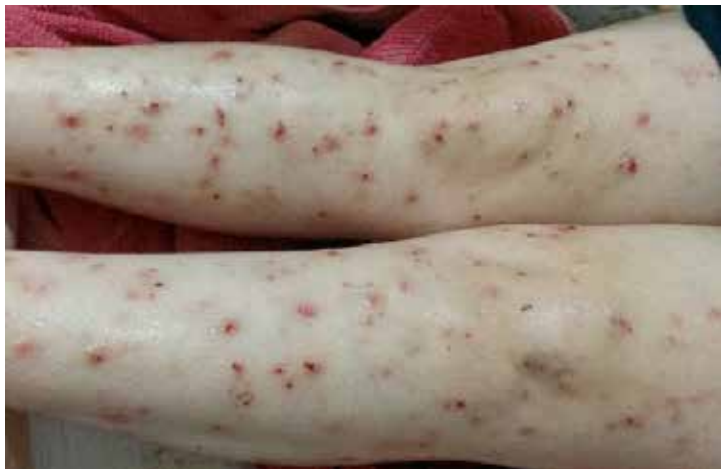
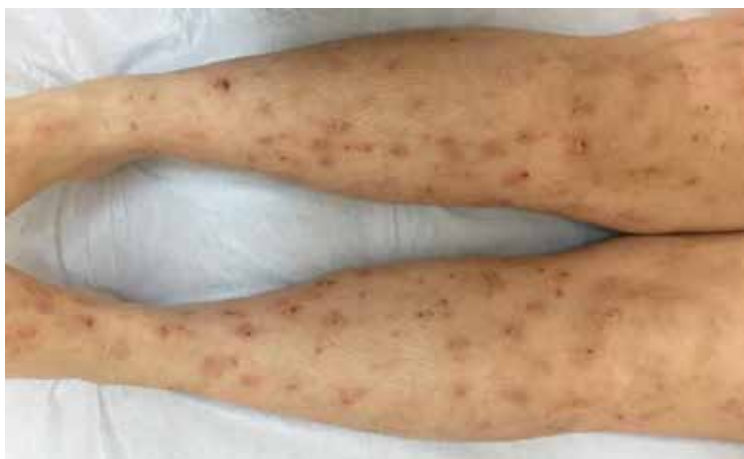
Figure 2



PP-107

[INFLAMMATORY SKIN DISEASES]

PYODERMA GANGRENOSUM AT THE SITE OF SUBCUTANEOUS INJECTION OF GOLIMUMAB IN A PATIENT WITH ANKYLOSING SPONDYLITIS

Zennure Takci¹, Akgül Arıcı², Atiye Ogrum¹, Havva Yıldız Seçkin¹

¹Department of Dermatology, Faculty of Medicine, Gaziosmanpaşa University, Tokat, Turkey

²Department of Pathology, Faculty of Medicine, Gaziosmanpaşa University, Tokat, Turkey

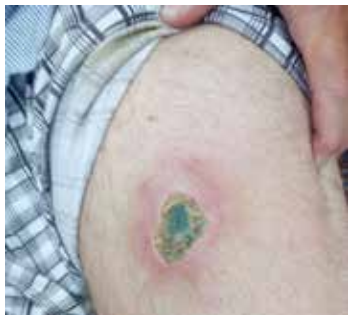INTRODUCTION: Pyoderma gangrenosum (PG) is an inflammatory disease characterized by painful ulcerations. It is often associated with other systemic inflammatory diseases, especially inflammatory bowel disease and autoimmune arthritis. Golimumab, a fully human anti-TNF monoclonal antibody, is approved for the treatment of ulcerative colitis, rheumatoid arthritis, ankylosing spondylitis and psoriatic arthritis. We report the case of a patient with ankylosing spondylitis who developed PG at the site of subcutaneous injection of golimumab.

CASE: A 43-year-old man presented with a painful leg ulcer for two months. The patient had a past history of ankylosing spondylitis and therapy with golimumab 50 mg which was administered subcutaneously to the front of middle thighs every 4 weeks. The patient stated that a painful erythematous swelling occurred 3 days after the last injection (fourth month of treatment) at the sites of subcutaneous injection of golimumab. Initially it was misdiagnosed as soft tissue infection and treated with a broad-spectrum antibacterial agent without any relief. Over time the lesion progressed into infiltrated and ulcerated purplish plaque and symptoms worsened. The golimumab treatment was interrupted by the rheumatologist and the patient was directed to our out-patient clinic. We observed an ulcer (2 x 3 cm) on the front of her left thigh, the bottom of which contained a yellow necrotic substance on an erythematous base (Fig. 1). Bacterial, fungal and mycobacterial cultures of debrided tissue were negative. Histopathological examination identified a neutrophilic infiltration in dermis. Considering these results, a diagnosis of PG was made.

DISCUSSION: Pathergy phenomenon is one of the characteristic features of PG. Over the past decade, new biologic medications such as infliximab, adalimumab and etanercept have been promising new treatment options for patients with immune-mediated diseases including PG. In this case it is unclear whether PG was triggered by golimumab or it developed on the basis of pathergy phenomenon.

Keywords: Pyoderma gangrenosum, golimumab, pathergy phenomenon

Figure 1



An ulcer covered by yellow fibrinoid necrotic material on an erythematous base

3rd INDERCOS

National Dermatology & Cosmetology Congress with International Participants

14-17 MARCH, 2018
HILTON ISTANBUL BOSPHORUS HOTEL
ISTANBUL, TURKEY



PP-108

[CUTANEOUS ONCOLOGY]

A CASE OF CYSTIC BASAL CELL CARCINOMA ORIGINATE FROM NOSE

Selami Aykut Temiz¹, Ilkay Özer¹, Arzu Ataseven¹, Recep Dursun¹, Siddika Findik²

¹Department of Dermatology, Necmettin Erbakan University Meram Faculty of Medicine, Konya, Turkey

²Department of Pathology, Necmettin Erbakan University Meram Faculty of Medicine, Konya, Turkey

Basal cell carcinoma (BCC) is the most common of all malignancies, and BCC is found in 65-80% frequency among non-melanoma skin malignancies. It is derived from the basal layer of the epidermis from pluripotent epithelial cells and hair follicles. Due to the density of pilosebaceous glands and sun exposure, BCC is found in approximately 80% of the head and neck region. BCC can be classified into 11 subtypes including nodular, superficial, infiltrative, fibroepithelial, keratotic, metatypical, pigmented, adenoid, morphiform / sclerosing, basosquamous and type of showing sebaceous differentiation, nodular type is most common with 60%. Cystic BCC is a rare variation of the nodular type.

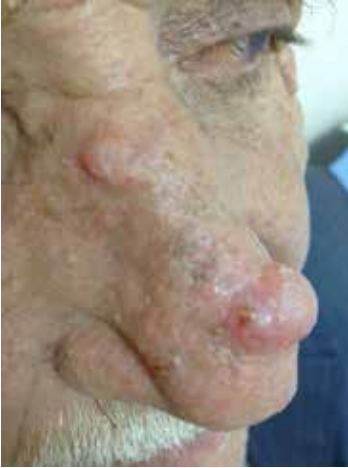A 69-year-old male patient appealed to a cystic lesion at the tip of the nose. On the dermatological examination telangiectatic structures were found on the lesion at the tip of the nose, there was extensive solar damage to the skin. On his dermatoscopic examination, there were short-twisted veins and blue-gray oval spots on the cystic lesion. Cystic BCC was considered based on clinical and dermatoscopic examination. Histological finding showed tumor masses mostly on the dermis with continuation from the epidermis in some parts. The tumor contains cystic spaces. Clefts between the stroma and tumor edge are seen. Palisading of the basaloid cells at the peripheral sites of the tumor masses is noticed. There was no skin cancer story in the family story. It was found that there was no other predisposing factor (arsenic, chemical carcinogen, radiation, thermal or chemical burn, chronic trauma) in terms of bcc except for sun exposure.

Basal cell carcinoma is common in dermatology practice, in addition epidemiological data suggest that the incidence of BCC is increasing worldwide. It has been reported that the average lifetime risk of developing BCC in white race is 30%. Nodular type is the most common type (60%), subspecies of this; solid, keratotic, cystic and adenoid types. In our case, there was cystic type nodular BCC. Histopathological subtype is the most critical factor when treatment is determined for BCC, dermoscopy has been proven to provide important information prior to pathologic examination to predict BCC subtype. Most of the cases of nodular cystic BCC can be completely treated with surgical excision, as they may know the surgical margin.

We wanted to present the cystic bcc (a rare form of nodular bcc) case because of dermoscopy to draw attention to the differential diagnosis and the importance of directing the surgery.

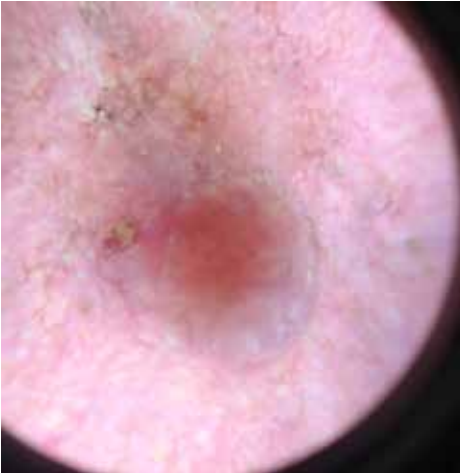Keywords: Cystic basal cell carcinoma, dermoscopy, non-melanoma skin cancer

Figure 1



Dermatological examination telangiectatic structures were found on the lesion at the tip of the nose

Figure 2



On his dermatoscopic examination, there were short-twisted veins and blue-gray oval spots on the cystic lesion

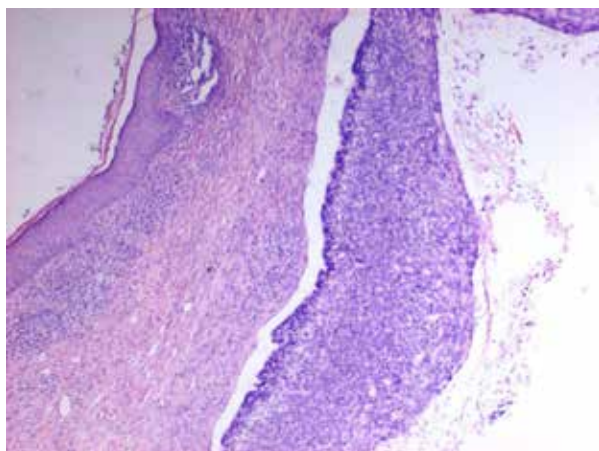
3rd INDERCOS

National Dermatology & Cosmetology Congress with International Participants

14-17 MARCH, 2018
HILTON ISTANBUL BOSPHORUS HOTEL
ISTANBUL, TURKEY



Figure 3



Histological finding showed tumor masses mostly on the dermis with continuation from the epidermis in some parts. The tumor contains cystic spaces. Clefts between the stroma and tumor edge are seen. Palisading of the basaloid cells at the peripheral sites of the tumor masses is noticed.



3rd INDERCOS

National Dermatology & Cosmetology Congress with International Participants

14-17 MARCH, 2018
HILTON ISTANBUL BOSPHORUS HOTEL
ISTANBUL, TURKEY

PP-109

[INFLAMMATORY SKIN DISEASES]

WOLF'S ISOTOPIC RESPONSE: A CASE OF MORPHEA ARISING AT THE SITE OF HEALED HERPES ZOSTER

Onur Karaağaç¹, Recep Dursun¹, Arzu Ataseven¹, İlkay Özer¹, Zehra Edebal²

¹Department of Dermatology, Meram Faculty of Medicine, Necmettin Erbakan University, Konya, Turkey

²Department of Pathology, Beyhekim State Hospital, Konya, Turkey

Wolf's isotopic response defines the occurrence of a new, unrelated disease that appears at the same location as a previously healed skin disease. Although the most common primary skin disease of this phenomenon is herpes virus infection (zoster or simplex), there are a significant number of cases in which other skin disorders precede the second disease. Several cases of isotopic response have been described and published in the literature. They have been classified as granulomatous reactions, malignant tumors, leukemic or lymphomatous infiltrations, dysimmune reactions, infections, comedonic-microcystic reactions and other miscellaneous conditions. The largest group was granulomatous reactions, mostly granuloma annulare. A few morphea cases have been reported. In this article, we present a case of morphea arising at the site of healed herpes zoster. A 30-year-old female who apply to our dermatological department with 10-month history of hyperpigmented, indurated plaque on the right breast. The patient complained of a painful, itchy eruption in the same area one year ago and had been diagnosed as herpes zoster. She had been treated with oral antiviral drugs, topical antibiotic, and analgesics. The lesions had resolved three weeks after the onset of the eruption. Two months after the complete resolution of herpes zoster, new indurated plaque had arisen at the site of healed herpes zoster. On the clinical examination shiny, slightly hyperpigmented, indurated oval plaque were observed on the lateral side of the right breast that match to the site of the healed herpes zoster. Laboratory tests were within normal ranges. Serological test for *Borrelia burgdorferi* was negative. Serology for varicella zoster virus tested negative for IgM but positive for IgG. Histopathological examination revealed hyperkeratosis and thick bundles of collagen in dermis. Eccrin glands trapped between collagen bundles and lymphoplasmacytic inflammation at dermal subcutaneous junction were observed. Consequently, our case was consistent with morphea as an expression of Wolf's isotopic response following herpes zoster. A few morphea cases developing at the side of healed herpes zoster have been reported. Here, we aimed to report an additional case of this rare isotopic response following herpes zoster.

Keywords: Wolf's isotopic response, morphea, herpes zoster

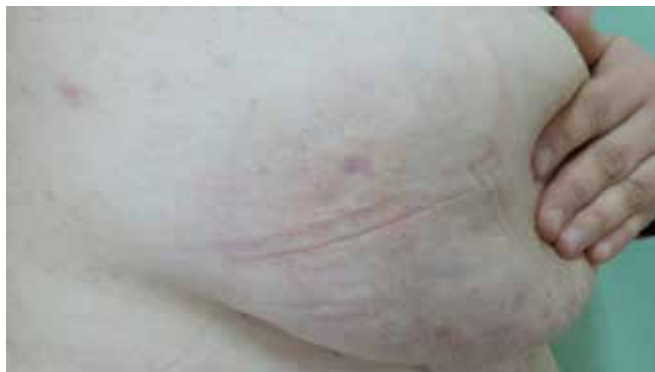3rd INDERCOS

National Dermatology & Cosmetology Congress with International Participants

14-17 MARCH, 2018
HILTON ISTANBUL BOSPHORUS HOTEL
ISTANBUL, TURKEY

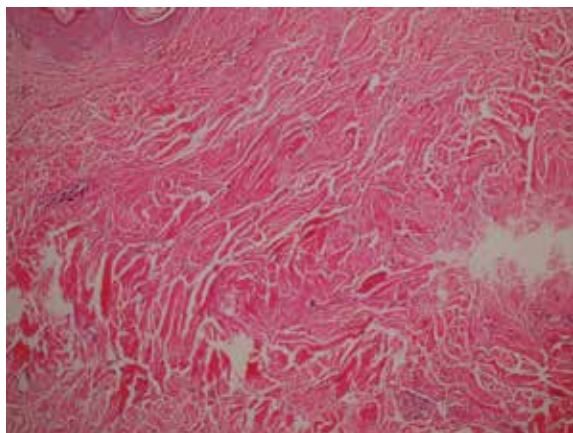


Figure 1



Shiny, slightly hyperpigmented, indurated oval plaque on the lateral side of the right breast, corresponding to the site of the healed herpes zoster

Figure 2



Thick bundles of collagen in dermis, absent of appendages (H&E stain, x100)



3rd INDERCOS

National Dermatology & Cosmetology Congress with International Participants

14-17 MARCH, 2018
HILTON ISTANBUL BOSPHORUS HOTEL
ISTANBUL, TURKEY

PP-110

[MISCELLANEOUS]

A CASE OF PLANE XANTHOMA WITH HYPERCHOLESTEROLEMIA ON THE FACE

Sertaç Şener¹, Fadime Kılınç¹, Ayşe Akbaş¹, Nuran Süngü Adıyaman², Akın Aktaş³

¹Ataturk Training and Research Hospital, Dermatology Clinic, Ankara, Turkey

²Yildirim Beyazıt University, Medical Faculty, Department of Pathology, Ankara, Turkey

³Yildirim Beyazıt University, Medical Faculty, Department of Dermatology, Ankara, Turkey

Cutaneous xanthomas occur as a result of intracellular and dermal lipid deposit. They are often associated with disorders of the lipid metabolism. There are many classifications for xanthomas including clinical appearance and relation of lipid metabolism. Normolipidemic xanthomas often appear as diffuse flat lesions while hyperlipidemic ones are generally polymorphous. Our case was a hyperlipidemic 58 year-old woman with xanthoma planum on her cheeks for 6 years. She was presented yellowish, hyperpigmented, diffuse, plane plaques on both sides. Her plasma cholesterol and LDL levels were high. Histopathological findings confirmed the clinical diagnosis.

Keywords: face, hypercholesterolemia, xanthoma

3rd INDERCOS

National Dermatology & Cosmetology Congress with International Participants

14-17 MARCH, 2018
HILTON ISTANBUL BOSPHORUS HOTEL
ISTANBUL, TURKEY



PP-111

[ALLERGOLOGY AND IMMUNOLOGY]

EVALUATION OF THE SKIN PATCH TEST RESULTS IN CASES OF ALLERGIC CONTACT DERMATITIS

Zerrin Ogretmen, Alper Ekinci

Faculty of Medicine, Department of Dermatology, Çanakkale Onsekiz Mart University, Türkiye

OBJECTIVE: Detecting the causative agent in the patients of allergic contact dermatitis is as important as the treatment given for the allergic situation. Skin patch test is performed to detect the sensitizing agent. According to the results of studies, the most common causative substances may differ for varied geographic regions. We aimed to determine the most common causative agents of allergic contact dermatitis in our region.

MATERIALS-METHODS: 54 cases who applied to our clinic with the diagnosis of allergic contact dermatitis and who had been tested with the standardized European serial (TRUE) test between the years of 2015 - 2018 were included in this study.

RESULTS: 37 (%69) of the cases were female and 17 (%31) of the cases were male. The mean age of the cases was 31,745. According to the TRUE test results, 17 of the cases (%31) had positive result for 1 substance, 8 of the cases (%15) had positive results for 2 substances, 4 of the cases (%7) had positive result for 3 substances, 1 of the cases (%2) had positive results for 4 substances, 1 of the cases (%2) had positive results for 5 substances. 23 of the cases (%43) had no positive test result for the substances which were included in the TRUE test. 14 of the cases (%26) were positive to Nickel, 4 of the cases (%7) were positive to Cobalt, 4 of the cases (%7) were positive to Thiomersal, 2 of the cases (%4) were positive to Colophony.

CONCLUSION: 3 studies which were operated in the different regions of our country (Hatay - the Mediterranean region, Sivas - the mid - Anatolian region and Istanbul - the Marmara region) had evaluated the results of the skin patch test in the cases of allergic contact dermatitis. In Hatay, the first, second and third most common sensitizing agents were found to be Nickel, Potassium dichromate and Cobalt, respectively. In Sivas, the first, second and third most common sensitizing agents were found to be Nickel, Cobalt and Potassium dichromate, respectively. In Istanbul, the first, second and third most common sensitizing agents were found to be Nickel, Potassium dichromate and Fragrance mix, respectively. In respect to these evaluations, the most common sensitizing agent in overall of our country was Nickel and the second and the third most common sensitizing agents were Potassium dichromate and Cobalt, respectively. In our study, Nickel (%26) was the most common sensitizing agent and Cobalt (%7) and Thiomersal (%7) were the second most common sensitizing agents. The results of our study is coherent with the results of other skin patch test studies in our country.

Keywords: Skin patch test, allergic contact dermatitis, TRUE test



3rd INDERCOS

National Dermatology & Cosmetology Congress with International Participants

14-17 MARCH, 2018
HILTON ISTANBUL BOSPHORUS HOTEL
ISTANBUL, TURKEY

PP-112

[CUTANEOUS ONCOLOGY]

MYCOSIS FUNGOIDES PRESENTING AS SYMMETRIC CONCENTRIC PATCHES MIMICKING FIGURATE ERYTHEMA WITH DERMOSCOPIC FINDINGS

Ilkin Zindanci¹, Melike Kibar Öztürk¹, Fatıma Gürsoy², Ebru Zeemheri²

¹Department of Dermatology, Sağlık Bilimleri University, Umranıye SUAM Training and Research Hospital, Istanbul, Turkey

²Department of Pathology, Sağlık Bilimleri University, Umranıye SUAM Training and Research Hospital, Istanbul, Turkey

A 52-year-old female presented to outpatient dermatology clinic for evaluation of a 3-year history of a persistent rash that appeared, erythematous annular patches on her anterior wall of abdomen. The lesions gradually expanded in concentric rings with scale over several months. A punch biopsy from the leading edge of a lesion found a n epidermal and dermal atypical lymphocytic infiltrate with epidermotropism and diagnosis was made as mycosis fungoides (MF). Dermoscopic pattern of this early lesion was consisting of fine short lineer vessels (on the right side) and orange-yellowish patchy areas with fine scales. On the other hand, chronic dermatitis like chronic forms of figurate erythemas were typified by a different dermoscopic pattern, usually consisting of dotted vessels. Nowadays MF is called as "great imitator". It may present with atypical clinical manifestations. Usually it mimics various chronic dermatoses. Rarely, MF can be presenting similarly to figurate erythemas as annular or polycyclic plaques. We want to present this case because of rarity and to emphasize the importance of dermoscopy in differential diagnosis

Keywords: mycosis fungoides, great imitator, dermoscopy, figured erythema

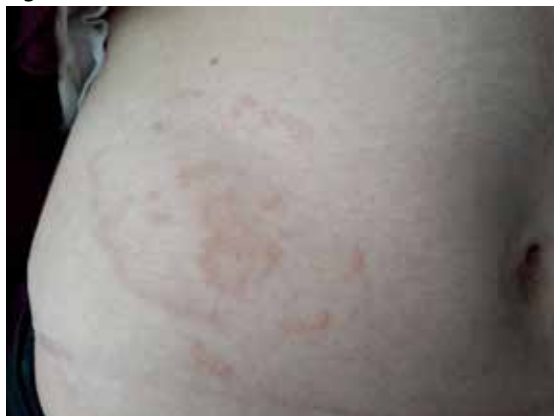3rd INDERCOS

National Dermatology & Cosmetology Congress with International Participants

14-17 MARCH, 2018
HILTON ISTANBUL BOSPHORUS HOTEL
ISTANBUL, TURKEY

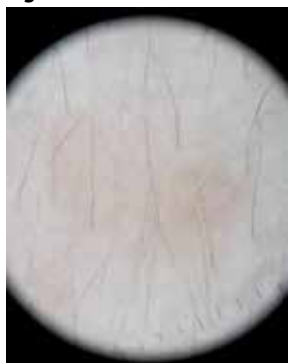

Figure 1



Clinical appearance of the lesion

Figure 2



Dermoscopy of the lesion



3rd INDERCOS

National Dermatology & Cosmetology Congress with International Participants

14-17 MARCH, 2018
HILTON ISTANBUL BOSPHORUS HOTEL
ISTANBUL, TURKEY

PP-113

[INFECTIOUS DISEASES, PARASITIC DISEASES, INFESTATIONS]

UNEXPECTED LOCALIZATION OF TUBERCULOSIS CUTIS VERRUCOSA: CASE REPORT

Selami Aykut Temiz¹, İlkay Özer¹, Arzu Ataseven¹, Recep Dursun¹, Mustafa Cihat Avunduk²

¹Department of Dermatology, Necmettin Erbakan University Meram Faculty of Medicine, Konya, Turkey

²Department of Pathology, Necmettin Erbakan University Meram Faculty of Medicine, Konya, Turkey

Skin tuberculosis, a chronic and granulomatous disease, occurs in a variety of clinical forms depending on the route of entry, the immunological response of the site, the number of bacilli and virulence. Cutaneous tuberculosis (tbc) is seen in less than 2% of all tuberculosis cases. Most cases of cutaneous tbc are endogenous forms (lupus vulgaris, scrofuloderma, metastatic tuberculosis abscess, acute miliary tuberculosis, or tubular tuberculosis), that is the form that the bacillus comes from another location in the body and the minor part is exogenous forms (tbc primer complex, tuberculosis cutis verrucosa). Tbc cutis verrucosa (TBVC) occurs in people who have previously contracted tuberculosis with intact immunity.

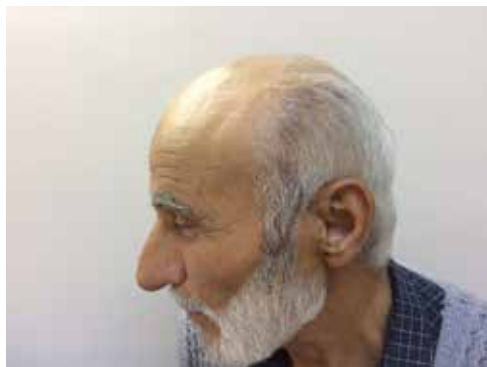A 68-year-old man was admitted with a complaint of verrucous plaques located in the right temporal region as a sporotrichoid for two months. At the external dermatology clinics, the lesions were performed by cryosurgery number of times with the diagnosis of verruca. Skin biopsy was performed with preliminary diagnoses of TBVC, hypertrophic lichen planus, seborrheic keratosis, verruca vulgaris, lipid proteinosis. Histopathologic examination result; granulomatous structures characterized by infiltration of inflammatory cells around the keratin plugs and giant multinuclear cells deep in the epithelium were observed. Positive expression with CD68 was detected. The histopathological diagnosis was TBCV. The case was consulted pulmonary medicine for pulmonary tuberculosis research, PPD test was positive 11 mm and no pathology was detected in PAAG. Thus no primary focus was found which would lead to lymphogenous or hematogenous spreading. There was no tuberculosis in his family medical history. The patient did not belong to any of the occupational groups at risk for tuberculosis. The lesions of the patient were regressed after two months of quadruple anti-tbc and four months of double anti-tbc treatment.

TBCV may be confused with verrucas. As a result, TBVC should be considered in the differential diagnosis of verrucal lesions, inflammatory purple ring around them, absence of Auspitz phenomenon seen in the lesions and unresponsiveness to the given wart treatment.

We wanted to present here a case of tbc cutis verrucosa with temporal location because of a rare variant of cutaneous tuberculosis.

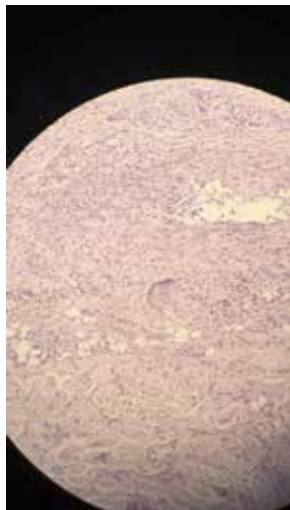
Keywords: Skin tuberculosis, tuberculosis cutis verrucosa, verrucous lesions, cryosurgery

Figure 1



Verrucous plaques located in the right temporal region as a sporotrichoid

Figure 2



Multinucleated giant cells in periodic acid-schiff [PAS] stain x20

Figure 3



CD68 staining



3rd INDERCOS

National Dermatology & Cosmetology Congress with International Participants

14-17 MARCH, 2018
HILTON ISTANBUL BOSPHORUS HOTEL
ISTANBUL, TURKEY

PP-114

[CUTANEOUS ONCOLOGY]

BLASTIC PLASMACYTOID DENDRITIC CELL NEOPLASM, WIDESPREAD CUTANEOUS INVOLVEMENT, CASE REPORT

Ebru Zemheri¹, Begüm Çalım¹, İlkin Zindancı², Melike Kibar Oztürk²

¹Department of Pathology, Sağlık Bilimleri University, Umraniye SUAM Training and Research Hospital, Istanbul, Turkey

²Department of Dermatology, Sağlık Bilimleri University, Umraniye SUAM Training and Research Hospital, Istanbul, Turkey

Blastic plasmacytoid dendritic cell neoplasm (BPDCN) is a aggressive and rare tumor. It frequently presents as cutaneous lesions and subsequently progresses to bone marrow and lymph node involvement. BPDCN is a rare entity that categorized by different neoplasm according to the 2016 World Health Organization classification.

We reported the case of a 67-year-old male who presented with pancytopenia, and with widespread cutaneous involvement. On dermatological examination, multiple, purple-red nodules and plaques were seen, mainly on the back, and chest. Biopsies taken from skin and bone marrow revealed CD4+, CD56+, CD123+ blastic plasmacytoid neoplasm. The patient progressed rapidly and died shortly after despite aggressive chemotherapy. We present our patient with BPDCN because of a distinct and rare entity and widespread cutaneous involvement.

Keywords: Plasmacytoid, dendritic cell, neoplasm

3rd INDERCOS

National Dermatology & Cosmetology Congress with International Participants

14-17 MARCH, 2018
HILTON ISTANBUL BOSPHORUS HOTEL
ISTANBUL, TURKEY



PP-115

[PAEDIATRIC DERMATOLOGY]

CUTIS MARMORATA TELANGIECTATICA CONGENITA IN A FEMALE NEWBORN: CASE REPORT

Ezgi Özkur¹, İlknur Altunay¹, Tuğba Falay²

¹Health Science University, Şişli Hamidiye Etfal Training and Research Hospital, Dermatology Department

²Health Science University, Sultan Abdülhamid Han Training and Research Hospital, Dermatology Department

Cutis marmorata telangiectatica congenita (CMTC) is an uncommon congenital sporadic vascular anomaly that usually present at birth. Various anomalies being associated with CMTC has been investigated since the description of this condition. The rate of anomalies reported in association with CMTC varies between 18.8% and 70% in current literature. Our patient is a female newborn spontaneously delivered at 38 weeks, 2600gram. Apgar score was 9-9 at 1' and 5' minutes of life respectively and family medical history was noncontributory. Physical examination revealed marbled brownish and deep purple reticulated skin lesions involving the right leg. She was otherwise healthy with head circumference 75 percentile, birth weight and length 50 percentile without other vascular anomalies or asymmetry of limbs growth. Neurological and ophthalmological examination was normal. Although it is a benign disorder which tends to self limiting; a complete detailed examination and multidisciplinary follow-up should be assessed in order to evaluate related abnormalities and distinguish from other conditions that may mimic CMTC like Klippel-Trenaunay syndrome, Sturge-Weber syndrome, Adam-Oliver syndrome, Bockenheimer's hastalığı. Annual follow-up at least 3 years is necessary for screening affected patients for the presentation of associated anomalies.

Keywords: cutis marmorata, cutis marmorata telangiectatica congenita, vascular anomaly

PP-116

[INFECTIOUS DISEASES, PARASITIC DISEASES, INFESTATIONS]

A CASE OF GENERALIZED PHTHIRUS PUBIS

Mustafa Aksoy¹, Yavuz Yeşilova², Ulaş Güvenç³, Mehmet Bayraktar⁴

¹Department of Dermatology and Venereology, Harran University, Sanliurfa, Turkey

²Department of Dermatology, Special Lokman Physician, Van, Turkey

³Department of Dermatology, Special Güvenc Beauty and Wellness Center, Mersin, Turkey

⁴Department of Medical Microbiology, Harran University, Sanliurfa, Turkey

Pediculosis pubis is the infestation of hair-covered areas. The clinical manifestation, in which Phthirus pubis is the pathogen, is typically seen in the upper part of the pubis, abdomen and femoral region. Itching, papular urticaria and excoriations which may vary from mild to moderate are observed clinically. It is spread from person to person by close physical contact such as sleeping in the same bed or sexual intercourse. Here, we presented a 45-year-old male patient with pediculosis pubis which started from the inguinal area and spread to the whole body, leading to generalized pruritus, and we aimed to draw attention to the fact that phthirus pubis infestation may be generalized.

Keywords: Phthirus pubis, generalised, pediculosis pubis

1: Clinic photos

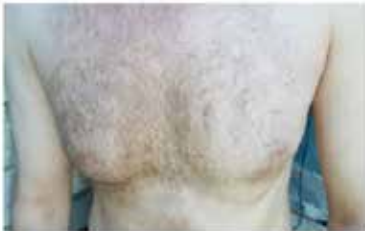
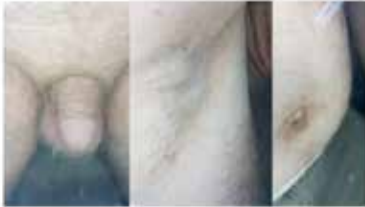
Figure 1: Numerous yellowish brown papular lesions in the pubic region, axillary region and abdomen.

Numerous yellowish Brown papular lesions in the pubic region, axillary region and abdomen.

2: Microscopic photo

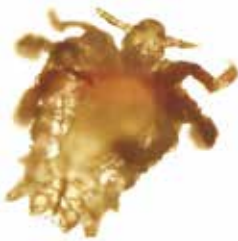

Figure 2: Microscopic photo: ptythirus pubis parasitica, 1-2 mm in length, yellowish brown in color, with antenna, round body, three pairs of legs. Magnification, X10.

Microscopically, ptythirus pubis parasitica, 1-2 mm in length, yellowish brown in color, with antenna, round body, three pairs of legs. Magnification, X10.

3rd INDERCOS

National Dermatology & Cosmetology Congress with International Participants

14-17 MARCH, 2018
HILTON ISTANBUL BOSPHORUS HOTEL
ISTANBUL, TURKEY



PP-117

[AUTOIMMUNE BULLOUS DISEASES]

PEMPHIGUS HERPETIFORMIS

*Mirjana Milosavljevic, Mirjana Paravina, Sanja Milosavljevic
Dermatovenerology practise "Bella Medica Centar", Niš, Serbia*

INTRODUCTION: Pemphigus herpetiformis is a rare autoimmune bullous skin disorder. It combines the clinical features of dermatitis herpetiformis with the immunopathologic features of pemphigus. P.H. is a clinical variant of pemphigus. The prognosis for P.H. usually is excellent and it is associated with significant pruritus. The severe pruritus is noted in approximately one half of patients affected with P.H. P.H. appears to be mediated by the immunoglobulin class of autoantibodies that target the skin epidermis desmoglein components (a desmosomal component predominantly located in the lower epidermis).

CASE REPORT: Our patient affected with P.H. is 35 years old with erythematous, vesicular, bullous and papular lesions, which is demonstrated as a "herpetiform" pattern and manifested as a cluster of blisters on an inflammatory base. Distribution is typically generalized and most prominent on trunk and limbs, with no oral mucosal involvement.

SKIN BIOPSY: DIF (direct immunofluorescence) detects the presence of IgG with C3 deposition around cell surfaces of keratinocytes in patient's skin. IIF (indirect immunofluorescence) presence in patient's serum IgG - circulating autoantibodies that bind to epidermal cell surfaces.

TREATMENT: Our patient was treated with systemic steroids (0.5-1.0mg/kg of Prednisone).

CONCLUSION: The patient normally responds to our treatment, with a tendency to complete remission even with the use of low doses of corticosteroids. Dapsone can give good results if it is used as monotherapy or in combination with systemic steroids.

Keywords: Pemphigus herpetiformis, erythematous lesions, vesicular lesions.

PP-118

[CUTANEOUS ONCOLOGY]

A CASE OF SOLITARY CUTANEOUS INFLAMMATORY PSEUDO-TUMOUR

Sertaç Şener¹, Fadime Kılınc¹, Ayşe Akbaş¹, Aydan Kılıçarslan², Akın Aktaş³

¹Ataturk Training and Research Hospital, Dermatology Clinic, Ankara, Turkey

²Yildirim Beyazıt University, Medical Faculty, Department of Pathology, Ankara, Turkey

³Yildirim Beyazıt University, Medical Faculty, Department of Dermatology, Ankara, Turkey

Pseudo-inflammatory tumours are poorly defined neoplasms. They have highly variable proliferations of myofibroblastic cells associated with a prominent inflammatory infiltrate. They may develop at almost any site of the body such as lungs, bladder, gastrointestinal system and, rarely limited to the skin. Our case who is a 62 year-old man presented with an erythematous nodule of one cm diameter on the glabella for two months. The diagnosis was confirmed as solitary cutaneous inflammatory pseudo-tumour histopathologically and the lesion was excised surgically.

Keywords: cutaneous, neoplasm, pseudo-tumour



3rd INDERCOS

National Dermatology & Cosmetology Congress with International Participants

14-17 MARCH, 2018
HILTON ISTANBUL BOSPHORUS HOTEL
ISTANBUL, TURKEY

PP-119

[ANGIOLOGY, HAEMANGIOMAS, VASCULAR MALFORMATIONS, VASCULITIS] AUTOERYTHROCYTE SENSITIZATION SYNDROME PRESENTING WITH GENERAL PRURITUS

Emel Bülbül Başkan, Eda Haşal

Department of Dermatology, Uludag University Medical Faculty, Bursa, Turkey

Autoerythrocyte sensitization syndrome (AES) is an autoimmune vasculopathy with sensitization to phosphatidylserine, a component of erythrocyte stroma. AES usually develops after psychological stress and is characterized by induced or spontaneous development of painful inflammatory skin lesions progressing to ecchymoses(1). Here we introduce a 79-year-old woman presenting with 2-month-old pruritus with bruising on the trunk and extremities.

A 79-year-old woman presented with a 2-month history of pruritus over her arms and trunk. The patient complained that the bruises appeared after scratching the skin to relieve pruritus. There was a history of hypertension in her medical records and she was using atenolol. She gave no history of bleeding tendencies or any underlying psychiatric illnesses. Cutaneous examination revealed livedo reticularis at lower extremities, xerosis cutis and a few ecchymotic patches over bilateral arms, non-tender on palpation. Rest of mucocutaneous, general and systemic examination was normal. Complete hemogram, platelet count, complete coagulation profile and antinuclear antibodies done to rule out other causes of purpuras and livedo reticularis were within normal limits. Intradermal injection of 0.1 ml of autologous blood on flexure aspect of right forearm was performed. Approximately 24 hours later, the patient developed an oval, 2 cm, sharply defined ecchymosed macule (picture 1). Intradermal injection of 0.1 ml of saline used as a control on the left arm caused no reaction. Based on clinical and laboratory findings a final diagnosis of Gardner–Diamond syndrome was made. As psychiatric associations are frequent, patient consulted for detailed psychiatric evaluation.

Autoerythrocyte sensitization syndrome, also known as Gardner–Diamond syndrome (painful bruising syndrome or psychogenic purpura), is a rare disorder first described by Gardner and Diamond in 1955(2). Only around 162 cases are described since then. Auto-sensitization of patients to their own blood, mainly to phosphatidylserine plays an important role in the pathogenesis. There are no disturbances in the blood coagulation system or abnormalities of vessel walls(3). Prognosis of AES is generally good with no reported fatalities. There is no effective treatment in this disease.

This condition should be kept in mind as a differential diagnosis of recurrent purpura. Timely and correct diagnosis helps to avoid exhaustive investigations and aggressive treatment.

Keywords: Gardner–Diamond syndrome, Autoerythrocyte sensitization syndrome, Psychogenic purpura

Picture 1



Intradermal test for autoerythrocyte sensitization resulted ecchymotic reaction on the autologous blood Injection site, but no reaction was observed on the normal saline injection site

PP-120

[DERMATOLOGY AND INTERNAL MEDICINE, INCLUDING SKIN MANIFESTATIONS OF SYSTEMIC DISEASES]

DISCRETE PAPULAR LICHEN MYXEDEMATOSUS ASSOCIATED WITH MONOCLONAL GAMMOPATHY: A CASE REPORT

Fatma Tunçez Akyürek¹, Gözde Ulutaş Demirbaş¹, Gülcan Saylam Kurtipek¹, Ceyhan Uğurluoğlu²

¹Department of Dermatology Selcuk University, Konya, Turkey

²Department of Pathology Selcuk University, Konya, Turkey

Lichen myxedematosus is a cronic, idiopathic cutaneous disorder and is classified into four clinical types. Discrete papular lichen myxedematosus (DPLM) is a rare subtype of localized lichen myxedematosus that presents with skin involvement only and without systemic involvement. In the literature a few cases with DPLM who associated with monoclonal gammopathy were classified as atypical. A 49-year-old man who presented with multible, discrete, flesh-colored shiny papules on his lower trunk, buttocks, upper extremities. Results of 2 punch biopsies showed splaying of the collagen with mucin present diffusely throughout the dermis. Human immunodeficiency virus (HIV), hepatitis B, and hepatitis C antibodies were negative. Laboratory tests (Complete blood count, renal, liver and thyroid function) results were all within reference range except serum protein electrophoresis. Serum protein electrophoresis showed Ig G gammopathy. DPLM is a self-limited skin disease, and prognosis is generally good however atypical clinical form may be associated with monoclonal gammopathy.

Keywords: lichen myxedematosus, monoclonal gammopathy, papular mucinosis



3rd INDERCOS

National Dermatology & Cosmetology Congress with International Participants

14-17 MARCH, 2018
HILTON ISTANBUL BOSPHORUS HOTEL
ISTANBUL, TURKEY

PP-121

[INFLAMMATORY SKIN DISEASES]

ISOLATED AND MULTIFOCAL ACTINIC LICHEN PLANUS IN LOWER LIP

Muhammet Reşat Akkuş¹, Kemal Özyurt¹, Mustafa Atasoy¹, Ragıp Ertaş¹, Yılmaz Ulaş¹, Fatma Şenel²

¹Clinic of Dermatology, Sağlık Bilimleri University Education and Research Hospital, Kayseri, Turkey

²Clinic of Patology, Sağlık Bilimleri University Education and Research Hospital, Kayseri, Turkey

Lichen planus (LP) is idiopathic disease with unknown etiology which frequently favor skin, haired skin, nails and mucosa. Oral LP is a variant of LP which may be with or without skin LP, located in oral mucosa and lips. Oral LP of lower lip is rare. Actinic LP is also a rare variant of LP. Actinic LP is frequent in children and young people with dark skin. Here in, a case of actinic LP of lower lip is presented with dermoscopic and histopathological signs.

Keywords: Lip, Actinic Lichen Planus, Oral Lichen Planus

PP-122

[CUTANEOUS ONCOLOGY]

CARCINOMA ERYSIPELOIDES ARISING FROM BREAST DUCTAL CARCINOMA ON MASTECTOMY SCAR

Ersoy Acer¹, Hilal Kaya Erdoğan¹, Zeynep Nurhan Saraçoğlu¹, Deniz Arık²

¹Department of Dermatology, Ekişehir Osmangazi University, Eskişehir, Turkey

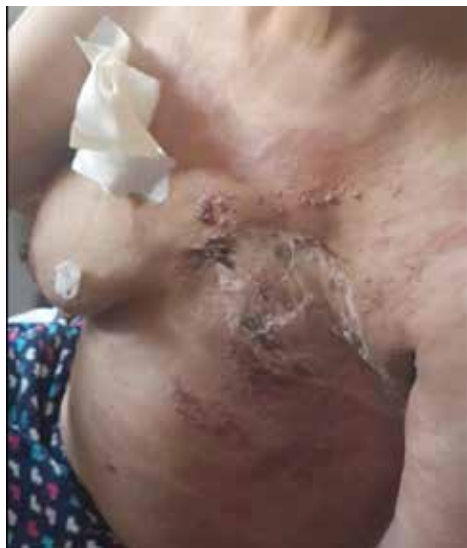²Department of Pathology, Ekişehir Osmangazi University, Eskişehir, Turkey

INTRODUCTION: Carcinoma erysipeloïdes is a rare variant of cutaneous metastasis, most frequently seen in patients with breast adenocarcinoma. It is characterized by erythematous, inflammatory patches or plaques due to tumor cells infiltration and lymphatic obstruction, frequently mimicks cellulitis or erysipelas. Metastatic tumor cells are seen obstructing dermal lymphatics on histopathological examination.

CASE: A 58-years-old woman was presented to our clinic with painful rash on her left upper arm, chest and back. The rash had started before five days. She had been treated with systemic antibiotics with the diagnosis of cellulitis without improvement. On dermatological examination, painful a sharply defined erythematous plaque on the left upper arm and the left side of the back and erythematous infiltrating papulonodular lesions and sharply defined plaque around postmastectomy scar on the left side of the chest were detected (Figure 1,2). There has been a history of breast ductal carcinoma for 1 year. A punch biopsy was performed and histopathologic examination revealed adenocarcinoma infiltration. Our case was diagnosed with carcinoma erysipeloïdes associated with breast ductal carcinoma. Herein we present a 58-years-old woman with carcinoma erysipeloïdes associated with breast ductal carcinoma and review the literature.

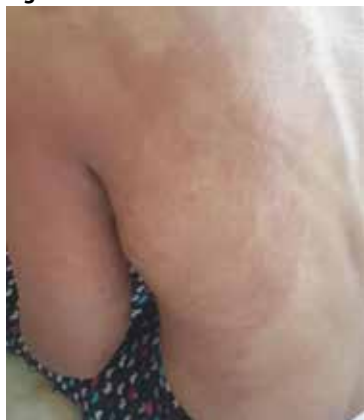Keywords: breast carcinoma, carcinoma erysipeloïdes, cellulitis, cutaneous metastasis

Figure 1



Erythematous infiltrating papulonodular lesions and sharply defined plaque around postmastectomy scar

Figure 2



A sharply defined erythematous plaque on the left side of the back

PP-123

[WOUNDS, CHRONIC WOUNDS, WOUND HEALING, ULCER]

CORTICOSTEROID PROPHYLACTIC THERAPY IN PYODERMA GANGRENOSUM

Mehmet Özeren¹

¹Department of Healthcare Management, Beykent University, İstanbul, Turkey

²Acibadem Medical center, Beylikdüzü, İstanbul, Turkey

Pyoderma gangrenosum is an uncommon, inflammatory ulcerative neutrophilic dermatosis. In over 50% of patients are associated with systemic diseases. The new ulcerations may be present after trauma, injury or surgery in 30% of these patients.

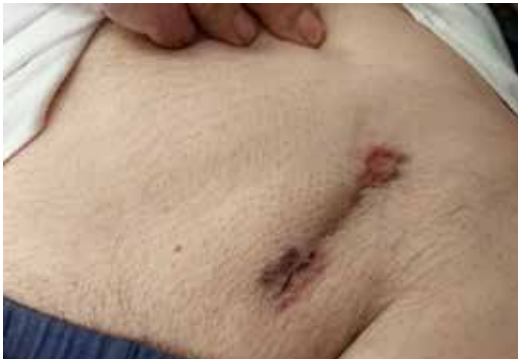A 60year-old white male patient presented to our clinic with wound started one month later after inguinal hernia operation. Physical examination revealed two ulcerations in 2x2 cm size around the linear incision scar. His medical history revealed several wounds on his body surface after shaving, enjection and minor trauma. He has diagnosed pyoderma gangrenosum six years ago. He has been hospitalized several times in recent years for treatment of ulcerations due to the pyoderma gangrenosum.

Patient's inguinal hernia operation was planned according to his medical history. And three depot-corticosteroid (betamethasone dipropionate 6,43 mg betamethasone sodium phosphate 2,63mg) injections were performed before the operation such as prophylaxis of pyoderma gangrenosum. However, this new lesion was occurred one month later after the operation.

In the review of literature, there is no consensus about the prophylactic dose of corticosteroid agent to prevent the occurrence of pyoderma gangrenosum. Most of post surgical pyoderma gangrenosum case occur before removal of suture but in our case lesion appeared 30 days after the operation.

Keywords: pyoderma gangrenosum, prophylaxis, surgery

Figure-1



ulceration on the incision scar

3rd INDERCOS

National Dermatology & Cosmetology Congress with International Participants

14-17 MARCH, 2018
HILTON ISTANBUL BOSPHORUS HOTEL
ISTANBUL, TURKEY



PP-124

[LASERS]

FRACTIONAL CO2 LASER TREATMENT FOR A PATIENT WITH LIME BURNING SCAR ON HER FACE

Tubanur Çetinarslan, Aylin Türel Ermertcan

Department of Dermatology, Manisa Celal Bayar University, Manisa, Turkey

INTRODUCTION: Burn scars leads to major functional and cosmetic problems. Although burn scars show the most disfiguring secondary effects in clinical practice, only few treatments are available to improve the appearance and texture of these scars today. Standard treatments for burn scars include scar revision, compression therapy, tissue expansion, intralesional steroid injection, interferon injection, and laser treatment. In the last decade, laser therapy has become a more and more popular treatment modality for severe burn scars, particularly the use of ablative fractional CO2 lasers.

CASE: A 34-year-old female patient came to our cosmetology clinic for the treatment of burning scar on her face. When she was 10 years old, she was bitten by a scorpion from her face. The scorpion biting area was lit with lime for treatment as non-medical. She did not respond to the previously given topical retinoids, topical steroids and other cosmetic topical procedures (etc peeling). Fractional CO2 laser treatment was started after informing about the general information about the laser therapy, possible side effects, risks and issues. After the topical anesthetic cream was removed, the fractional CO2 laser treatment was performed at 8.0-18.0 W, 74 mJ/dot, one pass once a month (surgical and traumatic scar mode with YouLaser). The end of the fourth month of laser treatment, the burning scar was reduced prominently. No complaints or symptoms related laser therapy except erythema was observed.

CONCLUSION: The exact mechanisms, by which the Fractional CO2 laser induces these beneficial scar changes remains poorly understood. Histologic analyses have been reported in previous studies, indicating that the unique pattern of fractional laser injury induces a molecular cascade including heat shock proteins and matrix metalloproteinases as well as inflammatory processes that lead to a rapid healing response and prolonged neocollagenesis with subsequent collagen remodeling.

Keywords: scar, burning, fractional CO2 laser, treatment



3rd INDERCOS

National Dermatology & Cosmetology Congress with International Participants

14-17 MARCH, 2018
HILTON ISTANBUL BOSPHORUS HOTEL
ISTANBUL, TURKEY

PP-125

[INFLAMMATORY SKIN DISEASES]

LICHEN STRIATUS AT UNUSUAL LOCATION AN ADULT

Selami Aykut Temiz¹, Arzu Ataseven¹, Recep Dursun¹, Ilkay Özer¹, Pembe Oltulu²

¹Department of Dermatology, Necmettin Erbakan University Meram Faculty of Medicine, Konya, Turkey

²Department of Pathology, Necmettin Erbakan University Meram Faculty of Medicine, Konya, Turkey

Lichen striatus (LS) is a rare inflammatory dermatosis that influences mostly children, being rare reports in adults. The pathogenesis is unknown. In addition, lichen striatus is demonstrated as T-cell mediated inflammatory cutaneous disease. It is characterized by linear tendency, usually on the extremities. Its most typical property is the linear arrangement of slightly raised, lichenoid papules.

A 28-year-old woman presented with a 3-month history of an asymptomatic linear erythematous violaceous papular lesions on her left abdominal area. Skin biopsy was performed in terms of differential diagnosis from other linear distributions of inflammatory dermatoses. Histopathological examination revealed hyperkeratosis, acanthosis, focal parakeratosis, exocytosis, subbasal dissociation of an area, vacuolar degeneration of the basal membrane, perivascular and lichenoid lymphocytic infiltration. As a result, our case was diagnosed as lichen striatus, clinically and histologically. Topical pimecrolimus ointment twice a day therapy was preferred in the patient. Lichen striatus is a self-limiting acquired dermatosis usually located along the Blaschko lines on the extremities. In the pathogenesis, T-cell mediated autoimmune reaction against Malpighi cells showing genetic mosaicism and distributed throughout the Blaschko lines is accused. Topical calcineurin inhibitors block interleukin-2 transcription and thus prevent local T lymphocyte activation. Thus, we used topical pimecrolimus in our case.

We think that our case of lichen striatus, which we treated with topical pimecrolimus treatment, was suitable for presentation because of its rare occurrence in adult patients and the rare occurrence of abdominal involvement.

Keywords: Lichen striatus, unusual location, pimecrolimus

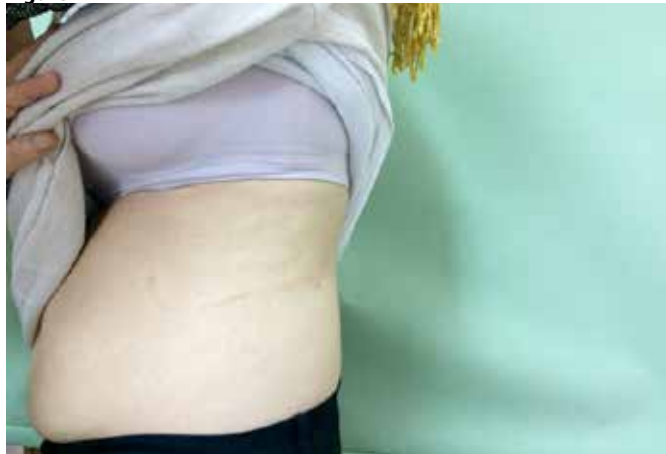3rd INDERCOS

National Dermatology & Cosmetology Congress with International Participants

14-17 MARCH, 2018
HILTON ISTANBUL BOSPHORUS HOTEL
ISTANBUL, TURKEY

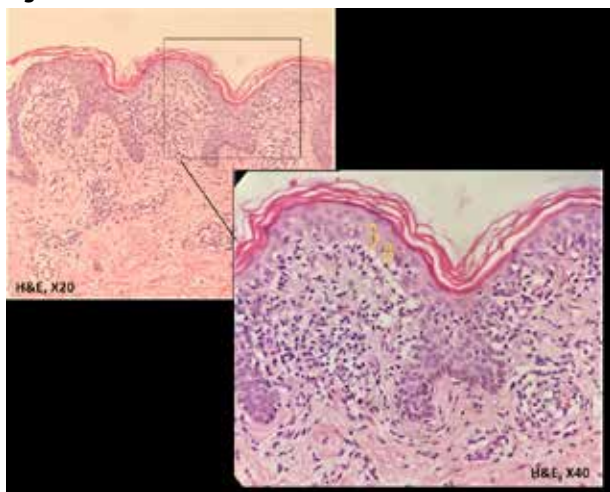


Figure 1



Linear erythematous violaceous papular lesions on her left abdominal area

Figure 2



Lichen striatus; band-like lymphocyte infiltration in the papillary dermis, vacuolization in the basal layer (arrow), lymphocyte exocytosis into the epithelium (yellow arrow)



3rd INDERCOS

National Dermatology & Cosmetology Congress with International Participants

14-17 MARCH, 2018
HILTON ISTANBUL BOSPHORUS HOTEL
ISTANBUL, TURKEY

PP-126

[DERMATOPATHOLOGY]

CUTANEOUS LIPOMATOUS NEUROFIBROMA; A PRESENTATION OF RARE CASE

Ebru Zemheri¹, Ilkin Zindanci², Melike Kibar Ozturk²

¹Department of Pathology, Sağlık Bilimleri University, Umraniye SUAM Training and Research Hospital, Istanbul, Turkey

²Department of Dermatology, Sağlık Bilimleri University, Umraniye SUAM Training and Research Hospital, Istanbul, Turkey

A 41-year-old female patient was admitted to our hospital due to a yellowish, 0.8 cm in diameter sized papulonodular lesion beneath the right ear. There were no subjective complaints. A microscopic examination revealed classical neurofibroma areas mixed with muddy fat tissue. Cutaneous lipomatous neurofibroma (CLN) was diagnosed. CLN is a very rare variant of neurofibromas. In the pathogenesis, aberrant development of the lipomatous tissue is mentioned. Differential diagnosis should be made with neurocristic cutaneous hamartoma, lipomas, cutaneous meningiomas, and nevi with lipocyte differentiation. We want to present our case in the context of the literature because of its rare occurrence.

Keywords: neurofibroma, cutaneous lipomatous neurofibroma, histopathology

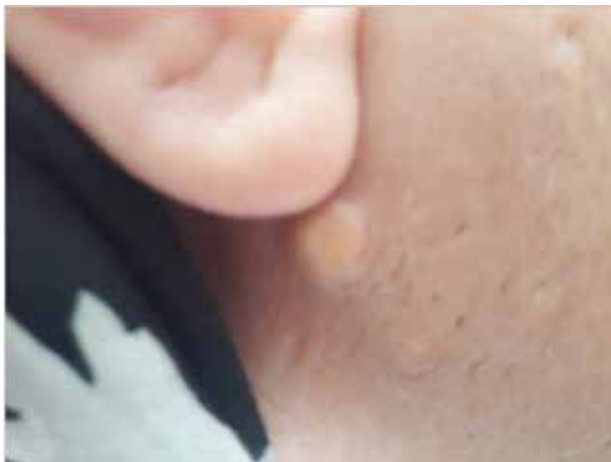3rd INDERCOS

National Dermatology & Cosmetology Congress with International Participants

14-17 MARCH, 2018
HILTON ISTANBUL BOSPHORUS HOTEL
ISTANBUL, TURKEY



Figure 1



Clinical appearance of the lesion

Figure 2



Neural cells and mature lipocytes



3rd INDERCOS

National Dermatology & Cosmetology Congress with International Participants

14-17 MARCH, 2018
HILTON ISTANBUL BOSPHORUS HOTEL
ISTANBUL, TURKEY

PP-127

[MISCELLANEOUS]

ERUPTIVE SYRINGOMAS: UNRESPONSIVENESS TO ORAL ISOTRETINOIN

Kiyimet Handan Keleşçi¹, Ali Karakuzu¹, İlgin Aydın², Erkan Davarçı¹

¹Department of Dermatology, İzmir Katip Çelebi University Atatürk Training and Research Hospital, İzmir, Turkey

²Department of Pathology, İzmir Katip Çelebi University Atatürk Training and Research Hospital, İzmir, Turkey

INTRODUCTION: Syringoma is a benign tumour arising from the intraepidermal portion of sweat ducts, of which the generalized eruptive form is a rare clinical variant. They usually appear as several small, round, smooth-surfaced, yellowish, papules. They are often located on the face and around the eyelids. Eruptive syringoma (ES), occurring more often in puberty and adolescence, presents as multiple papules, often located on the trunk.

CASE: A 24-year-old female presented with multiple asymptomatic, skin-colored lesions of 10 years duration which were progressive in nature. Lesions started from the neck and spread to the forearm and the legs. Patient was not on any medication. Family history was unremarkable. Cutaneous examination revealed multiple skin-colored papules over the neck, forearm and the legs (Figure 1,2,3), average 3 to 4 mm in size. No mucus membrane, nails, scalp, or palmoplantar involvement was seen. Systemic examination was unremarkable. Biopsy was taken from one of the forearm. The histology showed proliferation of eccrine ductal structures in the dermis with surrounding fibrotic stroma and the wall of the ducts is lined by 2 rows of cuboidal cells with comma-like tails and giving them the appearance of tadpole were seen (Figure 4,5) (H and E, ×40). This histopathologic findings were consistent with the clinical diagnosis of syringoma. The patient was advised for oral isotretinoin treatment for 8 months. After oral isotretinoin treatments, no improvement was seen. Patient is still under follow up.

CONCLUSION: Therapy for syringomas is usually unsatisfactory and recurrences are common. Oral isotretinoin have also been used. We report a rare clinical variant eruptive syringoma with unresponded oral isotretinoin over a 8-month period.

Keywords: eruptive, syringoma, isotretinoin

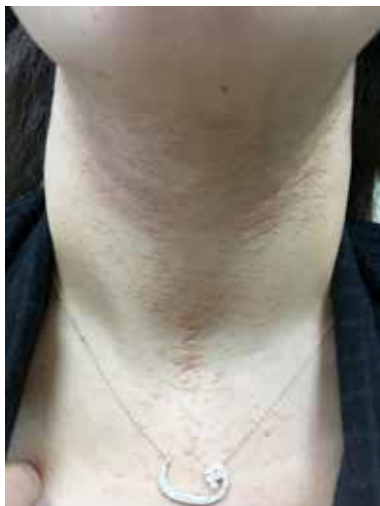3rd INDERCOS

National Dermatology & Cosmetology Congress with International Participants

14-17 MARCH, 2018
HILTON ISTANBUL BOSPHORUS HOTEL
ISTANBUL, TURKEY

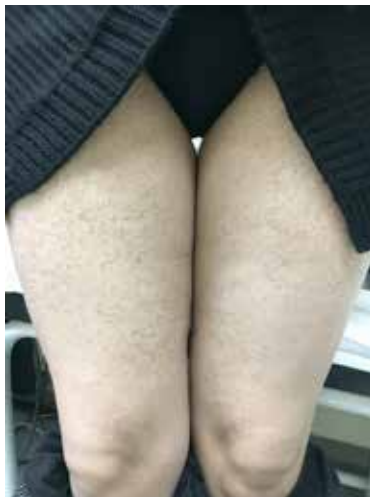

Figure 1



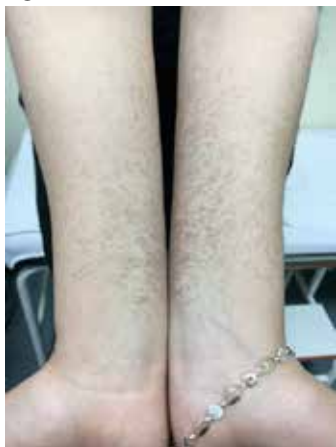Multiple skin-colored papules over the neck

Figure 2



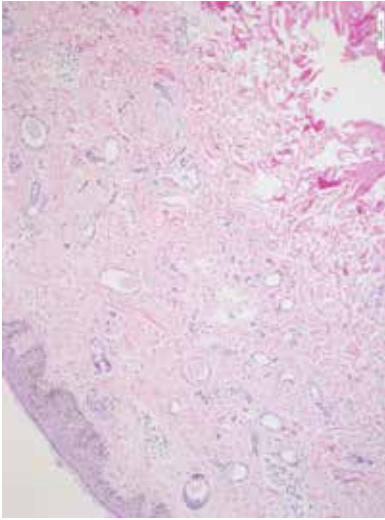
Multiple skin-colored papules over arm

Figure 3



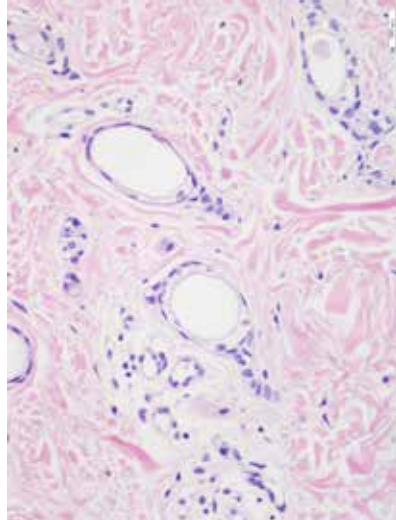
Multiple skin-colored papules over the legs

Figure 4



*Proliferation of eccrine ductal structures in the dermis with surrounding fibrotic stroma
Hematoxylin and eosin, $\times 10$.*

Figure 5



*The wall of the ducts is lined by 2 rows of cuboidal cells with comma-like tails. Hematoxylin and eosin,
 $\times 40$*



PP-128

[ADVERSE DRUG REACTIONS, TEN]

A RARE CASE OF DEXKETOPROFEN - INDUCED LINEAR IMMUNOGLOBULIN A BULLOUS DERMATOSIS

Mustafa Turhan Şahin¹, Peyker Temiz²

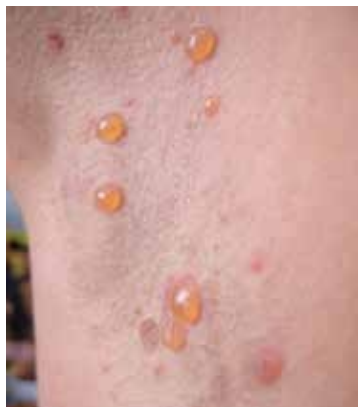¹Department of Dermatology, Celal Bayar University, Manisa, Turkey

²Department of Pathology, Celal Bayar University, Manisa, Turkey

Linear IgA bullous dermatosis (LAD) is a rare autoimmune blistering disorder characterized by subepidermal blisters with linear IgA deposition along the dermal-epidermal junction(1). Even though the majority of cases are idiopathic, some of them are drug-induced. Vancomycin is the medication most commonly reported in drug induced LAD. However, other medications, such as gemcitabine, interferon- α 2a, piroxicam and ketoprofen have also been reported. (2-3) Here we report a 55-year-old woman without any medical history who take sometimes a pill for her headache. 3 days after taking dexketoprofen, a skin eruption developed from the bilateral axilla and legs shaped like erythematous, intact blistering. Accompanying the exanthema, erosions in the oral and genital mucosa were not noted. The patient was negative for Nikolsky's sign. Histopathological examination of a skin direct immunofluorescence biopsy specimen showed linear deposition of IgA along the basement membrane zone. We present this rare case LAD, in order to draw attention to dexketoprofen which is a nonsteroidal anti-inflammatory drug, that has not been reported to induce LAD till now.

Keywords: dexketoprofen, Linear IgA bullous dermatosis, drug-induced

right axilla





3rd INDERCOS

National Dermatology & Cosmetology Congress with International Participants

14-17 MARCH, 2018
HILTON ISTANBUL BOSPHORUS HOTEL
ISTANBUL, TURKEY

PP-129

[ADVERSE DRUG REACTIONS, TEN]

ACNEIFORM ERUPTION INDUCED BY AN EGFR INHIBITOR-PANITUMUMAB: A CASE REPORT

*Ersoy Acer, Nihan Yüksel Çanakçı, Hilal Kaya Erdoğan, Zeynep Nurhan Saraçoğlu
Department of Dermatology, Ekişehir Osmangazi University, Eskişehir, Turkey*

INTRODUCTION: For the last few decades, drugs that target the epidermal growth factor receptor (EGFR) are used in the treatment of many types of cancer. Although their side effects are generally acceptable compared with the cytotoxic drugs; but they have various cutaneous side effects such as xerosis, eczema, telangiectasia, fissures, hyperpigmentation, hair changes, paronychia with pyogenic granuloma and acneiform eruption. Drug induced acne is a common skin reaction that shows sudden onset with a monomorphous eruption of inflammatory papules or pustules.

CASE: A sixty-eight years old male patient was referred to our clinic with a sudden onset itchy, erythematous rash on his trunk. He was treated with -an EGFR inhibitor -Panitumumab - for his metastatic colorectal carcinoma and his skin eruption started a few days after the first dose. On dermatological examination, monomorphic papulopustular lesions on his back, chest and shoulders were detected. Our case was diagnosed with Panitumumab induced acneiform eruption. Complete improvement of the lesions was observed with topical 5% benzoyl peroxide and 3% erythromycin and topical sodium sulfacetamide treatments without interruption of panitumumab treatment. Herein we present a patient with Panitumumab induced acneiform eruption.

Keywords: acneiform eruption, EGFR inhibitors, panitumumab

3rd INDERCOS

National Dermatology & Cosmetology Congress with International Participants

14-17 MARCH, 2018
HILTON ISTANBUL BOSPHORUS HOTEL
ISTANBUL, TURKEY



PP-130

[INFLAMMATORY SKIN DISEASES]

GROVER'S DISEASE IN A YOUNG WOMAN

Büşra Aydın¹, Berna Solak¹, Mustafa Kösem²

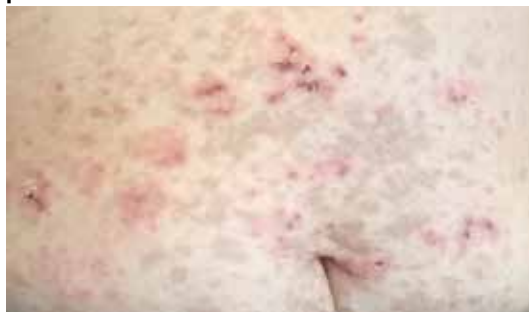¹Department of Dermatology, Sakarya University Training and Research Hospital, Sakarya, Turkey

²Department of Pathology, Sakarya University Training and Research Hospital, Sakarya, Turkey

A 32-year-old female patient was admitted because of pruritic skin lesions on the abdominal area and extremities for 3 months. On physical examination, there were numerous red-brown papules and post-inflammatory hyperpigmentation primarily on the abdomen as well as on proximal part of the extremities. (Picture 1) The oral and genital mucosa were not affected. She denied any infection, systemic disease, or drug use. She had given birth 8 months ago, now she has been nursing. Her laboratory findings were within normal limits. Punch biopsies from one of the skin lesions were performed. Histological examination revealed that acantholytic dermatosis, hypergranulosis, intraepidermal dissociation and bullae formation, acantholytic and dyskeratotic keratinocytes in the epidermis, and few eosinophils and neutrophils in the superficial dermis. Direct immunofluorescence examination was found as negative. Grover's disease (Transient acantholytic dermatosis) is an acantholytic dermatosis of unknown origin, which is characterized by erythematous, pruritic maculopapular eruption, mostly seen in the elderly. It has been reported that a number of disorders such as various malignancies, immunodeficiency states including HIV infection and bone marrow transplantation might be associated with Grover disease. As with our case, some reports in the literature were not associated any of the aforementioned conditions. Here we report this case to remind this disease when encounter pruritic lesions even in a young patient without any associated states.

Keywords: grover's disease, transient acantholytic dermatosis, red-brown papules, post inflammatory hiperpigmentation

picture 1



red-brown papules and post-inflammatory hyperpigmentation on the abdomen



3rd Indercos

National Dermatology & Cosmetology Congress with International Participants

14-17 MARCH, 2018
HILTON ISTANBUL BOSPHORUS HOTEL
ISTANBUL, TURKEY

PP-131

[DERMOSCOPY]

DERMOSCOPY OF NEVUS COMEDONICUS

Melek Aslan Kayıran¹, Filiz Cebeci¹, İlkin Zindancı², Mehmet Salih Gürel¹

¹Istanbul Medeniyet University Göztepe Education and Research Hospital, Department of Dermatology, Istanbul, Turkey

²Saglik bilimleri University Umraniye Education and Research Hospital, Department of dermatology, Istanbul, Turkey

INTRODUCTION: Nevus comedonicus is a rare type of nevus originating from the epithelial part of the center of the pilosebaceous unit. It is characterized by the combination of the dilated follicular openings resembling comedones. It may be seen in any part of the body but especially face and neck. It is usually solitary but sometimes it may be associated with central nervous system, skeletal system and eye anomalies and in that case, it is called nevus comedonicus syndrome. Accompanying skin diseases are ichthyosis, trichilemmal cysts, sebaceous nevi, Becker nevus, leukoderma, white hair, Sturge Weber Syndrome and hemangiomas. The treatment options if needed, are topical retinoid applications, and in resistant forms laser therapy or surgical excision.

CASE: A 38-year-old male patient admitted to our clinic due to a lesion on the left side of his body. The asymptomatic lesion had been present since childhood. The dilated follicular openings were spreading linearly from the left areola to his back and some of them had black keratotic plugs reminiscent of open comedones. (Figure1A-B) No evidence of any additional skin disease was observed. Multiple, circular and oval-shaped, white-light brown colored homogenous areas along with some dark grey-blackish keratin plugs were seen on its dermoscopic examination. (Figure2A-B) There were no systematic findings. The patient didn't want to have any treatment because it was only a cosmetic situation. However, the patient was followed up because it could be accompanied by some systemic anomalies. History and clinical examination leads to the diagnosis and there is no need to perform a histopathological examination in most cases. The diagnosis can be supported by dermoscopic findings. We found many circular and oval-shaped, white and light brown colored homogenous areas along with some dark gray-blackish keratin plugs on the dermoscopic examination. The dermoscopy of our case was similar to the findings of the present reports. The dermoscopic findings of the previous cases are multiple, well-defined, structureless brown homogenous areas surrounding the keratin plugs and many circular homogenous areas in light and dark-brown shades with remarkable keratin plugs.

CONCLUSION: This case is presented for emphasizing the point that dermoscopy can be supportive for the diagnosis of nevus comedonicus.

Keywords: dermoscopy, keratin plug, nevus comedonicus,

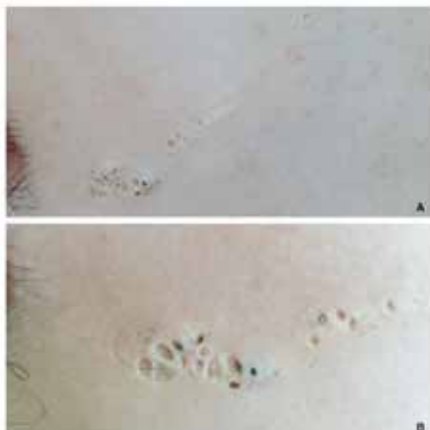
3rd INDERCOS

National Dermatology & Cosmetology Congress with International Participants

14-17 MARCH, 2018
HILTON ISTANBUL BOSPHORUS HOTEL
ISTANBUL, TURKEY

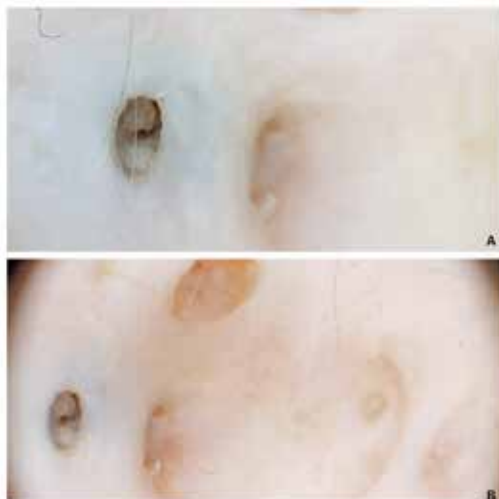


Figure 1 A-B



The dilated follicular openings are seen and some of them had black keratotic plugs reminiscent of open comedones.

Figure 2 A-B



Multiple, circular and oval-shaped, white-light brown colored homogenous areas along with some dark gray-blackish keratin plugs were seen on its dermoscopic examination.



3rd INDERCOS

National Dermatology & Cosmetology Congress with International Participants

14-17 MARCH, 2018
HILTON ISTANBUL BOSPHORUS HOTEL
ISTANBUL, TURKEY

PP-132

[AUTOIMMUNE BULLOUS DISEASES]

A CASE OF LINEAR IGA DERMATOSIS MIMICKING VARICELLA INFECTION

Ceren Buğlem Elgörmüş¹, Rafet Koca¹, Nilgün Tekin¹, Figen Barut²

¹Department of Dermatology, Bulent Ecevit University, Zonguldak, Turkey

²Department of Pathology, Bulent Ecevit University, Zonguldak, Turkey

Lineer IgA dermatosis is an autoimmune vesiculobullous disease that can affect children and adults. Antibody deposition on the basement membrane zone leads to complement activation and neutrophil chemotaxis, which eventuates with blister formation on skin and mucous membranes. This disease has been reported to have been caused by drugs too. A forty-six year old woman presented to our clinic with itching and watery bubbles for two months. On examination, there were vesicles, widespread on her back, neck and chest. Tzanck smear tests made from the base of intact vesicles did not show multinucleated giant cells. Histologic examination (both a hematoxylin eosin stain and a immunofluorescence stain) of a biopsy specimen was compatible with lineer IgA dermatosis. We started 100 mg/day dapson for the treatment. The patient had apparent clinical relief at the end of 15 days of the treatment. After a month starting the treatment, only postinflammatory hyperpigmentations remained. Dapson treatment was continued with 100 mg / day for 3 months and 50 mg / day for 1 month. The treatment was stopped after healing completely. The primary treatment of the disease is dapson. On the other hand, many treatments are being used such as corticosteroids, tetracycline, erythromycin, sulfapyridine, colchicine, mycophenolate mofetil and intravenous immunoglobulins. But our patient was fully recovered when using dapson. One point that we want to draw attention to is that, with a basic perspective, a patient who looks like varicella infection also needs more investigation.

Keywords: Lineer IgA dermatosis, diagnosis, treatment, dapson

3rd INDERCOS

National Dermatology & Cosmetology Congress with International Participants

14-17 MARCH, 2018
HILTON ISTANBUL BOSPHORUS HOTEL
ISTANBUL, TURKEY



PP-133

[DERMATOLOGICAL SURGERY]

USE OF FINGER PARTS OF SURGICAL GLOVES AS DIGITAL TOURNIQUETS ON THE GREAT TOE

Hasan Mete Aksoy¹, Berna Aksoy²

¹Bahcesehir University, Faculty of Medicine, Department of Plastic and Reconstructive Surgery, Istanbul; VM Medicalpark Hospital, Plastic and Reconstructive Surgery Clinic, Kocaeli, Turkey

²Bahcesehir University, Faculty of Medicine, Department of Dermatology, Istanbul; VM Medicalpark Hospital, Dermatology Clinic, Kocaeli, Turkey

A clean and bloodless surgical field is necessary for nail surgery and to achieve this a digital tourniquet is used. Even a minor surgical intervention performed on the nail complex obscures surgical field by causing excessive bleeding. Nail bed is a very vascular structure and blood must be emptied from this region and a digital tourniquet must be applied around the base of digit. The great toe is an anatomic region which is commonly affected by nail disorders. Various practical methods have been developed for tourniquet application to great toe. Use of finger parts of surgical gloves as digital tourniquets is a simple digital tourniquet method which is practical, effective, and safe.

Keywords: tourniquet, nail, surgery

PP-134

[INFECTIOUS DISEASES, PARASITIC DISEASES, INFESTATIONS]

ATYPICAL PRESENTATION OF PITYRIASIS VERSICOLOR: A CASE REPORT

Begüm Ünlü, Ümit Türsen

Department of Dermatology, Mersin University medical school, Mersin, Turkey

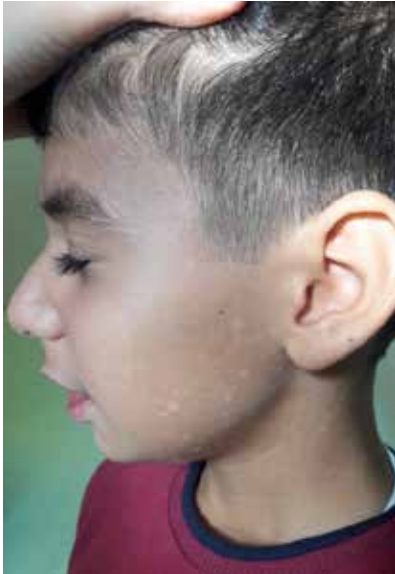Pityriasis versicolor is a superficial fungal infection that caused by *Malassezia* spp. It usually presents on chest, shoulders, upper back as asymptomatic, round to oval macules of varying sizes. It is characterized by superficial scaling and a mild disturbance of skin pigmentation. Face involvement is commonly seen in pediatric age group.

A 8 years old, male patient was referred to our dermatology department with a 1 month history of hypopigmented macules on his cheeks and neck. In potassium hydroxide examination, typical spaghetti and meatballs appearances of hyphae was observed.

In this case report, we aimed to emphasize the importance of potassium hydroxide examination on hypopigmented face lesions especially in children.

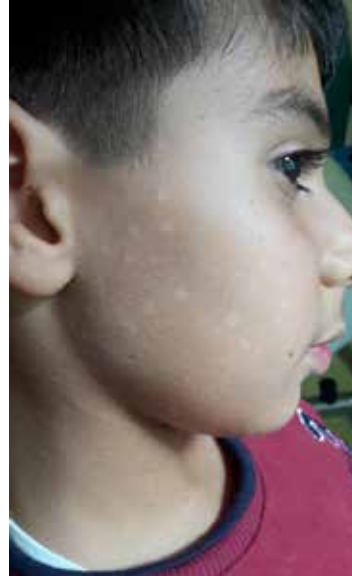Keywords: Pityriasis versicolor, hypopigmented, pediatric

Figure 1



Hypopigmented macules on face

Figure 1



Hypopigmented macules on face

3rd INDERCOS

National Dermatology & Cosmetology Congress with International Participants

14-17 MARCH, 2018
HILTON ISTANBUL BOSPHORUS HOTEL
ISTANBUL, TURKEY



PP-135

[DERMATOLOGY AND INTERNAL MEDICINE, INCLUDING SKIN MANIFESTATIONS OF SYSTEMIC DISEASES]

IDIOPATHIC UNILATERAL FACIAL HYPERHIDROSIS: A CASE REPORT

Mustafa Aksoy¹, Yavuz Yeşilova², Ulaş Güvenç³, Mehtap Kocatürk⁴, Özcan Kocatürk⁴

¹Department of Dermatology and Venereology, Harran University, Sanliurfa, Turkey

²Department of Dermatology, Special Lokman Physician Clinic, Van, Turkey

³Department of Dermatology, Special Güvenç Beauty and Wellness Center, Mersin, Turkey

⁴Department of Neurology, Harran University, Sanliurfa, Turkey

Localised unilateral hyperhidrosis (LUH) is a skin disease seen as a result of overactive sweat glands on one side of the body. This extremely rarely seen disease has primary (idiopathic) or secondary (malignancy, trauma etc) causes. The case is here presented of a male patient with excessive sweating on the right side of the face, who was diagnosed with idiopathic LUH disease.

Keywords: Localised, unilateral, hyperhidrosis.



3rd Indercos

National Dermatology & Cosmetology Congress with International Participants

14-17 MARCH, 2018
HILTON ISTANBUL BOSPHORUS HOTEL
ISTANBUL, TURKEY

PP-136

[MISCELLANEOUS]

VERRUCOUS HYPERPLASIA OF AMPUTATION STUMP: A CASE REPORT

Burçin Cansu Bozca¹, Cumhuri İbrahim Başsorgun², Erkan Alpsoy¹

¹Department of Dermatology and Venerology, Akdeniz University, Antalya, Turkey

²Department of Pathology, Akdeniz University, Antalya, Turkey

INTRODUCTION: Verrucous hyperplasia also known as papillomatosis cutis lymphostatica, lymphostatic congestion papillomatose or papillomatosis cutis verrucosa refers to a reactive hyperplastic condition. It presents as numerous, coalescent warty papules over amputation stump usually affecting lower limb. There have been various factors implicated in the pathogenesis of verrucous hyperplasia including poor fitting prosthesis, suction socket prosthesis, venous stasis and friction and superimposed bacterial infections. Here, we report a new case of verrucous hyperplasia of amputation stump in a patient with right heel amputation due to acral lentiginous malignant melanoma.

MATERIAL-METHODS: A 51-year-old female patient referred to our dermatology outpatient clinic with complaints of verrucous skin lesions developing over her amputation stump for 8 month. The patient had to undergo right heel amputation due to acral lentiginous melanoma 4 years ago. Dermatologic examination revealed vegetative and mamillated plaque with erythematous and edematous border over the amputation stump.

RESULTS: Cutaneous biopsies were found to be compatible with verrucous hyperplasia of amputation stump. In histopathologic examination, pseudoepitheliomatous hyperplasia along with dilated lymphatics and capillaries with variable inflammatory infiltrate was observed. Secondary bacterial infection was treated with amoxicillin clavulanic acid and the patient was advised to use appropriate shoes.

DISCUSSION: Skin problems commonly occur after lower limb amputation. One such skin anomaly that develops on the residual limb is wartlike lesions of verrucous hyperplasia. It occurs when the chronic pressure effects of a poor prosthetic fit disrupt vascular and lymphatic channels, resulting in chronic tissue edema. Bacterial infection may play a role in the development of pseudo verrucous hyperplasia, as secondary mixed flora infections are common because of the poor superficial blood flow and the convoluted surface. Clinically verrucous hyperplasia can be mistaken for tuberculosis verrucosa cutis, verruca vulgaris or verrucous carcinoma. The treatment is directed towards the possible underlying etiological factors. It includes external compression bandaging, shrinker socks, pads and partial end bearings. A short course of oral diuretics has also been used. It should be ensured that the prosthesis should be well fitting and a regular follow-up with prosthesis is essential for long term prevention of this condition. Here in, we present an extremely rare case of verrucous hyperplasia of amputation stump following right heel amputation because of acral lentiginous melanoma. Since these patients have an increased tendency to malignant skin tumor development, early diagnosis and close follow-up is important.

Keywords: Verrucous hyperplasia, amputation, stump, acral lentiginous malignant melanoma

3rd INDERCOS

National Dermatology & Cosmetology Congress with International Participants

14-17 MARCH, 2018
HILTON ISTANBUL BOSPHORUS HOTEL
ISTANBUL, TURKEY



PP-137

[INFECTIOUS DISEASES, PARASITIC DISEASES, INFESTATIONS]

UNILATERAL AND BILATERAL INVOLVEMENT: TWO CASES OF LOCALIZED PITYRIASIS ROSEA

Mualla Polat, Tekden Karapınar

Department of Dermatology, Faculty of Medicine, Abant İzzet Baysal University, Bolu, Turkey

Pityriasis rosea is a common papulosquamous disorder with occasional variations in lesion morphology, size, number, and course of disease. Unilateral pityriasis rosea is also one of the rare atypical pityriasis rosea variants and lesions are localized in one side of the body. In pityriasis rosea inversus, axillae, inguinal areas and face are predominantly affected. We present an extremely cases of unilateral pityriasis rosea in a 52 years old female patient and bilateral pityriasis rosea in a 30-year-old male patient. Diagnosis of unilateral and bilateral pityriasis rosea should be considered for patient who applies with localized erythematous papulosquamous lesions.

Keywords: Localized Pityriasis Rosea, papulosquamous disease, axillae

PP-138

[CUTANEOUS ONCOLOGY]

MAMMARY PAGET'S DISEASE: A CASE

Ayşe Akbaş¹, Fadime Kılınç¹, Tuçe Özkara¹, Sertaç Şener¹, Sibel Orhun Yavuz², Mehmet Özer³, Akın Aktaş⁴

¹Ataturk Training and Research Hospital, Dermatology Clinic, Ankara, Turkey

²Yıldırım Beyazıt University, Medical Faculty, Department of Pathology, Ankara, Turkey

³Ataturk Training and Research Hospital, General Surgery, Ankara, Turkey

⁴Yıldırım Beyazıt University, Medical Faculty, Department of Dermatology, Ankara, Turkey

Mammary Paget's disease is a rare disease that causes 1-4.3% of all breast cancer patients with characteristic eczematous changes in the nipple. Our case is a sixty two-old female lady who admitted to dermatology clinic of hospital with itchy lesions on her nipple-areolar complex of her right breast. She had these symptoms and signs for nearly two years and these lesions did not respond to topical treatment. A sharply demarcated erythematous lesion with yellowish crusts were found at the nipple-areolar complex of right breast. No lumps were palpated in both of the breast and axillary examination was normal bilaterally. Punch biopsy of the lesion revealed Paget's disease of the breast. No metastasis was detected Simple mastectomy was done. This case is presented to emphasize that Paget's disease should also be considered in the differential diagnosis of eczema-like lesions that do not respond to treatment on the mammary.

Keywords: breast, Paget's disease, surgery

PP-139

[INFLAMMATORY SKIN DISEASES]

A CASE OF PITYRIASIS LICHENOIDES: RAPID RESOLUTION WITH AZITHROMYCIN MONOTHERAPY IN THREE WEEKS

Atiye Ogrum¹, Zennure Takı¹, Havva Yıldız Seckin¹, Elif Cetin²

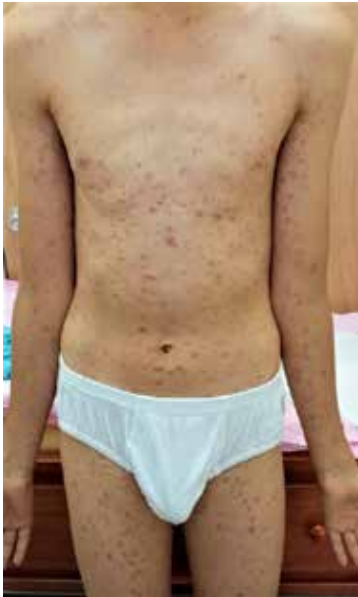¹Department of Dermatology and Venereology, Gaziosmanpaşa University, Tokat, Turkey

²Department of Pathology, Gaziosmanpaşa University, Tokat, Turkey

Pityriasis lichenoides (PL) is a spectrum of inflammatory skin diseases which include PL et varioliformis acuta (PLEVA), febrile ulceronecrotic Mucha-Habermann disease, and PL chronica (PLC). It occurs in all ages but affects mainly children and young adults. PLEVA and PLC lesions are rarely seen together on the same patient. Treatment options are based on case series-reports, and anecdotes, and include topical corticosteroids, topical immunomodulators, systemic antibiotics (tetracycline, erythromycin), phototherapy. We report a 13 year-old boy whose lesions of both PLEVA and PLC, with rapid and dramatic response to azythromycin monotherapy.

Keywords: Pityriasis lichenoides, treatment, azythromycin

Figure



3rd INDERCOS

National Dermatology & Cosmetology Congress with International Participants

14-17 MARCH, 2018
HILTON ISTANBUL BOSPHORUS HOTEL
ISTANBUL, TURKEY



PP-140

[SEXUALLY TRANSMITTED INFECTIONS, HIV/AIDS]

A CASE OF ZONA ZOSTER WITH SECONDARY STAGE SYPHILIS AND AIDS

Mualla Polat¹, Tekden Karapınar¹, Hesna Müzeyyen Astarci², Aslıhan Geyik¹

¹Department of Dermatology, Faculty of Medicine, Abant İzzet Baysal University, Bolu, Turkey

²Department of Pathology, Faculty of Medicine, Abant İzzet Baysal University, Bolu, Turkey

INTRODUCTION: Syphilis is a chronic, systemic, sexually transmitted, and treatable infection caused by a spirochete, *Treponema pallidum*. The second stage of early syphilis, the secondary stage syphilis, is very difficult to diagnose because of the large number and variety of elementary lesions. The diversity of elementary lesions has led to the need to classify these period lesions of syphilis. In addition, the intervening immunosuppression causes the lesions of this period to be further diversified and makes diagnosis of the disease difficult.

CASE: A 42-year-old male patient was admitted to our clinic with the complaints of widespread rash that were present on 4 days. In addition, the patient had pain in the zona zoster site 1 month ago. On the dermatological examination of the patient, subcutaneous nodules were observed on the trunk, which were erythematous, enduring, about 1 cm in diameter. Histopathological examination revealed flattened rete ridges and basket network hyperkeratosis in the epidermis, vacuolar degeneration and prominent lymphocyte exocytosis in the dermoepidermal compartment were observed. After the detection of perineural lymphoplasmic cell infiltration in some areas; we investigated VRDL, TPHA and possible sexually transmitted diseases. Consequently, VDRL, TPHA and Anti-HIV antibody were detected as positive. On account of these findings patients were diagnosed with postherpetic neuralgia, syphilis and AIDS.

DISCUSSION: We aimed to emphasize that the patient should be reminded that syphilis lesions may occur atypical due to developing immunosuppression and that sexually transmitted diseases may accompany each other.

Keywords: Zona Zoster, Syphilis, AIDS



3rd INDERCOS

National Dermatology & Cosmetology Congress with International Participants

14-17 MARCH, 2018
HILTON ISTANBUL BOSPHORUS HOTEL
ISTANBUL, TURKEY

PP-141

[CUTANEOUS ONCOLOGY]

MERKEL CELL CARCINOMA IN LOWER EXTREMITY: CASE REPORT

Muhammet Reşat Akkuş¹, Kemal Özyurt¹, Mustafa Atasoy¹, Yılmaz Ulaş¹, Ragıp Ertas¹, Yücel Tekin²

¹Clinic of Dermatology, Sağlık Bilimleri University. Education and Research Hospital, Kayseri, Turkey

²Clinic of Pathology, Sağlık Bilimleri University. Education and Research Hospital, Kayseri, Turkey

The origin of Merkel cell carcinoma (MCC) is exactly unknown which thought to derived from merkel cells. Some etiological factors are accused such as advanced age, merkel cell polyomavirus, UV damage and immunosuppression. Decreasing the time for establishing the diagnosis and beginning the therapy of MCC is very important for it is aggressive and fatal tumor. MCC have some features like high recurrence rate and metastasis to regional lymph nodes and far organs. Here is presented a 79 years old lady with MCC in her lower extremity which is verified with histopathological investigation.

Keywords: Merkel Cell Carcinoma, lower extremity, merkel cell polyomavirus



PP-142

[DERMATOLOGY AND INTERNAL MEDICINE, INCLUDING SKIN MANIFESTATIONS OF SYSTEMIC DISEASES]

A CASE OF ISOLATED MACRODACTYLY

Mustafa Aksoy¹, Ibrahim Sağlam², Mahmut Demir³, Ahmet Güzelçiçek³, Abdurrahim usak⁴, Özcan Kocatürk⁵, Mehtap Kocatürk⁵, Mehmet Akif Altay⁶, Yavuz Yeşilova⁷

¹Harran University, Faculty of Medicine, Dermatology and Venereology Department, ŞANLIURFA

²Harran University, Faculty of Medicine, Plastic and Reconstructive Surgery Department, ŞANLIURFA

³Harran University, Faculty of Medicine, Pediatrics Department, ŞANLIURFA

⁴Harran University, Faculty of Medicine, Radiology Department, ŞANLIURFA

⁵Harran University, Faculty of Medicine, Neurology Department, ŞANLIURFA

⁶Harran University, Faculty of Medicine, Orthopedics and Traumatology Department, ŞANLIURFA

⁷Special Lokman Physician Hospital, Dermatology Department, VAN

Macroductyly is characterized with the abnormal enlargement of one or more fingers or toes. It constitutes 1% of all congenital anomalies. It is more common in males. There is excessive growth in bone and soft tissue and the treatment is surgery. Here, a 23-month-old male with congenital left-hand 1st and 2nd digits macroductyly was presented due to its very rare occurrence.

Keywords: Macroductyly, hand, rare disease

Figures

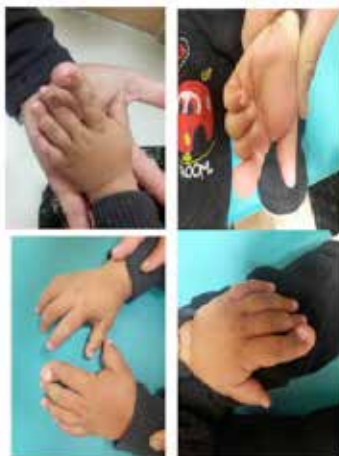

Figure-1: Clinic photos

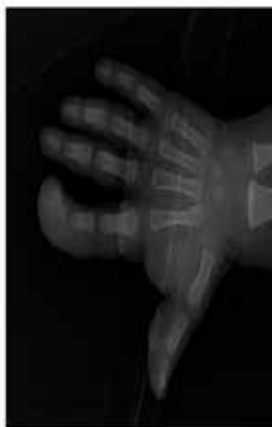

Figure-2: Radiological photo

Figure 1, 2



3rd Indercos

National Dermatology & Cosmetology Congress with International Participants

14-17 MARCH, 2018
HILTON ISTANBUL BOSPHORUS HOTEL
ISTANBUL, TURKEY

PP-143

[PRURITUS]

UNILATERAL PITYRIASIS ROSEA WITH DERMATOMAL SPREAD: A RARE CASE REPORT

Hatice Kaya Özden¹, Mualla Polat², Ahmet Tuğrul Eruyar³

¹Department of Dermatology, Kocaeli Derince Training and Research Hospital, Kocaeli, Turkey

²Department of Dermatology, Abant İzzet Baysal University, Bolu, Turkey

³Department of Pathology, Kocaeli Derince Training and Research Hospital, Kocaeli, Turkey

INTRODUCTION & OBJECTIVES: Pityriasis rosea (PR) is a common, acute, self-limiting, papulosquamous disorder characterized by a single, erythematous herald patch plaque followed by a secondary eruption with lesions on the cleavage lines of the trunk. Atypical forms such as inversus, localized and unilateral forms have been described and these account for up to 20% of all cases. In literature, only two case reports were found when screening with dermatomal or segmental PR keywords. Our case is presented here for its rarity form in clinical practice.

MATERIALS & METHODS: This is a case report.

CASE: A 33-year-old female presented to our clinic with a sudden onset of several itchy erythematous and scaly plaques on her back that had been present for two weeks (Photograph 1a-b). The patient first noticed a big plaque, which was followed by new smaller scaly plaques of various sizes. There was no additional complaints. Initially, antiviral treatment with a preliminary diagnosis of herpes zoster was proposed. However the patient stated that she did not use the recommended treatment. Dermatological examination revealed multiple discrete, annular, erythematous plaques with peripheral collarette of scales, the biggest one being a well-defined salmon-colored plaque -herald patch- not crossing the midline, from the left scapular area to the left underarm. The lesions were scattered predominantly at the proper localization of the T2-T3 dermatomal distribution area. A few lesions were also seen throughout the adjacent dermatomes. Systemic examination revealed no abnormalities. The patient's all routine biochemical examinations were in normal range and KOH mount did not reveal any fungal elements. A punch biopsy material obtained from the lesion.

RESULTS: Histopathological examination showed focal parakeratosis, mild epidermal hyperplasia, spongiosis and perivascular lymphocyte infiltrate. According to clinical and histopathological findings, unilateral PR was diagnosed. Lesions have been treated with topical methylprednisolone and desloratadine tablet for 2 weeks and complete resolution was observed.

CONCLUSION: Atypical PR cases are rare and they are confused with many different entities in terms of location and morphology. Neurological and immunologic responses are involved in the pathogenesis of papulosquamous diseases and neuropeptides such as nerve growth factor may play a role in the development of PR that is distributed throughout the neural segment. It has been reported that herpes

3rd INDERCOS

National Dermatology & Cosmetology Congress with International Participants

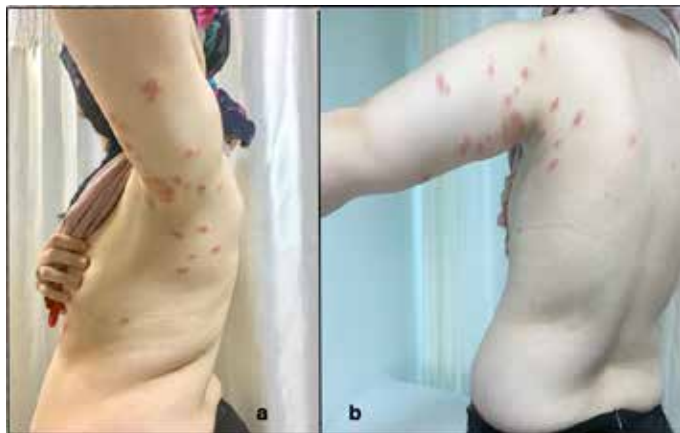14-17 MARCH, 2018
HILTON ISTANBUL BOSPHORUS HOTEL
ISTANBUL, TURKEY



zoster disease with characteristic dermatomal spread is rarely observed in other adjacent dermatomes in immunocompetent individuals. We present a unilateral PR with dermatomal spread on an immunocompetent person which was initially confused with herpes zoster infection. It should be kept in mind that PR may also manifest itself with atypical lesions. A careful anamnesis and dermatological examination should be performed by an expert in order to avoid misdiagnosis and establish the best treatment options.

Keywords: Pityriasis rosea, atypical, dermatomal, unilateral, zosteriform, segmental

Photograph 1 a-b



Well-defined salmon-colored herald patch and several erythematous and scaly plaques at the proper localization of the T2-T3 dermatomal distribution area of her back.

PP-144

[ANGIOLOGY, HAEMANGIOMAS, VASCULAR MALFORMATIONS, VASCULITIS]

ACUTE INFANTILE HEMORRHAGIC OEDEMA, A CASE REPORT

Büşra Deniz, Mustafa Anıl Yılmaz, Begüm Ünlü, Hediye Rana Gümüşdağ, Ümit Türsen
Department of dermatology, Mersin university medical school, Mersin, Turkey

Acute infantile hemorrhagic oedema (AIHO) is a cutaneous leukocytoclastic vasculitis characterized by purpuric skin rashes, fever and oedema (1,2). This disease starts severely and with a short onset period, it is benign and it heals spontaneously in a few weeks. Some publications say that this disease may be a cutaneous variant of Henoch Schönlein Purpura (HSP) (3) but some publications consider that it is a different entity (4). The aim of this study is to remind you about the clinical signs and symptoms of this rare disease.

Keywords: Acute infantile hemorrhagic edema, purpura, vasculitis

Figure 1

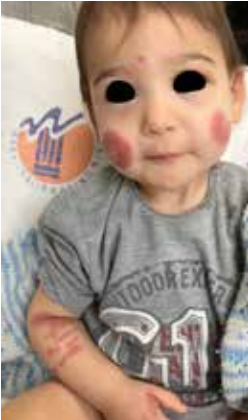

Figure 2

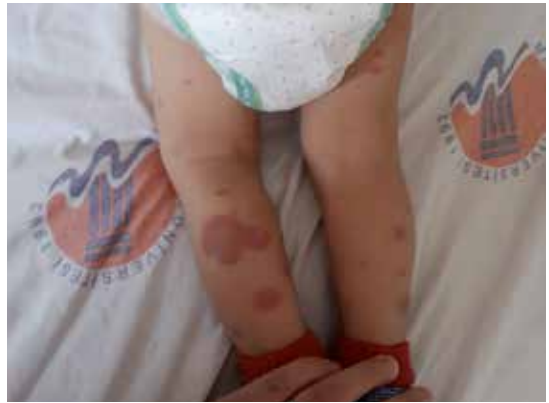
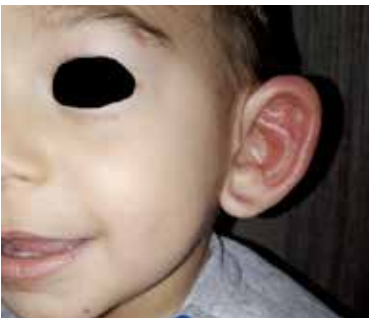
Figure 3



3rd INDERCOS

National Dermatology & Cosmetology Congress with International Participants

14-17 MARCH, 2018
HILTON ISTANBUL BOSPHORUS HOTEL
ISTANBUL, TURKEY



PP-145

[CUTANEOUS ONCOLOGY]

POROKERATOIS LIKE BASAL CELL CARCINOMA

Muhammet Reşat Akkuş¹, Kemal Özyurt¹, Mustafa Atasoy¹,
Yılmaz Ulaş¹, Ragıp Ertaş¹, Serdar Sadet Özcan², Yücel Tekin²

¹Clinic of Dermatology, Sağlık Bilimleri University. Education and Research Hospital, Kayseri, Turkey

²Clinic of Pathology, Sağlık Bilimleri University. Education and Research Hospital, Kayseri, Turkey

Basal Cell Carcinoma (BCC) is the most frequent skin cancer which is derived from non-keratinised cell of basal layer of epidermis., BCC seems frequently in sun-exposed areas of the body; head and neck, as UV is the major etiological factor. Recently, cases of BCC are published with atypical locations and clinical presentations. Porokeratosis is a distinct entity and generally presented raised peripheral borders with central atrophy. In literature lots of presentations show the development of malignancy from the porokeratosis. Here, we are presenting a case of BCC on back of patient mimicking porokeratosis.

Keywords: Basal Cell Carcinoma, Porokeratosis, atypical clinic variant

PP-146

[INFLAMMATORY SKIN DISEASES]

A CASE REPORT OF A PATIENT, WHO HAD ERITRODERMIC PSORIASIS AFTER CORTICOSTEROID DRUG USE

Büşra Deniz, Hediye Rana Gümüşdağ, Mustafa Anıl Yılmaz, Begüm Ünlü, Ümit Türsen
Department of dermatology, Mersin university medical school, Mersin, Turkey

Psoriasis is a chronic, genetic and immune-mediated disease which is presenting red patches of skin (1). It can be aggravated trauma, sunburn, or chemical irritants. Also systemic drugs can provoked the disease for example β blockers, lithium, antimalarials, and non-steroidal anti-inflammatory agents (2). Corticosteroids in psoriasis treatment should not be preferred too much because withdrawal risks exacerbating of the psoriatic lesions and may cause generalised pustular psoriasis. After stopping a treatment, lesions of psoriasis increases rapidly in rebound psoriasis. In this paper, we presented a male patient who admitted to our outpatient clinic with red patches and silvery scales that covers about 80% of the his body.

Keywords: psöriasis, corticostreoids, flare, eritrodermic psöriasis

Figure 1

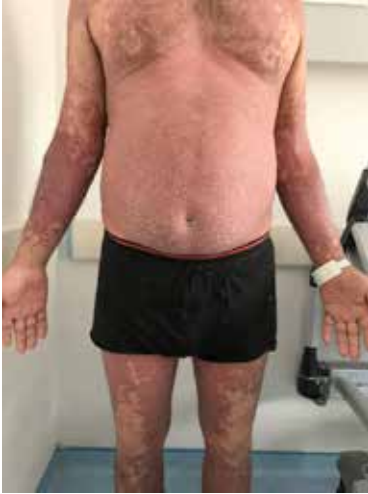

Figure 2

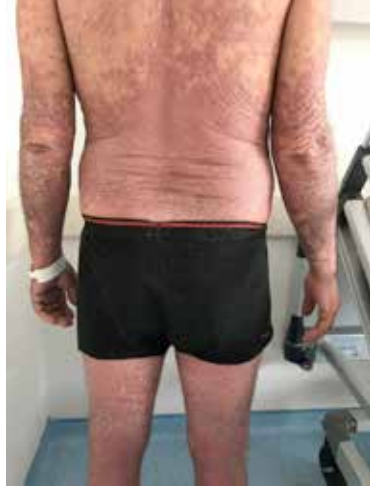
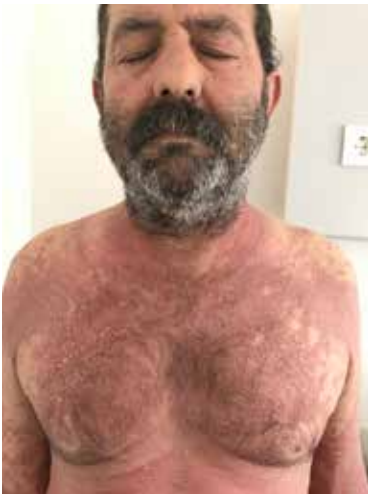
Figure 3



3rd INDERCOS

National Dermatology & Cosmetology Congress with International Participants

14-17 MARCH, 2018
HILTON ISTANBUL BOSPHORUS HOTEL
ISTANBUL, TURKEY



PP-147

[CUTANEOUS ONCOLOGY]

BOWEN'S DISEASE: A CASE REPORT

Fatma Tunçez Akyürek¹, Nihal Sarı¹, Gülcan Saylam Kurtipek¹, Ceyhan Uğurluoğlu²

¹Department of Dermatology Selcuk University, Konya, Turkey

²Department of Pathology Selcuk University, Konya, Turkey

Bowen's disease (BD) is a form of in situ squamous cell carcinoma commonly occurring in the elderly. It often presents mainly slowly growing, well-demarcated, scaly or crusted, pink erythematous to brown patch or plaque lesions with irregular borders usually on sun-exposed sites. Dermoscopy is a noninvasive technique that has enhanced the diagnostic accuracy of skin tumors. The main dermoscopic features of BD are glomerular vessels, scaly surface, small brown globules and grey to brown pigmentation. A 65-year-old male patient was presented with a 5-year history of an erythematous infiltrated plaque lesion on scrotum. The patient has been reported to have sexual contact with a woman in the recent year before the onset of the symptoms. Results of laboratory testing included a positive venereal disease research laboratory (VDRL). Other serological confirmation tests [TPHA (Treponema pallidum hemagglutination assay) and RPR (Rapid plasma reagin)] were negative. The dermoscopic features observed included glomerular vessels and scaly surface. An ultrasound of the inguinal region was performed and bilateral inguinal lymphadenopathies were detected. The histological findings of the lesional punch biopsy and total excisional material were compatible with Bowen's disease (intraepithelial neoplasia). The risk of BD progressing to squamous cell carcinoma has been estimated to be %3-5, therefore early diagnosis and treatment are very important. Glomerular vessels and scaly surface were the most frequent dermoscopic finding of pigmented and non-pigmented BD. Dermoscopy may be considered as a helpful tool for increasing the diagnostic accuracy of BD based on these clues. In this case, although it has suspicious symptoms in terms of syphilis in the anamnesis and laboratory investigation, BD was diagnosed based on dermoscopic examination.

Keywords: Bowen's disease, dermoscopy, syphilis



3rd INDERCOS

National Dermatology & Cosmetology Congress with International Participants

14-17 MARCH, 2018
HILTON ISTANBUL BOSPHORUS HOTEL
ISTANBUL, TURKEY

PP-148

[MISCELLANEOUS]

A CASE SERIES WITH “INVERSE” SEBORRHEIC KERATOSIS

Hülya Cenk¹, Gülbahar Saraç²

¹Department of Dermatology, Sorgun State Hospital, Yozgat, Turkey

²Department of Dermatology, Inonu University, Malatya, Turkey

Seborrheic keratosis (SK) is one of the most common benign epidermal tumors. Both sexes are affected equally and usually appear in the fifth decade of life and generally, new lesions continue to emerge later on. It's seen on any part of the body, mostly on the face and the upper trunk. It is usually asymptomatic but may be itchy. SKs usually present as multiple, pigmented, sharply marginated, velvety lesions. SKs typically evolve from a slightly hyperpigmented macule and may progress to become papular or verrucous depending on their stage of development. There are six subtypes identified: dermatosis papulosa nigra, stucco keratosis, inverted follicular keratosis, large cell acanthoma, lichenoid keratosis, and flat seborrheic keratosis. But as far as we know there aren't any classifications based on the location, maybe because of its wide involvement.

Recently four patients with seborrheic keratosis on flexural surfaces (axillae, submammary folds and groins) admitted to our outpatient polyclinic consecutively in two months. Three of the patients were women and the other patient was a man. All of the patients were in their sixties and they hadn't any SKs on the other parts of their body except the face and neck. We didn't encounter any data about intertriginous, inverse or flexural type of SK. Therefore, we have thought that we could name these type of patients as having inverse SKs, a new type classified based on the location. We found valuable to share this case series because it may represent a new classification of SKs.

Keywords: Inverse, intertriginous, seborrheic keratosis

3rd INDERCOS

National Dermatology & Cosmetology Congress with International Participants

14-17 MARCH, 2018
HILTON ISTANBUL BOSPHORUS HOTEL
ISTANBUL, TURKEY



PP-149

[ACNE AND RELATED DISORDERS, HIDRADENITIS SUPPURATIVA]

A NEW THERAPEUTIC APPROACH TO GRANULOMATOUS ROSACEA: ORAL IVERMECTIN.

Mehmet Salih Gurel¹, Muge Gore Karaali², Vefa Aslı Erdemir¹

¹Department of Dermatology, Medeniyet University, Istanbul, Turkey

²Department of Dermatology, Istanbul Training and Research Hospital, Istanbul, Turkey

INTRODUCTION: Granulomatous rosacea (GR) is a rare clinicopathological variant of rosacea presented with lesions localized largely to the central face. GR may be considered recalcitrant to therapy and a number of agents have anecdotally been used such as oral doxycycline, metronidazole, isotretinoin, dapsone and corticosteroids. Here in, we report four cases who were treated with oral ivermectin successfully.

CASES: Four patients (2 female, 2 male) presented to the dermatology outpatient clinic with erythematous, monomorphic, firm papules, pustules, nodules and plaques. All patients had histopathological results with granulomatous rosacea. The patients were resistant to oral corticosteroid, oral isotretinoin and oral metronidazole therapy. All patients were treated with oral ivermectin for 1 to 2 months long. The female patients used oral ivermectin with oral isotretinoin and topical ivermectin were used as for the maintenance therapy. One of the male patient used oral and topical ivermectin together. The other one used oral metronidazole, ivermectin and topical ivermectin together. In all four patients the lesions improved significantly and no relapses were noted for follow-up period.

DISCUSSION: Ivermectin is an anti-parasitic drug. Topical ivermectin is considered as an effective treatment option for rosacea. But the mechanism in rosacea is unclear; antimicrobial, antiparasitic, antibacterial and anti-inflammatory activities may play a role. Literature concerning oral ivermectin is more limited. By reporting these cases, we aimed to emphasize the place of oral ivermectin in the therapeutic approach to recalcitrant forms of rosacea, such as granulomatous rosacea.

Keywords: rosacea, oral ivermectin, granulomatous rosacea

PP-150

withdrawn



3rd INDERCOS

National Dermatology & Cosmetology Congress with International Participants

14-17 MARCH, 2018
HILTON ISTANBUL BOSPHORUS HOTEL
ISTANBUL, TURKEY

PP-151

[DERMOSCOPY]

HEMORRHAGIC, BULLOUS LICHEN SCLEROSUS WITH DERMOSCPIC FEATURES

Vefa Aslı Erdemir¹, Mehmet Salih Gürel¹, Melek Aslan Kayıran¹, Filiz Cebeci Kahraman¹, Bengü Çobanoğlu²

¹Department of Dermatology, Medeniyet University

²Department of Pathology, Medeniyet University

Lichen sclerosus (LS) is a chronic inflammatory dermatosis involving the skin and mucous membranes. Approximately 85% of the cases are anogenital and 15-20% are extragenital. The clinical findings of the disease is atrophic plaques in porcelain whitish color accompanied by dryness and pruritus. Hemorrhagic and bullous form is rarely reported. In this case report, we present of a patient with hemorrhagic and bullous LS lesions with dermoscopic features. A 70-year-old female patient presented with mild itchy lesions on the right and left shoulder and on the right side of the back. The patient had a history of diabetes mellitus, hypertension and hyperlipidemia. Dermatologic examination revealed white colored, erythematous plaques on the right and left shoulders and a hemorrhagic irregularly defined plaque with yellowish plugs on the right scapula. On dermoscopic examination, bright white-yellowish patches, yellowish-follicular plugs were observed on porcelain whitening plaques, and yellowish follicular plugs on on red background constitute with strawberry pattern and also white scaling were noted on hemorrhagic lesion. Histopathological examination of the biopsy from both lesions revealed hyperkeratosis, focal parakeratosis, epidermal atrophy, mild nonacantholytic bulla, dermal edema lymphocytes and histiocytes. Direct immunofluorescence was negative. The patient was diagnosed with hemorrhagic and bullous lichen sclerosus. Bullous LS is a rare disorder that can be generalized and localized. The bullous form of LS is thought to be due to edema in the dermis and excessive vacuolar degeneration in the basal membrane. The haemorrhagic view is thought to be the end result of the disintegration of capillaries with loss of dermal support. In a previous study, dermoscopy was used at LS and Morfea distinction and LS dermoscopic criteria were defined. Hemorrhagic points have been detected especially in patients with inflammatory sclerotic stage lesions. In our patient, strawberry pattern and scaling are observed on hemorrhagic lesion as a new dermoscopic finding.

Keywords: Lichen sclerosus, Hemorrhagic, Dermoscopy



PP-152

[ADVERSE DRUG REACTIONS, TEN]

SORAFENIB INDUCED RASH: A CASE REPORT

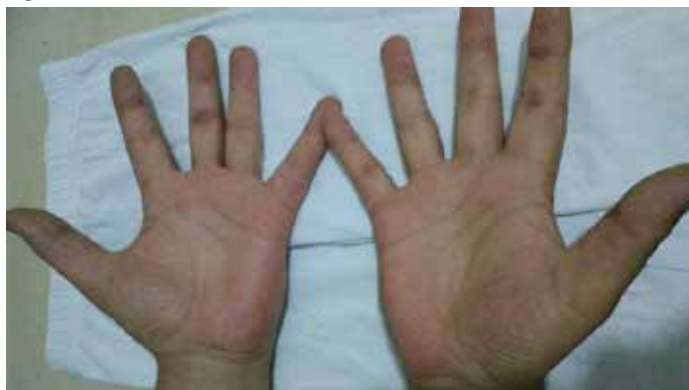Mustafa Anıl Yılmaz, Melodi Çekiç, Begüm Ünlü, Ümit Türsen

Department of Dermatology, Mersin University Medical School, Mersin, Turkey

Sorafenib is a multikinase inhibitor used for treatment of hepatocellular cancer. Sorafenib may cause adverse reactions such as gastrointestinal system, dermatological, hypertension and hypoalbuminemia. Sorafenib inhibits the signals of growth factors and it is down-regulating RAF/mitogen-activated protein/extracellular signal-regulated kinase (ERK) kinase (MEK)/ERK cascade. The sorafenib- associated hand- foot syndrome is painful erythematous plaques in the palmoplantar areas which include the dorsum of the hands and feet and periungual areas. Vesicles and peeling may occur in severe cases. The clinical symptoms are pain, ulceration, desquamation, swelling and blistering. Sorafenib may also lead to other cutaneous adverse effects such as seborrheic dermatitis like rash, alopecia, splinter hemorrhages and inflammation of actinic keratoses. We reported a 52 year old male patient suffering from hepatocellular carcinoma and hepatitis B infection was treated with sorafenib. After 2 weeks, the patient presented with cutaneous skin lesions on the soles and palms. On physical examination, erythematous and bullous lesions were noted. Based on clinical findings and history, a diagnosis of hand-foot syndrome secondary to sorafenib therapy was made.

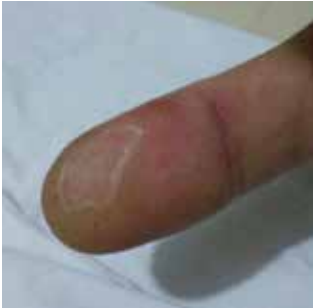Keywords: Sorafenib, rash, adverse effect

Figure 1



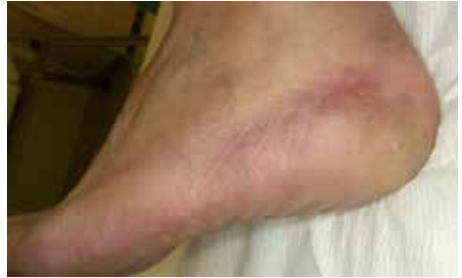Erythematous plaques in the palmoplantar areas

Figure 2



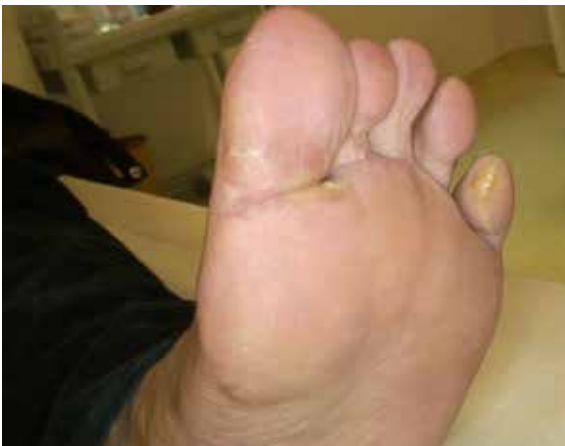Erythematous plaques in the palmoplantar areas

Figure 3



Erythematous plaques in the palmoplantar areas

Figure 4



Erythematous plaques in the palmoplantar areas



PP-153

[INFLAMMATORY SKIN DISEASES]

BENIGN LICHENOID KERATOSIS ON THE INTRAMAMMARY FOLD: A CASE REPORT

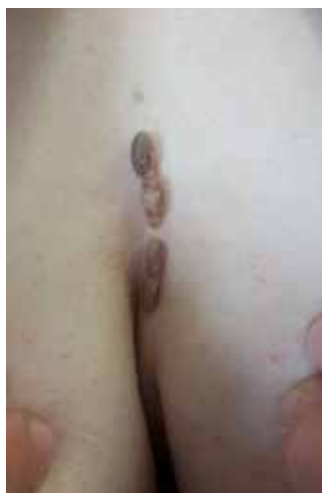Begüm Ünlü, Melodi Çekiç, Mustafa Anıl Yılmaz, Ümit Türsen

Department of Dermatology, Mersin University Medical School, Mersin, Turkey

Benign lichenoid keratosis, also known as lichen planus-like keratosis, is a cutaneous entity that presents with asymptomatic, pink to violaceous to hyperpigmented papule or plaque. Histology of this entity reveals epidermal acanthosis, parakeratosis and a band-like lichenoid lymphocyte infiltrate. 21 years old female patient attended to our dermatology clinic with asymptomatic, pink to violaceous to hyperpigmented papular lesions on intramammary fold, first noticed when she was baby. In histopathologic examination, epidermal necrotic keratinocytes, vacuolar alterations of the basal layer and lichenoid infiltrate of lymphocytes in dermis was observed. We aimed to emphasize that we should keep in mind benign lichenoid keratosis in differential diagnosis of papular lesions which are similar to dermal nevus, skin tag, tumour or lichenoid lesions.

Keywords: Benign lichenoid keratosis, nevus, skin tag

Figure 1



Pink to violaceous to hyperpigmented papular lesions on intramammary fold

PP-154

[ORAL MUCOSA AND OTHER SKIN-ADJACENT MUCOUS MEMBRANES] PYOGENIC GRANULOMA WITH LOW GRADE DYSPLASIA: A CASE REPORT

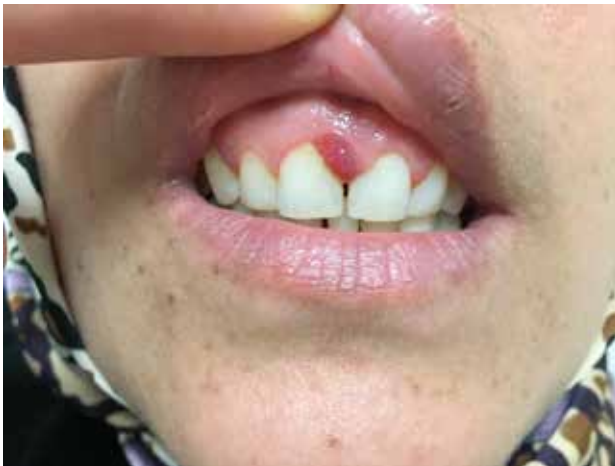Melodi Çekiç, Begüm Ünlü, Mustafa Anıl Yılmaz

Department of Dermatology, Mersin University Medical School, Mersin, Turkey

The pyogenic granuloma is a benign inflammatory lesion. It is considered to be a tissue reaction to local traumas. Pyogenic granuloma is the most common gingival tumoral lesion. It may also be seen in other mucosal areas such as; lips, tongue and buccal mucosa. Some drugs such as cyclosporine may have a role in forming pyogenic granuloma. Differential diagnosis is very important in oral mucosal lesions and biopsy findings have an important role, too. Once pyogenic granuloma has been diagnosed; hemangioma(4), Kaposi's sarcoma, metastatic cancer, (3) bacillary angiomatosis, angiosarcoma(4) and Non-Hodgkin's lymphoma should be considered as differential diagnoses. We reported a 32-year-old woman presented with an exophytic red lesion located in the maxillary region of gingiva which had recurred after having been excised. It was considered as pyogenic granuloma. An incisional biopsy revealed low grade squamous dysplasia and the lesion was surgically excised. This case report shows the importance of performing biopsy in lesions which diagnosed pyogenic granuloma. Possibility of malignancy should be kept in mind.

Keywords: pyogenic granuloma, biopsy, dysplasia

pyogenic granuloma



pyogenic granuloma on gingiva

A large, stylized blue leaf graphic with a central vein and several smaller leaflets, positioned in the upper half of the page.

Authors Index for Abstracts





3rd INDERCOS

National Dermatology & Cosmetology Congress with International Participants

14-17 MARCH, 2018
HILTON ISTANBUL BOSPHORUS HOTEL
ISTANBUL, TURKEY

Abdel Kareem Ibrahim Mohammed

OP-19

OP-38

Acer Ersoy

OP-31

PP-056

PP-087

PP-106

PP-122

PP-129

Adıyaman Nuran Süngü

PP-110

Afşar Fatma Şule

PP-018

Ağaoğlu Esra

PP-106

Ağırgöl Senay

PP-030

Ağırgöl Şenay

OP-50

PP-023

PP-064

Ak Ayşegül

OP-50

Akaryıldız Mustafa

PP-024

Akbaba Gulhan

PP-052

Akbas Ayse

OP-14

Akbaş Ayşe

PP-089

PP-110

PP-118

PP-138

Akdeniz Necmettin

OP-60

Akkalp Aslı Kahraman

PP-084

PP-099

Akkuş Muhammet Reşat

PP-121

PP-141

PP-145

Akkuş Reşat

PP-102

Aksoy Berna

OP-24

OP-52

OP-54

PP-069

PP-133

Aksoy Hande Nur

PP-088

Aksoy Hasan Mete

OP-24

PP-069

PP-133

3rd INDERCOS

National Dermatology & Cosmetology Congress
with International Participants

14-17 MARCH, 2018

HILTON ISTANBUL BOSPHORUS HOTEL
ISTANBUL, TURKEY



Aksoy Mustafa

PP-004

PP-096

PP-116

PP-135

PP-142

Aksoy Nazan

PP-030

Aksu Ayşe Esra Koku

OP-22

Aktar Rojda

PP-004

Aktaş Akın

PP-025

PP-089

PP-110

PP-118

PP-138

Aktaş Hamza

OP-02

Al Mulla Emad

OP-57

Alatas Emine Tugba

PP-093

Alhussan Yazeed

OP-46

Alomair Nora

OP-46

Alp Erdal Semahat

OP-02

Alpsoy Erkan

PP-017

PP-022

PP-136

Alpua Murat

OP-34

Alsallouth Nawaf

OP-46

Altay Mehmet Akif

PP-142

Altınyazar Hilmi Cevdet

OP-40

Altun Deniz Büşra

PP-071

Altunay İlknur

PP-045

PP-115

Altundal Kamile

PP-064

Alyahia Mazen

OP-46

Alzahrani Muhannad

OP-46

Anadolu Rana

PP-096



3rd INDERCOS

National Dermatology & Cosmetology Congress with International Participants

14-17 MARCH, 2018
HILTON ISTANBUL BOSPHORUS HOTEL
ISTANBUL, TURKEY

Arıcı Akgül

PP-107

Arıcı Akgül

PP-104

Arık Deniz

PP-122

Arshah Tarek Mohamed

PP-044

Arsan Abdurrahman

OP-41

Aslan Abdulmuttalip

OP-43

Aslan Kayıran Melek

OP-56

OP-59

PP-131

PP-151

Astarcı Hesna Müzeyyen

PP-140

Ataoglu Safinaz

PP-105

Ataseven Arzu

PP-011

PP-035

PP-059

PP-108

PP-109

PP-113

PP-125

Atasoy Mustafa

PP-034

PP-102

PP-121

PP-141

PP-145

Atasoy Pınar

OP-32

Atış Güldehan

OP-33

Avcı Atıl

PP-102

Avunduk Mustafa Cihat

PP-113

Ay Mustafa Ertan

OP-04

Aydemir Merve

PP-075

PP-088

PP-092

Aydın Büşra

PP-036

PP-082

PP-130

Aydın İlgin

PP-127

Bahcivan Atike

PP-037

3rd INDERCOS

National Dermatology & Cosmetology Congress
with International Participants

14-17 MARCH, 2018

HILTON ISTANBUL BOSPHORUS HOTEL
ISTANBUL, TURKEY



Bakirci Ureyen Sibel

OP-06

Balta Ilknur

OP-37

Barut Figen

PP-132

Bassorgun Cumhuri Ibrahim

PP-136

Bayrak Seval

PP-058

Bayraktar Mehmet

PP-116

Baysak Sevim

PP-024

PP-083

Benhiba Hind

PP-010

Biçer Yusuf Özgür

PP-076

Bilen Handan

OP-36

PP-001

PP-066

Bilgili Serap Gunes

PP-005

Bilgin Muzaffer

OP-31

Birol Kocaalp Ahu

OP-32

Boran Çetin

PP-042

Böyük Emine

OP-21

Bozca Burçin Cansu

PP-022

PP-136

Bukhari Iqbal

OP-46

Bülbül Başkan Emel

PP-119

Bulur Işıl

OP-21

OP-41

Büyükdeğirmenci Cansu

PP-022

Büyüktortop Gökçınar Nesrin

OP-26

Caf Nazlı

PP-030

Çakır Cumhuri

PP-021

Çalıkoğlu Emel

OP-24



3rd INDERCOS

National Dermatology & Cosmetology Congress with International Participants

14-17 MARCH, 2018
HILTON ISTANBUL BOSPHORUS HOTEL
ISTANBUL, TURKEY

Çalım Begüm

PP-114

Can Kuru Burçe

PP-074

PP-091

Canaz Funda

OP-21

PP-087

Çaytemel Ceyda

PP-023

PP-064

Cebeci Filiz

OP-59

PP-131

Cebeci Kahraman Filiz

PP-151

Çekiç Melodi

PP-051

PP-152

PP-153

PP-154

Çelik Ebru

PP-013

PP-015

PP-016

Çelik Zeliha Esin

PP-060

Cenk Hülya

PP-008

PP-050

PP-053

PP-078

PP-101

PP-148

Cetin Elif

PP-067

PP-139

Çetin Çiğdem Berna

PP-082

Çetinarslan Tubanur

PP-124

Chatziioannou Sofia

OP-27

Chen Wenchieh

OP-61

Cinar Nese

PP-052

Cinar Salih Levent

OP-12

Ciriş Ibrahim Metin

PP-047

Çobanoğlu Bengü

PP-151

Cornaggia Medici Pier Luigi L.m.

OP-16

3rd INDERCOS

National Dermatology & Cosmetology Congress
with International Participants

14-17 MARCH, 2018

HILTON ISTANBUL BOSPHORUS HOTEL
ISTANBUL, TURKEY



Culha Gulnaz

PP-013

Daie Ghazvini Roshanak

PP-079

Davarcı Erkan

PP-127

Demir Mahmut

PP-142

Demir Pektas Suzan

OP-13

OP-39

PP-039

PP-052

PP-062

PP-093

Demirbaş Abdullah

PP-029

Demirci Elif

PP-066

Demirkan Serkan

OP-34

Deniz Arık

PP-007

Deniz Büşra

PP-051

Deniz Büşra

PP-144

PP-146

Derviş Emine

OP-56

Dogan Gursoy

PP-093

Doğan Bilal

PP-024

PP-083

Doğan Altınpulluk Meryem

PP-040

PP-094

Doğru Gurbet

OP-04

Duman Deniz Demircioglu

PP-052

Dursun Recep

PP-011

PP-035

PP-059

PP-108

PP-109

PP-113

PP-125

Dusak Abdurrahim

PP-142

Düzcü Selma Erdoğan

PP-080

PP-098

Edebal Zehra

PP-109



3rd INDERCOS

National Dermatology & Cosmetology Congress with International Participants

14-17 MARCH, 2018
HILTON ISTANBUL BOSPHORUS HOTEL
ISTANBUL, TURKEY

Ehtesham Masoud

OP-53

Ekinci Alper

PP-073

PP-111

Ekşioğlu Hatice Meral

OP-37

El Darbi Reem

OP-09

El Esawy Fatma Mohamed

OP-45

El Lawindi Mona Ibrahim

OP-47

El Nabarawy Eman A.

OP-47

El Zawahry Bakr Mohamed

PP-054

Elahi Afnan

OP-46

Elghobashy Mohammed Ahmed

OP-19

Elgörmüş Ceren Buğlem

PP-031

PP-132

Elmasry Maha Fathy

OP-09

OP-47

PP-046

PP-054

Emeksiz Mehmet Ali Can

OP-32

Emre Selma

PP-025

Engin Burhan

OP-10

Erdal Mehmet Emin

OP-04

Erdem Yasemin

PP-038

Erdemir Vefa Aslı

OP-59

PP-149

PP-151

Erdoğan Serpil

PP-025

Erel Ozcan

PP-039

PP-052

Ergin Merve

PP-025

Erman Hayriye

OP-60

3rd INDERCOS

National Dermatology & Cosmetology Congress
with International Participants

14-17 MARCH, 2018

HILTON ISTANBUL BOSPHORUS HOTEL
ISTANBUL, TURKEY



Ersay Acer

PP-007

Ertas Ragıp

PP-065

PP-086

Ertaş Ragıp

OP-15

PP-034

PP-102

PP-121

PP-141

PP-145

Erturan İjlal

PP-012

PP-047

Erturk Zeynep

OP-06

Erucar Ahmet Tuğrul

PP-143

Esbah Onur

PP-041

Esmer Oktay

PP-043

Falay Tuğba

PP-115

Falay Gur Tuğba

PP-024

Falay Gür Tuğba

PP-083

Fenjanlı Ali Reza

OP-10

Fındık Sıddıka

PP-011

PP-035

PP-108

Gamsızkan Mehmet

PP-037

PP-049

PP-065

PP-086

PP-105

Gautam Rakesh

OP-29

PP-002

Gega Migena

PP-026

Gencer Başol Hatice

OP-42

Georgakopoulos Alexandros

OP-27

Geyik Aslıhan

PP-098

PP-140

Giouleka Paschalina

OP-27



3rd INDERCOS

National Dermatology & Cosmetology Congress with International Participants

14-17 MARCH, 2018
HILTON ISTANBUL BOSPHORUS HOTEL
ISTANBUL, TURKEY

Gocer Onder Sevda

PP-043

Göktay Fatih

OP-33

Gore Karaali Muge

PP-149

Güder Semih

OP-23

Guler Simsek Gulcin

PP-043

Gümüşdağ Hediye Rana

PP-144

PP-146

Gündüz Özgür

OP-26

PP-006

PP-070

Gunes Bilgili Serap

PP-043

Güneş Bilgili Serap

PP-004

Güngör Emre Sinan

OP-49

Güngör Şule

OP-49

Gurel Mehmet Salih

PP-149

Gürel Mehmet Salih

OP-22

OP-59

OP-60

PP-131

PP-151

Gursoy Fatıma

PP-020

Gürsoy Fatıma

PP-072

PP-112

Güvenç Ulaş

PP-116

PP-135

Güzelçiçek Ahmet

PP-142

Hacıhasanoğlu Ezgi

OP-22

Halvae Samaneh

PP-079

Hamed Ahmed Mohamed

OP-07

Hancer Hilal Semra

PP-052

PP-093

Haşal Eda

PP-119

3rd INDERCOS

National Dermatology & Cosmetology Congress
with International Participants

14-17 MARCH, 2018

HILTON ISTANBUL BOSPHORUS HOTEL
ISTANBUL, TURKEY



Hasan Manal

OP-46

Hawro Tomasz

PP-034

Hilal Kaya Erdogan

PP-007

Hüdaverdi Meltem

PP-023

PP-064

Hye Mohammad Abdul

OP-18

OP-58

Ibrahim Ibrahim Mearag

OP-19

Ipin Tuğba

PP-048

Işık Merve

OP-52

OP-54

Isik Mermutlu Selda

OP-01

Izci Ay Özlem

OP-04

Kalkan Gökür

PP-025

Kandaz Mustafa

OP-05

Kapıcıoğlu Yelda

PP-008

PP-050

PP-053

PP-078

Kara Ahmet

PP-052

Kara Cüneyt

PP-024

PP-083

Karaağaç Onur

PP-109

Karadağ Ayşe Serap

OP-61

PP-043

Karadağ Remzi

PP-043

Karadağ Ayşe Serap

OP-59

OP-60

Karadayı Nimet

OP-54

Karagun Ebru

PP-049

PP-086

PP-105



3rd INDERCOS

National Dermatology & Cosmetology Congress with International Participants

14-17 MARCH, 2018
HILTON ISTANBUL BOSPHORUS HOTEL
ISTANBUL, TURKEY

Karakuzu Ali

PP-018
PP-084
PP-099
PP-127

Karaosmanoğlu Nermin

OP-17

Karapınar Tekden

PP-057
PP-058
PP-076
PP-080
PP-090
PP-098
PP-137
PP-140

Karatepe Hasan Turan

OP-60

Karlı Şahin

OP-02

Kaur Ahmet

OP-52

Kaya Tamer İrfan

PP-071

Kaya Erdoğan Hilal

OP-31
PP-056
PP-087
PP-106
PP-122
PP-129

Kaya İslamoğlu Zeynep Gizem

OP-40

Kaya Özden Hatice

PP-143

Kaya Terzi Neslihan

PP-024
PP-083

Kaygısız Bilgin

OP-21

Kelekçi Kıymet Handan

PP-018
PP-084
PP-099
PP-127

Khanna Neena

OP-11

Kibar Öztürk Melike

PP-020
PP-072
PP-075
PP-088
PP-092
PP-114
PP-126

Kibar Öztürk Melike

PP-077

3rd INDERCOS

National Dermatology & Cosmetology Congress
with International Participants

14-17 MARCH, 2018

HILTON ISTANBUL BOSPHORUS HOTEL
ISTANBUL, TURKEY



Kibar Öztürk Melike

OP-30
PP-014
PP-021
PP-027
PP-040
PP-094
PP-097
PP-112

Kılıçarslan Aydan

PP-118

Kılınç Fadime

OP-14
PP-089
PP-110
PP-118
PP-138

Kısacık Didem

PP-008
PP-050

Kıvanç Altunay İlknur

PP-038

Kivrak İbrahim

PP-062

Kızıлтаç Kübra

PP-095

Koca Rafet

PP-031
PP-132

Koçak Gülşah

PP-006
PP-070

Koçak Mukadder

OP-32

Kocatürk Emek

PP-048
PP-095

Kocatürk Mehtap

PP-135
PP-142

Kocatürk Özcan

PP-135
PP-142

Kocatürk Göncü Özgür Emek

PP-061

Koçer Murat

PP-047

Kolay Aypınar

PP-075
PP-088
PP-092

Kolilekas Lykourgos

OP-27

Konur Gülden

PP-019
PP-042
PP-057
PP-080



3rd INDERCOS

National Dermatology & Cosmetology Congress with International Participants

14-17 MARCH, 2018
HILTON ISTANBUL BOSPHORUS HOTEL
ISTANBUL, TURKEY

Korbila Ioanna

OP-27

Korkmaz Selma

OP-20

PP-012

PP-047

Kösem Mustafa

PP-130

Koska Mahmut Can

PP-091

Köylü Nihal

PP-068

Kunter Seza

PP-048

Kutlu Ömer

OP-37

Kutlubay Zekayi

OP-10

Kwasniewski Marcin

PP-085

Leblebici Cem

OP-22

Leylek Ozgur

OP-08

Manali Effrosyni D

OP-27

Mantar Irem

PP-008

PP-050

PP-053

PP-078

Mashaly Heba

PP-046

Maurer Marcus

PP-034

Mehtap Ozgur

PP-049

Melikoğlu Mehmet

OP-23

OP-42

OP-43

PP-001

PP-066

Metekoğlu Şafak

OP-23

Meydan Mehmet Yunus

PP-030

Milosavljevic Mirjana

PP-117

Milosavljevic Sanja

PP-117

Mohamed Marwa

OP-44

3rd INDERCOS

National Dermatology & Cosmetology Congress
with International Participants

14-17 MARCH, 2018

HILTON ISTANBUL BOSPHORUS HOTEL
ISTANBUL, TURKEY



Muja Diana

PP-026

Nagui Noha Abdel Rehim

OP-09

Neselioglu Salim

PP-039

PP-052

Oba Muazzez Çiğdem

OP-10

Oğretmen Zerrin

PP-073

PP-111

Oğrum Atiye

PP-067

PP-107

PP-139

Oğrum Atiye

PP-033

PP-100

PP-104

Oğuz Topal İlteriş

OP-23

Oguztuzun Serpil

PP-043

Oltulu Pembe

PP-125

Onec Birgul

PP-049

Örnek Nurgül

OP-26

Örnek Sinem Ayşe

PP-048

PP-061

PP-095

Özarslan Bengisu

OP-01

Özaydın Yavuz Gökür

OP-48

PP-004

Ozbilgin Ahmet

PP-013

Ozcan Yunus

PP-028

PP-037

PP-041

PP-049

PP-065

PP-086

PP-105

Özcan Serdal Sadet

PP-145

Özçelik Gül

PP-038

Özçentik Aslı

PP-017



3rd INDERCOS

National Dermatology & Cosmetology Congress with International Participants

14-17 MARCH, 2018
HILTON ISTANBUL BOSPHORUS HOTEL
ISTANBUL, TURKEY

Özdemir Ömer

PP-061
PP-095

Özdemir Şevki

OP-42
PP-001
PP-066

Özekinci Selver

PP-061

Özer İlkay

PP-011
PP-035
PP-059
PP-108
PP-109
PP-113
PP-125

Özer Mehmet

PP-138

Özeren Mehmet

PP-123

Özgür Tumay

PP-015

Özkan Elif Emine

OP-20
PP-012
PP-047

Özkanlı Sıdika Şeyma

PP-091

Özkara Tuçe

PP-138

Özkur Ezgi

PP-045

Özkur Ezgi

OP-24
PP-038
PP-115

Özlu Emin

OP-61
PP-028
PP-037
PP-041
PP-043
PP-049
PP-065
PP-086
PP-105

Özlü Emin

OP-15
PP-102

Öztas Kara Rabia

OP-06

Öztekin Aynure

PP-039

Öztekin Coskun

PP-039

Özyurt Kemal

PP-065

3rd INDERCOS

National Dermatology & Cosmetology Congress with International Participants

14-17 MARCH, 2018
HILTON ISTANBUL BOSPHORUS HOTEL
ISTANBUL, TURKEY



Özyurt Kemal

PP-034
PP-102
PP-121
PP-141
PP-145

Pala Erdal

PP-001
PP-066

Papadaki Georgia

OP-27

Papadavid Evaggelia

OP-27

Papaioannou Andriana I

OP-27

Papiris Spyros

OP-27

Paravina Mirjana

PP-117

Parlak Ali Haydar

PP-019
PP-042
PP-057
PP-090

Parlak Hatice

PP-087

Pektas Gokhan

PP-052

Pianou Nikoletta K

OP-27

Pinar Atasoy

PP-006

Polat Mualla

PP-058
PP-076
PP-080
PP-098
PP-137
PP-140
PP-143

Prandecka Dorota

PP-085

Ragab Amira

PP-054

Rashed Laila Ahmed

OP-09

Rastgar Ladan

OP-52
OP-54

Rimani Mouna

PP-010

Roussou Aneza

OP-27

Rubins Silvestrs

OP-16



3rd INDERCOS

National Dermatology & Cosmetology Congress with International Participants

14-17 MARCH, 2018
HILTON ISTANBUL BOSPHORUS HOTEL
ISTANBUL, TURKEY

Sadreddini Sina

OP-53

Sağlam İbrahim

PP-142

Şahin Ceyhan

PP-055

Şahin Mustafa Turhan

PP-128

Sanad Eman Moustafa

OP-07

OP-45

OP-51

OP-55

Saraç Gülbahar

PP-008

PP-050

PP-053

PP-078

PP-101

PP-148

Saracoglu Zeynep Nurhan

PP-087

Saracoğlu Zeynep Nurhan

OP-31

Saraçoğlu Zeynep Nurhan

OP-21

OP-41

PP-056

PP-106

PP-122

PP-129

Sarı Güzin

PP-128

Sarı Nihal

PP-060

PP-147

Savaş Müzeyyen Müge

PP-055

Saylam Kurtipek Gülcan

OP-32

PP-029

PP-032

PP-060

PP-063

PP-068

PP-081

PP-103

PP-120

PP-147

Şenel Fatma

PP-121

Şener Serpil

PP-008

PP-050

PP-053

PP-078

3rd INDERCOS

National Dermatology & Cosmetology Congress
with International Participants

14-17 MARCH, 2018

HILTON ISTANBUL BOSPHORUS HOTEL
ISTANBUL, TURKEY



Şener Sertaç

PP-089

PP-110

PP-118

PP-138

Serarslan Gamze

PP-015

PP-016

Serdaroğlu Server

OP-10

Şerefican Betül

OP-25

PP-019

PP-042

PP-057

PP-090

Sertkaya Serap

PP-057

PP-058

PP-090

Sezer Tuna

PP-076

Shaker Olfat

PP-046

Sharma Meghna

OP-03

OP-29

PP-002

PP-003

Sharma Rashmi

PP-002

Shereen Ossama

PP-046

Siguenza Mercedes

PP-085

Şimşek Mehmet

OP-60

Sobczyk Eva

PP-085

Soha Alena

OP-16

Solak Berna

PP-036

PP-082

PP-130

Solano Lopez Guillermo

PP-085

Sözeri Betül

OP-30

PP-097

Sviridova Anna

OP-16

Takci Sahin

PP-033



3rd INDERCOS

National Dermatology & Cosmetology Congress with International Participants

14-17 MARCH, 2018
HILTON ISTANBUL BOSPHORUS HOTEL
ISTANBUL, TURKEY

Takci Zennure

PP-033
PP-107

Takcı Zennure

PP-067
PP-139

Takçı Zennure

PP-100
PP-104

Takır Mumtaz

OP-61

Tanır Sümeyye

PP-059

Tarek Yasmine Ahmed

OP-47

Tas Betul

OP-28

Taşçılar Koray

PP-095

Tatlıparmak Aslı

OP-52
OP-54

Tekin Burak

OP-60

Tekin Leyla

PP-093

Tekin Nilgün

PP-031
PP-132

Tekin Yücel

PP-141
PP-145

Temiz Peyker

PP-128

Temiz Selami Aykut

PP-011
PP-035
PP-059
PP-108
PP-113
PP-125

Tetik Aydogdu Ceyda

PP-093

Tezcan Yavuz

OP-50

Topkarcı Zeynep

OP-43

Tuncel Deniz

PP-038

Tunçöz Ebru

PP-060

3rd INDERCOS

National Dermatology & Cosmetology Congress
with International Participants

14-17 MARCH, 2018

HILTON ISTANBUL BOSPHORUS HOTEL
ISTANBUL, TURKEY



Tunçez Akyürek Fatma

OP-32
PP-029
PP-032
PP-060
PP-063
PP-068
PP-081
PP-103
PP-120
PP-147

Türel Ermertcan Aylin

PP-124

Türkegün Merve

OP-04

Turker Kamuran

OP-28

Turkoglu Zafer

PP-030

Türkoğlu Şule Aydın

OP-25

Türkoğlu Zafer

OP-50
PP-023
PP-064

Tursen Ümit

OP-04

Türsen Ümit

PP-051
PP-071
PP-134
PP-144
PP-146
PP-152
PP-153

Uğurluoğlu Ceyhan

PP-120
PP-147

Ulaş Yılmaz

PP-102
PP-121
PP-141
PP-145

Ulutaş Demirbaş Gözde

PP-029
PP-120

Unal Mehmet

OP-35

Ünal Betül

PP-017
PP-022

Unay Caner

PP-083



3rd INDERCOS

National Dermatology & Cosmetology Congress with International Participants

14-17 MARCH, 2018
HILTON ISTANBUL BOSPHORUS HOTEL
ISTANBUL, TURKEY

Ünlü Begüm

PP-051
PP-134
PP-144
PP-146
PP-152
PP-153
PP-154

Urgancı Tatlı Işıl Ezgi

PP-018

Uzun Fatma

OP-22

Uzun Özge

PP-076

Uzuncakmak Tugba Kevser

OP-61

Vidová Uğurbaş Martina

PP-009

Wantuch Oszczak Joanna

PP-085

Yaldiz Mahizer

OP-06

Yaldız Mehmet

PP-015
PP-016

Yaman Ozan

PP-102

Yavuz Dudu Dilek

PP-047

Yavuz Goknur Ozaydin

PP-005

Yavuz Ibrahim Halil

OP-48
PP-004
PP-005

Yavuz Sibel Orhun

PP-089
PP-138

Yavuzcan Gizem

PP-090

Yazgan Aksoy Duygu

PP-052

Yeşilova Yavuz

PP-116
PP-135
PP-142

Yıldırım Mehmet

PP-012
PP-047

Yıldız Seckin Havva

PP-067
PP-139

3rd INDERCOS

National Dermatology & Cosmetology Congress
with International Participants

14-17 MARCH, 2018

HILTON ISTANBUL BOSPHORUS HOTEL
ISTANBUL, TURKEY



Yıldız Seçkin Havva

PP-033
PP-100
PP-104
PP-107

Yılmaz Nigar

PP-062

Yılmaz Elif

PP-077

Yılmaz Erkan

OP-10

Yılmaz Evrim

OP-21

Yılmaz Mustafa Anıl

PP-071
PP-144
PP-146
PP-152
PP-153
PP-154

Yöntem Özge

PP-061

Yöntem Günver Özge

PP-048

Youssef Randa

PP-046

Yuksel Alpaslan

PP-065

Yüksel Tülin

PP-048
PP-061

Yüksel Çanakçı Nihan

OP-31
PP-056
PP-129

Zeemheri Ebru

PP-112

Zemheri Ebru

PP-014
PP-020
PP-021
PP-027
PP-040
PP-055
PP-072
PP-075
PP-077
PP-088
PP-092
PP-094
PP-097
PP-114
PP-126

Zeynep Nurhan Saracoglu

PP-007



3rd INDERCOS

National Dermatology & Cosmetology Congress with International Participants

14-17 MARCH, 2018
HILTON ISTANBUL BOSPHORUS HOTEL
ISTANBUL, TURKEY

Zindancı İlkin

PP-020
PP-055
PP-072
PP-075
PP-077
PP-092
PP-094
PP-112
PP-114
PP-126

Zindancı İlkin

OP-30
PP-014
PP-021
PP-027
PP-040
PP-074
PP-088
PP-091
PP-097
PP-131



Organization Secretariat



FIGÜR CONGRESS & ORGANIZATION

19 Mayıs Mah. 19 Mayıs Cad. Nova Baran Center No:4 34360 Şişli / İstanbul – Turkey

Phone: 0 212 381 46 00 / Fax: 0 212 258 60 78

E-mail: indercos@figur.net

